National Comprehensive Cancer Network®

NCCN Clinical Practice Guidelines in Oncology (NCCN Guidelines®)

Melanoma: Uveal

Version 1.2026 — February 10, 2026

NCCN recognizes the importance of clinical trials and encourages participation when applicable and available. Trials should be designed to maximize inclusiveness and broad representative enrollment.

Version 1.2026, 02/10/26 © 2026 National Comprehensive Cancer Network® (NCCN®), All rights reserved. NCCN Guidelines® and this illustration may not be reproduced in any form without the express written permission of NCCN.

PLEASE NOTE that use of this NCCN Content is governed by the End-User License Agreement, and you MAY NOT distribute this Content or use it with any artificial intelligence model or tool.
Printed by Galya Basol Kochav on 2/13/2026 11:27:31 AM. Copyright © 2026 National Comprehensive Cancer Network, Inc. All Rights Reserved.

***Susan M. Swetter, MD/Chair** ϖ
Stanford Cancer Institute

***Douglas Johnson, MD, MSCI/Vice-Chair †**
Vanderbilt-Ingram Cancer Center

Mark R. Albertini, MD †
University of Wisconsin
Carbone Cancer Center

Christopher A. Barker, MD §
Memorial Sloan Kettering Cancer Center

Sarah Bateni, MD, MAS ¶
O'Neal Comprehensive
Cancer Center at UAB

Joel Baumgartner, MD ¶
UC San Diego Moores Cancer Center

Shailender Bhatia, MD †
Fred Hutchinson Cancer Center

Christopher Bichakjian, MD ϖ
University of Michigan Rogel Cancer Center

Genevieve Boland, MD, PhD ¶
Mass General Cancer Center

Sunandana Chandra, MD, MS †
Robert H. Lurie Comprehensive Cancer
Center of Northwestern University

David Chen, MD, PhD ϖ
Siteman Cancer Center at Barnes-
Jewish Hospital and Washington
University School of Medicine

Bartosz Chmielowski, MD, PhD ‡ †
UCLA Jonsson
Comprehensive Cancer Center

Jacob Choi, MD, PhD †
Robert H. Lurie Comprehensive Cancer
Center of Northwestern University

Dominick DiMaio, MD ≠
Fred & Pamela Buffett Cancer Center

Roxana Dronca, MD †
Mayo Clinic Comprehensive Cancer Center

Martin D. Fleming, MD ¶
The University of Tennessee
Health Science Center

Anjela Galan, MD ≠
Yale Cancer Center/
Smilow Cancer Hospital

Samantha Guild ¥
AIM at Melanoma

Siwen Hu-Lieskovan, MD, PhD ‡
Huntsman Cancer Institute
at the University of Utah

Giorgos Karakousis, MD ¶
Abramson Cancer Center
at the University of Pennsylvania

Kari Kendra, MD, PhD †
The Ohio State University
Comprehensive Cancer Center -
James Cancer Hospital and
Solove Research Institute

Maija Kiuru, MD, PhD ϖ ≠
UC Davis Comprehensive Cancer Center

Julie R. Lange, MD, ScM ¶
Johns Hopkins Kimmel Cancer Center

Ryan Lanning, MD, PhD §
University of Colorado Cancer Center

Theodore Logan, MD †
Indiana University Melvin and Bren Simon
Comprehensive Cancer Center

Miguel Materin, MD ⌾
Duke Cancer Institute

Kelly Nelson, MD ϖ
The University of Texas
MD Anderson Cancer Center

Daniel Olson, MD †
The UChicago Medicine
Comprehensive Cancer Center

Anthony J. Olszanski, MD, RPh †
Fox Chase Cancer Center

Patrick A. Ott, MD, PhD † ‡ Þ
Dana-Farber/Brigham and Women's Cancer Center

Igor Puzanov, MD, MSCI ‡
Roswell Park Comprehensive Cancer Center

Luke Rothermel, MD, MPH ¶
Case Comprehensive Cancer Center/
University Hospitals Seidman Cancer
Center and Cleveland Clinic Taussig
Cancer Institute

April K. Salama, MD †
Duke Cancer Institute

Rohit Sharma, MD ¶
UT Southwestern Simmons
Comprehensive Cancer Center

***Arun Singh, MD** ⌾
Case Comprehensive Cancer Center/
University Hospitals Seidman Cancer Center
and Cleveland Clinic Taussig Cancer Institute

Andrew Stacey, MD, MS ⌾
Fred Hutchinson Cancer Center

Katy Tsai, MD †
UCSF Helen Diller Family
Comprehensive Cancer Center

Evan Wuthrick, MD §
Moffitt Cancer Center

Yan Xing, MD, PhD †
City of Hope National Medical Center

NCCN
Sara Espinosa, PhD
Nicole McMillian, MS

ϖ Dermatology
‡ Hematology/Hematology oncology
Þ Internal medicine
† Medical oncology
⌾ Ophthalmology
≠ Pathology
¥ Patient advocacy
§ Radiotherapy/Radiation oncology
¶ Surgery/Surgical oncology
* Writing committee member

NCCN Guidelines Panel Disclosures

Version 1.2026, 02/10/26 © 2026 National Comprehensive Cancer Network® (NCCN®), All rights reserved. NCCN Guidelines® and this illustration may not be reproduced in any form without the express written permission of NCCN.

PLEASE NOTE that use of this NCCN Content is governed by the End-User License Agreement, and you MAY NOT distribute this Content or use it with any artificial intelligence model or tool.
Printed by Galya Basol Kochav on 2/13/2026 11:27:31 AM. Copyright © 2026 National Comprehensive Cancer Network, Inc. All Rights Reserved.

UVEAL MELANOMA SUBCOMMITTEE

***Arun Singh, MD/Lead** ۞
Case Comprehensive Cancer Center/ University Hospitals Seidman Cancer Center and Cleveland Clinic Taussig Cancer Institute

Christopher A. Barker, MD §
Memorial Sloan Kettering Cancer Center

Shailender Bhatia, MD †
Fred Hutchinson Cancer Center

Bartosz Chmielowski, MD, PhD ‡ †
UCLA Jonsson Comprehensive Cancer Center

Roxana Dronca, MD †
Mayo Clinic Comprehensive Cancer Center

Samantha Guild ¥
AIM at Melanoma

***Douglas Johnson, MD, MSCI †**
Vanderbilt-Ingram Cancer Center

Miguel Materin, MD ۞
Duke Cancer Institute

April K. Salama, MD †
Duke Cancer Institute

Andrew Stacey, MD, MS ۞
Fred Hutchinson Cancer Center

***Susan Swetter, MD ϖ**
Stanford Cancer Institute

Evan Wuthrick, MD §
Moffitt Cancer Center

ϖ Dermatology
‡ Hematology/Hematology oncology
† Medical oncology
۞ Ophthalmology
¥ Patient advocacy
§ Radiotherapy/Radiation oncology
* Discussion Section Writing Committee

NCCN Guidelines Panel Disclosures

PLEASE NOTE that use of this NCCN Content is governed by the End-User License Agreement, and you MAY NOT distribute this Content or use it with any artificial intelligence model or tool.
Printed by Galya Basol Kochav on 2/13/2026 11:27:31 AM. Copyright © 2026 National Comprehensive Cancer Network, Inc. All Rights Reserved.

NCCN Guidelines Version 1.2026
Melanoma: Uveal

NCCN Uveal Melanoma Panel Members
NCCN Uveal Melanoma Subcommittee Members
Summary of the Guidelines Updates

Clinical Presentation, Workup and Diagnosis, Clinical Staging (UM-1)
Workup and Staging, Tumor Size, Primary Treatment (UM-2)
Additional Primary Treatment (UM-3)
Risk of Distant Metastasis Systemic Imaging Based on Risk Stratification (UM-4)
Treatment for Recurrence (UM-5)
Treatment of Distant Metastatic Disease (UM-6)

Systemic Therapy for Metastatic or Unresectable Disease (UMSYS-1)
Risk Factors for Development of Uveal Melanoma (UM-A)
Principles of Radiation Therapy (UM-B)

Staging (ST-1)

Abbreviations (ABBR-1)

Find an NCCN Member Institution: https://www.nccn.org/home/member-institutions.

NCCN Categories of Evidence and Consensus: All recommendations are category 2A unless otherwise indicated.

See NCCN Categories of Evidence and Consensus.

NCCN Categories of Preference: All recommendations are considered appropriate.

See NCCN Categories of Preference.

The NCCN Guidelines® are a statement of evidence and consensus of the authors regarding their views of currently accepted approaches to treatment. Any clinician seeking to apply or consult the NCCN Guidelines is expected to use independent medical judgment in the context of individual clinical circumstances to determine any patient's care or treatment. The National Comprehensive Cancer Network® (NCCN®) makes no representations or warranties of any kind regarding their content, use or application and disclaims any responsibility for their application or use in any way. The NCCN Guidelines are copyrighted by National Comprehensive Cancer Network®. All rights reserved. The NCCN Guidelines and the illustrations herein may not be reproduced in any form without the express written permission of NCCN. ©2026.

PLEASE NOTE that use of this NCCN Content is governed by the End-User License Agreement, and you MAY NOT distribute this Content or use it with any artificial intelligence model or tool.
Printed by Galya Basol Kochav on 2/13/2026 11:27:31 AM. Copyright © 2026 National Comprehensive Cancer Network, Inc. All Rights Reserved.

Updates in Version 1.2026 of the NCCN Guidelines for Melanoma: Uveal include:

UM-2
- Workup and Staging; 2nd Bullet revised: *Strongly* consider biopsy of primary tumor for prognostic analysis
- Footnote l revised: "... including clinical *trial or* observation in select patients."

UM-2A
- Footnote i revised: "...At minimum, all patients should have contrast-enhanced MR *(preferred)* or ultrasound of the liver..."
- Footnote p revised: Brachytherapy ~~with scleral patch graft~~ or particle beam radiation for cases with limited extraocular extension.

UM-3
- Extraocular extension at the time of enucleation; Bottom pathway recommedations revised:
  - Visible extraocular tumor ~~or suspicion of gross disease in the orbit~~
  - Additional Primary Treatment
    - Biopsy extraocular tissue if possible and consider one or more of the following for local control:
      - ~~Cryotherapy~~
      - *Observation*
      - *Local excision*
      - *RT to orbit*
      - Orbital exenteration
      - ~~RT to orbit~~

UM-4
- Risk of Distant Metastasis; High risk; 4th Bullet revised: BAP1 *somatic* mutation
- Footnote dd revised: ~~Gene expression profile (GEP) class had a stronger independent association with metastasis than any other prognostic factor (P < .0001) (Onken MD, et al. Ophthalmology 2012;119:1596-1603). PRAME expression is a marker for metastasis in Class 1 uveal melanoma tumors, and in Class 2 patients with PRAME expression may be associated with a shorter time to metastasis.~~ *PRAME expression is a risk modifier to the 15-GEP (gene expression profile) signal and may be associated with an increased risk of metastasis in both Class 1 and Class 2 uveal melanoma tumors.* (Harbour JW, et al. J Clin Oncol 2024;42:3319-3329)
- Footnote ff revised: "...For patients who elect to have surveillance imaging, options include: contrast-enhanced MRI (~~most sensitive~~ *preferred*), CT abdomen ± pelvis, or abdominal ultrasound..."

UM-5
- Footnote ii revised: "...Modalities of choice for detection of metastasis are *MRI abdomen with IV gadolinium-based contrast (preferred),* CT chest/abdomen/pelvis with IV iodinated contrast, CT chest with or without IV contrast, ~~and MRI abdomen with IV gadolinium-based contrast~~ or whole-body FDG-PET/CT. (Also for UM-6A)

UM-6
- Treatment of Metastatic Disease, Liver-Directed Therapies revised:
  - 4th Bullet: ~~Consider~~ *R*esection and/or RT ~~(photon beam or SRS for limited or symptomatic disease in the liver)~~

Continued

Version 1.2026, 02/10/26 © 2026 National Comprehensive Cancer Network® (NCCN®), All rights reserved. NCCN Guidelines® and this illustration may not be reproduced in any form without the express written permission of NCCN.

PLEASE NOTE that use of this NCCN Content is governed by the End-User License Agreement, and you MAY NOT distribute this Content or use it with any artificial intelligence model or tool.
Printed by Galya Basol Kochav on 2/13/2026 11:27:31 AM. Copyright © 2026 National Comprehensive Cancer Network, Inc. All Rights Reserved.

Updates in Version 1.2026 of the NCCN Guidelines for Melanoma: Uveal include:

UM-6A
- Footnote ll: "... If disease is confined to the liver, regional therapies such as *percutaneous hepatic perfusion,* chemoembolization, radioembolization..."

UM-A 1 of 2
- Risk Factors for Development of Uveal Melanoma; 1st Bullet; 3rd Arrow Sub-bullet revised: Familial uveal melanoma (eg, germline ~~mutations~~ *pathogenic variants* in BAP1, PALB2, *POT1*, or MBD4
- Footnote b; 1st arrow sub-bullet revised: BRCA*1/BRCA2,* PALB2, *POT1*: breast, ovarian, or pancreatic cancers

UM-A 2 of 2
- References were updated and/or added as follows:
  - ~~Pilarski R, Carlo M, Cebulla C, Abdel-Rahman M. BAP1 Tumor Predisposition Syndrome. In: Adam MP, Ardinger HH, Pagon RA, et al. eds. GeneReviews. Seattle, WA: University of Washington, Seattle. Copyright © 1993-2020, University of Washington, Seattle. GeneReviews is a registered trademark of the University of Washington, Seattle. All rights reserved; 2020.~~ *Pilarski R, Byrne L, Carlo MI, et al. BAP1 Tumor Predisposition Syndrome. In: Adam MP, Feldman J, Mirzaa GM, et al, eds. GeneReviews. Seattle (WA): University of Washington, Seattle; October 13, 2016 [updated 2024 Dec 5].*
  - *Repo PE, Jakkula E, Hiltunen J, et al. Pathogenic germline variants in uveal melanoma driver and BAP1-associated genes in Finnish patients with uveal melanoma. Pigment Cell Melanoma Res 2025;38:e13198.*
  - *Nisanova A, Park SS, Amin A, et al. Novel risk factors for uveal melanoma in adolescent and young adult patients: A comprehensive case-control analysis. Ophthalmol Sci 2024;5:100687.*
  - *Le Ven A, Villy MC, Silveira AB, et al. Uveal melanoma and the Lynch syndrome tumor spectrum. JAMA Ophthalmol 2025;143:661-668.*

UM-B 1 of 4
- New header added: Primary Tumor Radiotherapy

UM-B 2 of 4
- Particle Beam Therapy: Treatment Dosing Information; 4th Arrow sub-bullet revised: "... (intraoperative, *preoperative*, and/or ~~preoperative~~ *postoperative*), *X-ray*, MRI, and/or CT."
- Headers revised
  - *Photon* Stereotactic Radiosurgery
  - *Fractionated* Photon ~~Beam~~ Radiotherapy
    - ◊ This section was extensively revised/reorganized.
- Separate section on Proton Beam Therapy removed.

UM-B 3 of 4
- New header added: Metastasis Directed Radiotherapy

Version 1.2026, 02/10/26 © 2026 National Comprehensive Cancer Network® (NCCN®), All rights reserved. NCCN Guidelines® and this illustration may not be reproduced in any form without the express written permission of NCCN.

PLEASE NOTE that use of this NCCN Content is governed by the End-User License Agreement, and you MAY NOT distribute this Content or use it with any artificial intelligence model or tool.
Printed by Galya Basol Kochav on 2/13/2026 11:27:31 AM. Copyright © 2026 National Comprehensive Cancer Network, Inc. All Rights Reserved.

CLINICAL PRESENTATION[a]

- Suspicious pigmented uveal tumor of ciliary body and/or choroid[b]
  - Symptoms may include:
    - Vision loss
    - Vision changes (eg, blurred vision, photopsia, floaters, metamorphopsia)
  - May be asymptomatic
  - Assess risk factors for developing uveal melanoma[c]

→

WORKUP AND DIAGNOSIS

- Clinical evaluation, including:
  - History and physical (H&P), including personal/family history of prior or current cancers (outside the eye)[b]
  - Comprehensive eye exam: Examine the front and back of eye (biomicroscopy)
    - Perform dilated fundus exam (indirect ophthalmoscopy)
    - Measure visual acuity
    - Measure and document location and size of the tumor (diameter, thickness), distance from disc and fovea, and ciliary body involvement
    - Assess and document if present:
      - Subretinal fluid
      - Orange pigment
- Additional testing options include, but are not limited to:
  - Color fundus photography
  - Ocular ultrasound (including ultrasound biomicroscopy for anterior uveal or ciliary body lesion)
  - Autofluorescence of the ocular fundus
  - Optical coherence tomography
  - Retinal fluorescein angiography of the ocular fundus
  - Transillumination
  - MRI (with and without IV contrast) as clinically indicated to confirm diagnosis
- Consider biopsy, if needed to confirm diagnosis,[d] or for prognostic analysis for risk stratification[e]

CLINICAL STAGING

Diagnosis uncertain (especially for small tumors) and/or <3 risk factors for growth[f] →

- Observe and re-evaluate for growth or features of malignancy[g]
  - Every 2–6 months[h] as clinically indicated
  - Then close follow-up for 5 years[h]
  - Then annually thereafter

Uveal melanoma (per clinical diagnostic criteria) → See Workup and Staging for uveal melanoma (UM-2)

[a] Referral to centers with expertise in the management of uveal melanoma is recommended.
[b] This guideline does not include the management of iris melanoma.
[c] Risk Factors for Development of Uveal Melanoma (UM-A).
[d] Biopsy is usually not necessary for initial diagnosis of uveal melanoma and selection of first-line treatment, but may be useful in cases of uncertainty regarding diagnosis, such as for amelanotic tumors, or retinal detachment.
[e] Biopsy of the primary tumor may provide additional prognostic information that can help inform frequency of follow-up and may be needed for eligibility for clinical trials. Biopsy is typically performed before the tumor is irradiated and can often be performed at the time of primary treatment depending on the procedure modality. If biopsy is performed, molecular/chromosomal testing for prognostication is preferred over cytology alone. The risks/benefits of biopsy for prognostic analysis should be carefully considered and discussed.
[f] Risk factors for growth of small melanocytic tumors: presence of symptoms, tumor thickness >2 mm, tumor diameter >5 mm, presence of subretinal fluid and orange pigment, tumor margin within 3 mm of optic disc, and ultrasound hollowness. Documented growth may indicate progression to uveal melanoma (UM-2).
[g] The recommendation to "observe and re-evaluate" consists of tests listed under "Workup and Diagnosis" that would help to clarify if there is progression and determine the natural history of the indeterminate lesion.
[h] Frequency of evaluation should depend on index of suspicion, patient age, and medical frailty.

Note: All recommendations are category 2A unless otherwise indicated.

Version 1.2026, 02/10/26 © 2026 National Comprehensive Cancer Network® (NCCN®), All rights reserved. NCCN Guidelines® and this illustration may not be reproduced in any form without the express written permission of NCCN.

PLEASE NOTE that use of this NCCN Content is governed by the End-User License Agreement, and you MAY NOT distribute this Content or use it with any artificial intelligence model or tool.
Printed by Galya Basol Kochav on 2/13/2026 11:27:31 AM. Copyright © 2026 National Comprehensive Cancer Network, Inc. All Rights Reserved.

WORKUP AND STAGING

- Ocular imaging if not previously done:
  - If large tumor, close to nerve or suspicion of extraocular involvement, MRI of orbit with and without IV contrast [i]
- Strongly consider biopsy of primary tumor for prognostic analysis[e]
- Assess and document, if present:
  - Ciliary body involvement
  - Extraocular extension
- Extraocular imaging:
  - Baseline imaging to screen for distant disease[i]

TUMOR SIZE / PRIMARY TREATMENT[l]

Largest diameter 5–19 mm[j] and thickness <2.5 mm →

Options:
- Regular ophthalmologic follow-up in select patients[m]
- Brachytherapy plaque[n,o,p]
- Particle beam radiation[n,p]
- Other options in highly select patients[q,r]

Largest diameter ≤19 mm[j] and thickness 2.5–10 mm →

Options:
- Brachytherapy plaque[n,o,p,s]
- Particle beam radiation[n,p,s]
- Enucleation[t,u]

Largest diameter >19 mm[j] (any thickness) or Thickness >10 mm (any diameter) or Thickness >8 mm with optic nerve involvement (any diameter) →

Options:
- Radiation therapy (RT)[n]
- Particle beam radiation[n,p,s]
- Stereotactic radiosurgery (SRS)[n]
- Enucleation[t,u]

→ Additional Primary Treatment (UM-3)

Metastasis[k] → UM-6

[l] Clinical decisions should be informed by a variety of case-specific factors (eg, patient characteristics and preferences like age, status of the other eye, disease characteristics, and medical history), such that for some patients the best clinical approach may be other than one of the listed options, including clinical trial or observation in select patients.

Additional footnotes on UM-2A

Note: All recommendations are category 2A unless otherwise indicated.

Version 1.2026, 02/10/26 © 2026 National Comprehensive Cancer Network® (NCCN®), All rights reserved. NCCN Guidelines® and this illustration may not be reproduced in any form without the express written permission of NCCN.

PLEASE NOTE that use of this NCCN Content is governed by the End-User License Agreement, and you MAY NOT distribute this Content or use it with any artificial intelligence model or tool.
Printed by Galya Basol Kochav on 2/13/2026 11:27:31 AM. Copyright © 2026 National Comprehensive Cancer Network, Inc. All Rights Reserved.

FOOTNOTES FOR UM-2

[e] Biopsy of the primary tumor may provide additional prognostic information that can help inform frequency of follow-up and may be needed for eligibility for clinical trials. Biopsy is typically performed before the tumor is irradiated and can often be performed at the time of primary treatment depending on the procedure modality. If biopsy is performed, molecular/chromosomal testing for prognostication is preferred over cytology alone. The risks/benefits of biopsy for prognostic analysis should be carefully considered and discussed.

[i] The most frequent site of metastasis is the liver; other sites include lungs, skin/soft tissue, and bones. At minimum, all patients should have contrast-enhanced MR (preferred) or ultrasound of the liver, with modality preference determined by expertise at the treating institution. Additional imaging modalities may include chest/abdomen/pelvis CT with and without contrast. Scans should be performed with IV contrast unless contraindicated.

[j] The cutoff for largest basal diameter depends on the dimensions of the largest brachytherapy plaque available, so it may depend on the type of plaque and isotope selected if brachytherapy is used.

[k] Patients may be considered for palliative local therapy to the primary tumor in the setting of metastatic disease. Patients who present with advanced metastatic disease and limited life expectancy may elect to have no treatment to their primary tumor.

[m] For patients who meet the criteria for observation, regular ophthalmologic follow-up is recommended to re-evaluate for growth.

[n] Principles of Radiation Therapy (UM-B).

[o] The plaque should cover the tumor with a ≥2 mm circumferential margin. The exception is for tumors near the optic nerve where it may be impossible to achieve adequate coverage of the margins. The largest commercially available brachytherapy plaque is 23 mm in diameter; thus, plaque brachytherapy is recommended only for tumors with largest basal diameter ≤19 mm and can be considered for select cases with tumors >10 mm in height.

[p] Brachytherapy or particle beam radiation for cases with limited extraocular extension.

[q] Consider laser treatment or enucleation (per patient preference) for patients who are not good candidates for brachytherapy or particle beam radiation.

[r] For small ciliary body tumors (less than 3 clock hours), surgical excision may be considered.

[s] Consider additional treatment with resection, laser ablation, transpupillary thermotherapy, or cryotherapy if concern that adequate response was not achieved from initial radiation.

[t] While there is a trend toward avoiding enucleation, it is recommended for patients with neovascular glaucoma, tumor replacing >50% of globe, or blind, painful eyes. Consider enucleation in cases of extensive extraocular extension.

[u] Pathologic evaluation should follow the uveal melanoma synoptic report recommendations by the College of American Pathologists. Available at: https://documents.cap.org/protocols/cp-uveal-melanoma-17protocol-4000.pdfv

Note: All recommendations are category 2A unless otherwise indicated.

Version 1.2026, 02/10/26 © 2026 National Comprehensive Cancer Network® (NCCN®), All rights reserved. NCCN Guidelines® and this illustration may not be reproduced in any form without the express written permission of NCCN.

PLEASE NOTE that use of this NCCN Content is governed by the End-User License Agreement, and you MAY NOT distribute this Content or use it with any artificial intelligence model or tool.
Printed by Galya Basol Kochav on 2/13/2026 11:27:31 AM. Copyright © 2026 National Comprehensive Cancer Network, Inc. All Rights Reserved.

ADDITIONAL PRIMARY TREATMENT

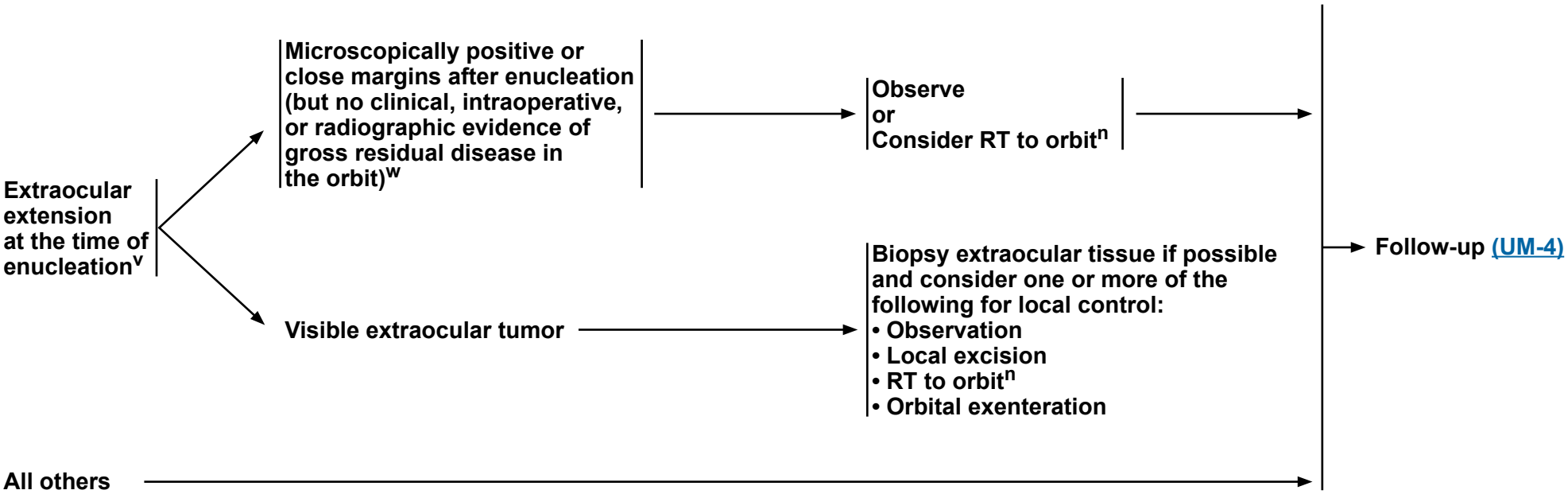

[n] Principles of Radiation Therapy (UM-B).
[v] This is a relatively rare occurrence; data are limited for these recommendations.
[w] Consider orbital biopsy if clinically appropriate.

Note: All recommendations are category 2A unless otherwise indicated.

Version 1.2026, 02/10/26 © 2026 National Comprehensive Cancer Network® (NCCN®), All rights reserved. NCCN Guidelines® and this illustration may not be reproduced in any form without the express written permission of NCCN.

PLEASE NOTE that use of this NCCN Content is governed by the End-User License Agreement, and you MAY NOT distribute this Content or use it with any artificial intelligence model or tool.
Printed by Galya Basol Kochav on 2/13/2026 11:27:31 AM. Copyright © 2026 National Comprehensive Cancer Network, Inc. All Rights Reserved.

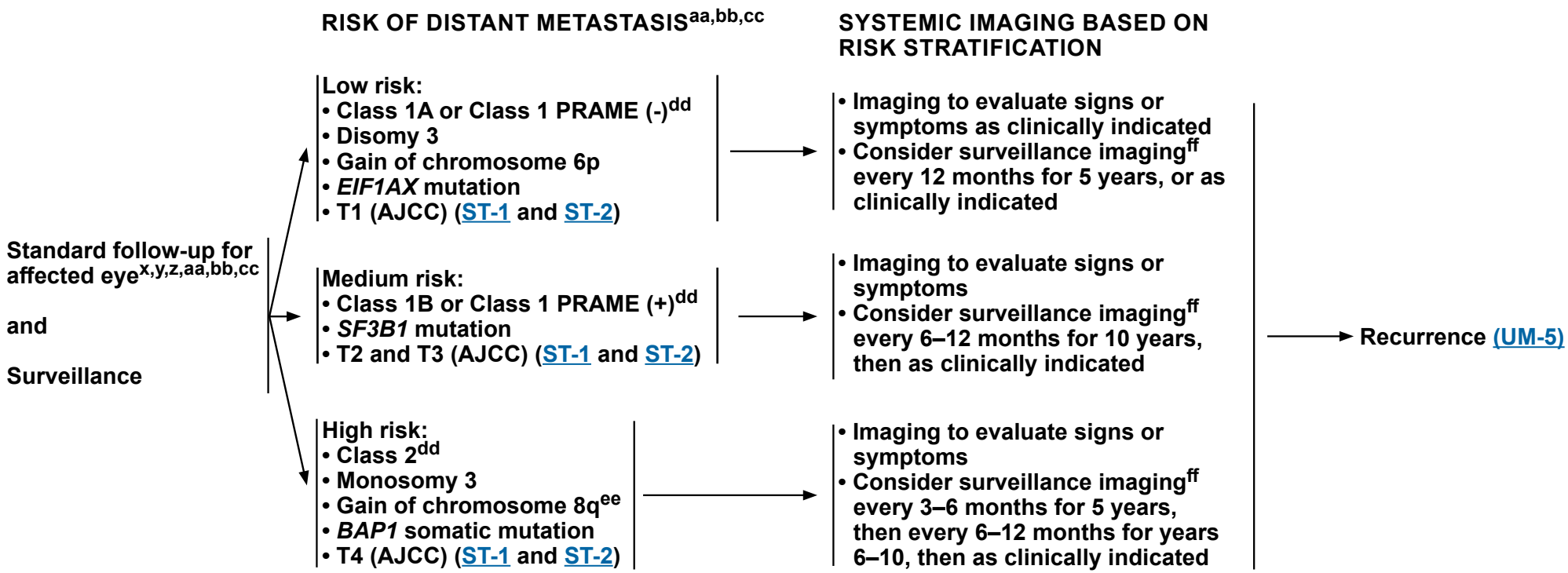

[bb] Risk stratification to determine the frequency of follow-up should be based on the highest risk factor present.

[x] The affected eye should be imaged with color fundus photography and ultrasonography every 3–6 months for 3–5 years, then every 6–12 months thereafter, if stable. Serial orbital MRI may be used as clinically indicated. The frequency of follow-up should depend on the size and location (eg, juxtapapillary location, ciliary body involvement) of the tumor at presentation. Radiation-related retinopathy and other treatment-related complications may occur at any time following treatment.

[y] The contralateral eye is not at increased risk of uveal melanoma, and should be followed with routine ophthalmologic care including routine eye protection for the remaining eye (eg, polycarbonate glasses).

[z] Liver function tests (LFTs) may be considered as part of follow-up, although some studies showed poor sensitivity for early detection of liver metastases.

[aa] If biopsy is not performed, then follow medium- or high-risk pathways depending on whether any high-risk features are present.

Note: All recommendations are category 2A unless otherwise indicated.

[cc] Additional risk factors for recurrence: juxtapapillary location and ciliary body involvement.

[dd] PRAME expression is a risk modifier to the 15-GEP (gene expression profile) signal and may be associated with an increased risk of metastasis in both Class 1 and Class 2 uveal melanoma tumors. (Harbour JW, et al. J Clin Oncol 2024;42:3319-3329)

[ee] 8q gain, especially when numerous copies are found, portends greater risk for metastasis.

[ff] The most frequent site of metastasis is the liver; other sites include lungs, skin/soft tissue, and bones. For patients who elect to have surveillance imaging, options include: contrast-enhanced MRI (preferred), CT abdomen ± pelvis, or abdominal ultrasound, with modality preference determined by expertise at the treating institution. Chest imaging can be done with CT chest without contrast, or chest x-ray.

Version 1.2026, 02/10/26 © 2026 National Comprehensive Cancer Network® (NCCN®), All rights reserved. NCCN Guidelines® and this illustration may not be reproduced in any form without the express written permission of NCCN.

PLEASE NOTE that use of this NCCN Content is governed by the End-User License Agreement, and you MAY NOT distribute this Content or use it with any artificial intelligence model or tool.
Printed by Galya Basol Kochav on 2/13/2026 11:27:31 AM. Copyright © 2026 National Comprehensive Cancer Network, Inc. All Rights Reserved.

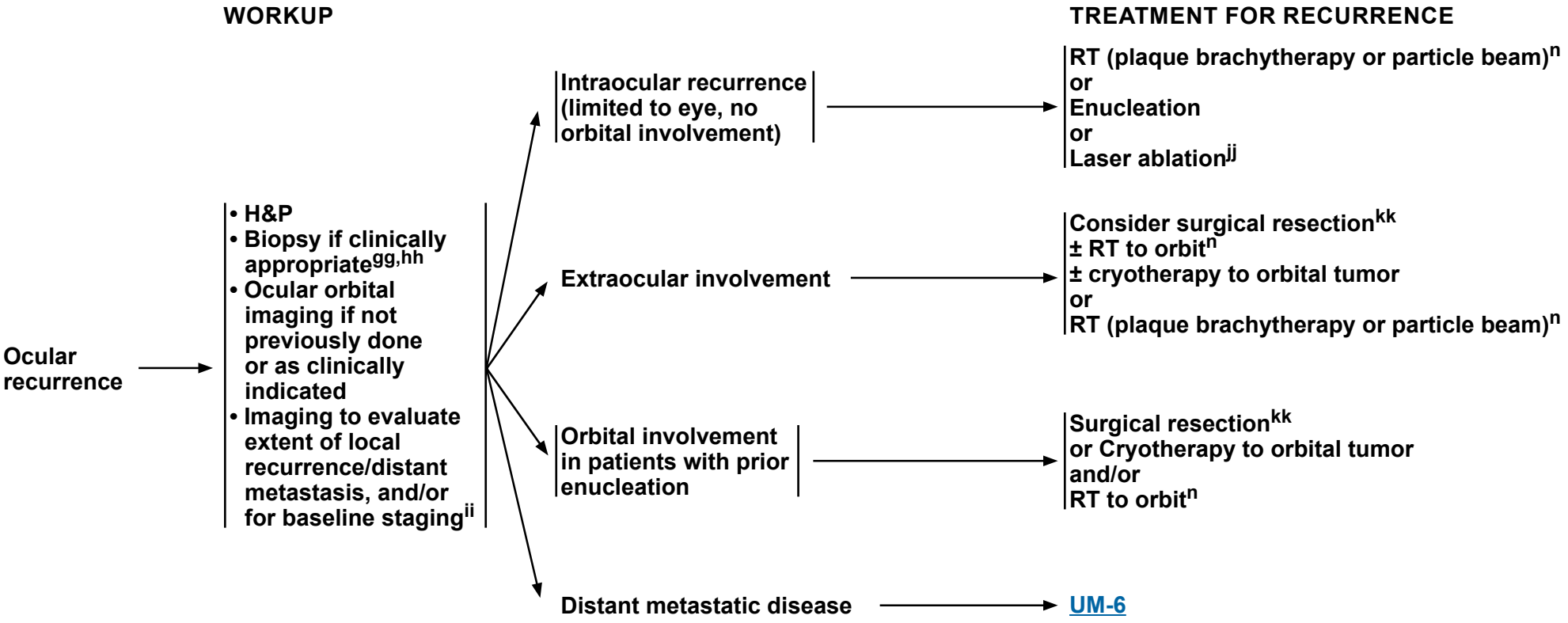

[n] Principles of Radiation Therapy (UM-B).
[gg] Extraocular recurrence or metastasis should be confirmed histologically whenever possible or if clinically indicated. Biopsy techniques may include core needle biopsy, if possible, or otherwise fine-needle aspiration (FNA). Consider genetic testing if it might affect treatment options.
[hh] Intraocular recurrence can often be diagnosed and managed without a biopsy. Additional prognostic FNA biopsy may be valuable.
[ii] The most frequent site of metastasis is the liver; other sites include lungs, skin/soft tissue, and bones. Modalities of choice for detection of metastasis are MRI abdomen with IV gadolinium-based contrast (preferred), CT chest/abdomen/pelvis with IV iodinated contrast, CT chest with or without IV contrast, or whole-body FDG-PET/CT. In select patients with renal failure and/or iodinated contrast allergy, MR abdomen with gadolinium-based contrast is the preferred imaging study over CT. If no IV contrast can be administered, MR without contrast is superior to nonenhanced CT. Ultrasound evaluation of the liver can be used in select patients; however, it has limited value given its operator-dependent nature, limited sensitivity in patients with obesity, and lack of specificity. Brain MRI with IV contrast may be performed if neurologic symptoms are present, but routine CNS imaging is not recommended. Abdominal imaging should be performed with IV contrast unless contraindicated.
[jj] For small recurrences in patients who cannot undergo RT or surgery, transpupillary thermotherapy is recommended.
[kk] Surgical resection may potentially include partial orbital tumor resection, enucleation, or exenteration.

Note: All recommendations are category 2A unless otherwise indicated.

Version 1.2026, 02/10/26 © 2026 National Comprehensive Cancer Network® (NCCN®), All rights reserved. NCCN Guidelines® and this illustration may not be reproduced in any form without the express written permission of NCCN.

PLEASE NOTE that use of this NCCN Content is governed by the End-User License Agreement, and you MAY NOT distribute this Content or use it with any artificial intelligence model or tool.
Printed by Galya Basol Kochav on 2/13/2026 11:27:31 AM. Copyright © 2026 National Comprehensive Cancer Network, Inc. All Rights Reserved.

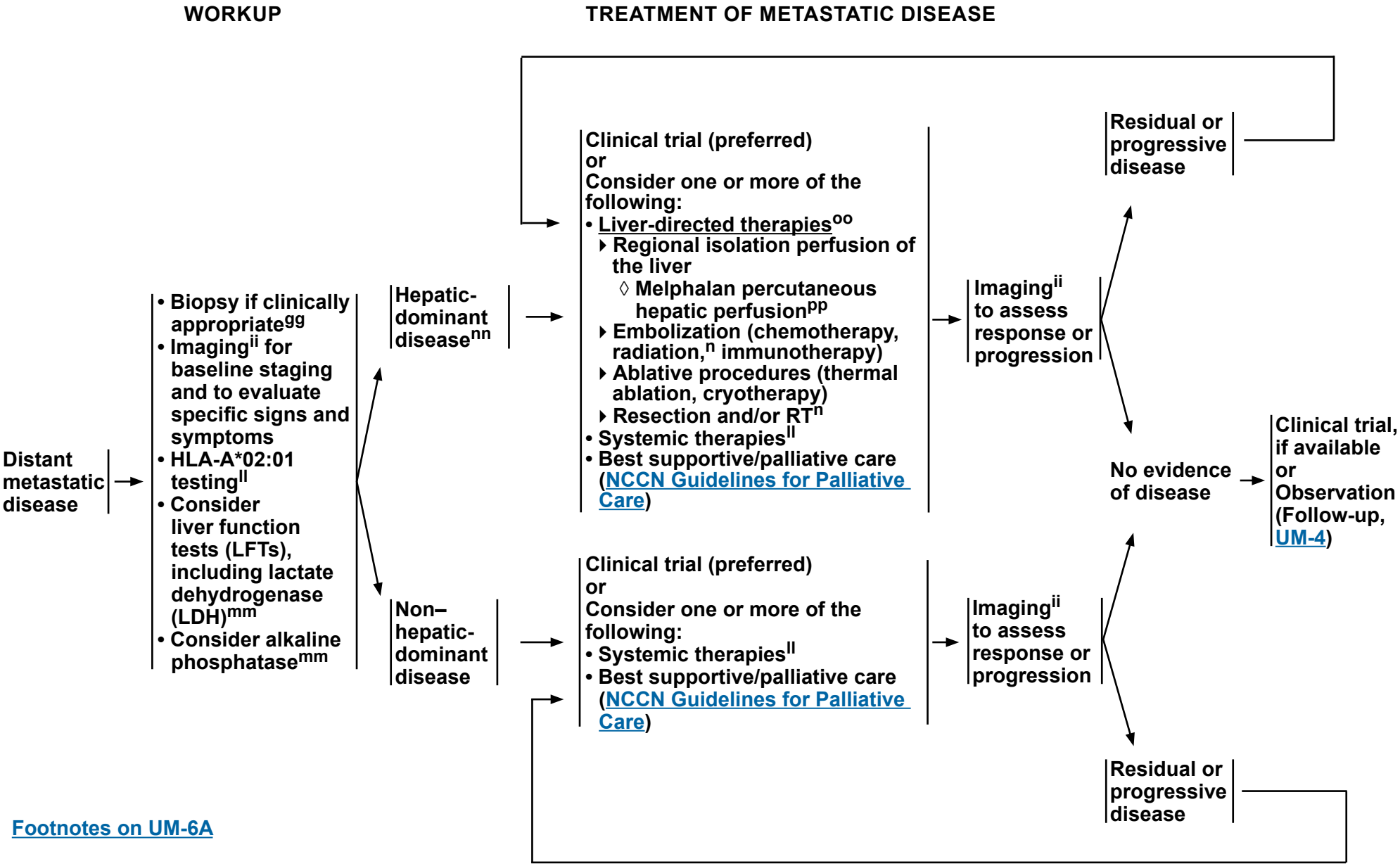

Footnotes on UM-6A

Note: All recommendations are category 2A unless otherwise indicated.

Version 1.2026, 02/10/26 © 2026 National Comprehensive Cancer Network® (NCCN®), All rights reserved. NCCN Guidelines® and this illustration may not be reproduced in any form without the express written permission of NCCN.

PLEASE NOTE that use of this NCCN Content is governed by the End-User License Agreement, and you MAY NOT distribute this Content or use it with any artificial intelligence model or tool.
Printed by Galya Basol Kochav on 2/13/2026 11:27:31 AM. Copyright © 2026 National Comprehensive Cancer Network, Inc. All Rights Reserved.

FOOTNOTES FOR UM-6

[n] Principles of Radiation Therapy (UM-B).

[gg] Extraocular recurrence or metastasis should be confirmed histologically whenever possible or if clinically indicated. Biopsy techniques may include core needle biopsy, if possible, or otherwise FNA. Consider genetic testing if it might affect treatment options.

[ii] The most frequent site of metastasis is the liver; other sites include lungs, skin/soft tissue, and bones. Modalities of choice for detection of metastasis are MRI abdomen with IV gadolinium-based contrast (preferred), CT chest/abdomen/pelvis with IV iodinated contrast, CT chest with or without IV contrast, or whole-body FDG-PET/CT. In select patients with renal failure and/or iodinated contrast allergy, MR abdomen with gadolinium-based contrast is the preferred imaging study over CT. If no IV contrast can be administered, MR without contrast is superior to nonenhanced CT. Ultrasound evaluation of the liver can be used in select patients; however, it has limited value given its operator-dependent nature, limited sensitivity in patients with obesity, and lack of specificity. Brain MRI with IV contrast may be performed if neurologic symptoms are present, but routine CNS imaging is not recommended. Abdominal imaging should be performed with IV contrast unless contraindicated.

[ll] A phase III randomized trial was conducted in previously untreated HLA A*02:01-positive, metastatic uveal melanoma. Patients were randomized to receive tebentafusp-tebn (a bispecific protein) or investigator's choice of either pembrolizumab, ipilimumab, or dacarbazine. Treatment with tebentafusp-tebn resulted in longer overall survival (OS) compared to control therapy. Agents that are effective for metastatic cutaneous melanoma may be used as first-line therapy for HLA-A*02:01-negative disease and after disease progression with first-line use of tebentafusp-tebn for HLA-A*02:01-positive disease. If disease is confined to the liver, regional therapies such as percutaneous hepatic perfusion, chemoembolization, radioembolization, or immunoembolization should be considered. Since tebentafusp-tebn response rates are low, symptomatic patients may be better palliated by liver-directed treatment first or their disease may respond better to ipilimumab/nivolumab. See Systemic Therapy for Metastatic or Unresectable Disease (UMSYS-1).

[mm] LDH and alkaline phosphatase may assist in determining prognosis in the setting of uveal melanoma (Khoja L, et al. Ann Oncol 2019;30:1370-1380).

[nn] The bulk of overall metastatic disease is confined to the liver.

[oo] Liver-directed therapies have efficacy largely in hepatic-dominant metastatic uveal melanoma and are thus recommended only in this setting.

[pp] Melphalan percutaneous hepatic perfusion was tested in patients with hepatic-dominant metastatic uveal melanoma with <50% liver involvement and was associated with a 36.6% response rate in a 91-patient phase II trial, and with improved response rate (36.3% vs. 12.5%) and median progression-free survival (PFS) (9 vs. 3.1 months) compared with best alternative care in a phase III trial (n = 123 treated). Median OS was similar (19.3 vs. 14.5 months; *P* = .14). Overnight stay in intensive care unit is recommended for hemodynamic monitoring; this therapy is recommended only at experienced centers. Prescribing information is available at: https://www.accessdata.fda.gov/drugsatfda_docs/label/2023/201848s000lbl.pdf. (Hughes MS, et al. Ann Surg Oncol 2016;23:1309-1319; Olofsson Bagge R, et al. J Clin Oncol 2023;41:3042-3050).

Note: All recommendations are category 2A unless otherwise indicated.

Version 1.2026, 02/10/26 © 2026 National Comprehensive Cancer Network® (NCCN®), All rights reserved. NCCN Guidelines® and this illustration may not be reproduced in any form without the express written permission of NCCN.

PLEASE NOTE that use of this NCCN Content is governed by the End-User License Agreement, and you MAY NOT distribute this Content or use it with any artificial intelligence model or tool.
Printed by Galya Basol Kochav on 2/13/2026 11:27:31 AM. Copyright © 2026 National Comprehensive Cancer Network, Inc. All Rights Reserved.

SYSTEMIC THERAPY FOR METASTATIC OR UNRESECTABLE DISEASE[a,b]

Preferred	Other Recommended	Useful in Certain Circumstances
• When available and clinically appropriate, enrollment in a clinical trial is recommended. • Tebentafusp-tebn in patients who are HLA-A*02:01-positive (category 1)[c] • Immune checkpoint inhibitors[d,e] ▸ Ipilimumab + Nivolumab[f,g]	Immune checkpoint inhibitors[d,e] • Ipilimumab • Anti-PD-1 monotherapy ▸ Pembrolizumab[h] ▸ Nivolumab[i]	Consider one or more of the following options: • Cytotoxic regimens ▸ Dacarbazine ▸ Temozolomide ▸ Paclitaxel ▸ Albumin-bound Paclitaxel ▸ Carboplatin/Paclitaxel • Targeted therapy[j,k] ▸ Trametinib

[a] The order of listed systemic therapies in a given section does not reflect order of preference. The choice of treatment is based on evaluation of the individual patient, which includes patient characteristics, disease presentation, health system resources/experience, and patient preference.
[b] Referral to centers with expertise in the management of uveal melanoma is recommended.
[c] A phase III randomized trial was conducted in previously untreated HLA-A*02:01-positive, metastatic uveal melanoma. Patients were randomized to receive tebentafusp-tebn (a bispecific protein) or investigator's choice of either pembrolizumab, ipilimumab, or dacarbazine. Treatment with tebentafusp-tebn resulted in longer OS compared to control therapy. Agents that are effective for metastatic cutaneous melanoma may be used as first-line therapy for HLA-A*02:01-negative disease and after disease progression with first-line use of tebentafusp-tebn for HLA-A*02:01-positive disease. If disease is confined to the liver, regional therapies such as chemoembolization, radioembolization, or immunoembolization should be considered. Since tebentafusp-tebn response rates are low, symptomatic patients may be better palliated by liver-directed treatment first (UM-6) or their disease may respond better to ipilimumab/nivolumab.
[d] Immune checkpoint inhibitors have inferior activity in uveal melanoma compared with cutaneous melanoma, though may still produce durable benefit in a minority of patients. Small prospective or retrospective studies have shown response rates of 0%–5% for anti-programmed cell death protein 1 (PD-1) or ipilimumab monotherapy, and 5%–20% for nivolumab 1 mg/kg and ipilimumab 3 mg/kg. No prospective studies have demonstrated differences in OS between immune checkpoint inhibitor regimens.
[e] NCCN Guidelines for Management of Immune Checkpoint Inhibitor-Related Toxicities.
[f] Studies of nivolumab/ipilimumab have used a dose of nivolumab 1 mg/kg and ipilimumab 3 mg/kg; it is unknown whether other dosing regimens (ie, nivolumab 3 mg/kg and ipilimumab 1 mg/kg) are equally effective in uveal melanoma.
[g] Nivolumab and hyaluronidase-nvhy is not approved for concurrent use with IV ipilimumab; however, for nivolumab monotherapy, nivolumab and hyaluronidase-nvhy subcutaneous injection may be substituted for IV nivolumab. Nivolumab and hyaluronidase-nvhy has different dosing and administration instructions compared to IV nivolumab.
[h] Pembrolizumab and berahyaluronidase alfa-pmph subcutaneous injection may be substituted for IV pembrolizumab. Pembrolizumab and berahyaluronidase alfa-pmph has different dosing and administration instructions compared to IV pembrolizumab.
[i] Nivolumab and hyaluronidase-nvhy subcutaneous injection may be substituted for IV nivolumab. Nivolumab and hyaluronidase-nvhy has different dosing and administration instructions compared to IV nivolumab.
[j] See Management of Toxicities Associated with Targeted and Immune Therapies in the NCCN Guidelines for Melanoma: Cutaneous.
[k] The listed systemic therapy options do not cover *BRAF*- or *KIT*-mutated tumors. In general, uveal melanomas rarely have *BRAF* or *KIT* mutations.

Note: All recommendations are category 2A unless otherwise indicated.

References

Version 1.2026, 02/10/26 © 2026 National Comprehensive Cancer Network® (NCCN®), All rights reserved. NCCN Guidelines® and this illustration may not be reproduced in any form without the express written permission of NCCN.

PLEASE NOTE that use of this NCCN Content is governed by the End-User License Agreement, and you MAY NOT distribute this Content or use it with any artificial intelligence model or tool.
Printed by Galya Basol Kochav on 2/13/2026 11:27:31 AM. Copyright © 2026 National Comprehensive Cancer Network, Inc. All Rights Reserved.

SYSTEMIC THERAPY FOR METASTATIC OR UNRESECTABLE DISEASE REFERENCES

Immunotherapy

Tebentafusp-tebn for HLA A*02:01-positive tumors
- Nathan P, Hassel JC, Rutkowski P, et al. Overall survival benefit with tebentafusp in metastatic uveal melanoma. N Engl J Med 2021;385:1196-1206.

Nivolumab/ipilimumab
- Piulats JM, Espinosa E, de la Cruz Merino L, et al. Nivolumab plus ipilimumab for treatment-naive metastatic uveal melanoma: An open-label, multicenter, phase II trial by the Spanish Multidisciplinary Melanoma Group (GEM-1402). J Clin Oncol 2021;39:586-598.
- Pelster MS, Gruschkus SK, Bassett R, et al. Nivolumab and ipilimumab in metastatic uveal melanoma: Results from a single-arm phase II study. J Clin Oncol 2021;39:599-607.

Ipilimumab
- Zimmer L, Vaubel J, Mohr P, et al. Phase II DeCOG-study of ipilimumab in pretreated and treatment-naive patients with metastatic uveal melanoma. PLoS One 2015;10:e0118564.
- Danielli R, Ridolfi R, Chiarion-Sileni V, et al. Ipilimumab in pretreated patients with metastatic uveal melanoma: safety and clinical efficacy. Cancer Immunol Immunother 2012;61:41-48.
- Luke JJ, Callahan MK, Postow MA, et al. Clinical activity of ipilimumab for metastatic uveal melanoma: a retrospective review of the Dana-Farber Cancer Institute, Massachusetts General Hospital, Memorial Sloan-Kettering Cancer Center, and University Hospital of Lausanne experience. Cancer 2013;119:3687-3695.

Pembrolizumab and nivolumab
- Kottschade LA, McWilliams RR, Markovic SN, et al. The use of pembrolizumab for the treatment of metastatic uveal melanoma. Melanoma Res 2016;26:300-303.
- Algazi AP, Tsai KK, Shoushtari AN, et al. Clinical outcomes in metastatic uveal melanoma treated with PD-1 and PD-L1 antibodies. Cancer 2016;122:3344-3353.

Cytotoxic Regimens

Dacarbazine
- Serrone L, Zeuli M, Sega FM, et al. Dacarbazine-based chemotherapy for metastatic melanoma: thirty-year experience overview. J Exp Clin Cancer Res 2000;19:21-34.

Temozolomide
- Bedikian AY, Papadopoulos N, Plager C, et al. Phase II evaluation of temozolomide in metastatic choroidal melanoma. Melanoma Res 2003;13:303-306.

Paclitaxel
- Wiernik PH, Einzig AI. Taxol in malignant melanoma. J Natl Cancer Inst Monogr 1993;15:185-187.

Albumin-bound paclitaxel
- Hersh EM, O'Day SJ, Ribas A, et al. A phase 2 clinical trial of nab-paclitaxel in previously treated and chemotherapy-naïve patients with metastatic melanoma. Cancer 2010;116:155-163.
- Kottschade LA, Suman VJ, Amatruda T, et al. A phase II trial of nab-paclitaxel (ABI-007) and carboplatin in patients with unresectable stage iv melanoma: a north central cancer treatment group study, N057E(1). Cancer 2011;117:1704-1710.

Carboplatin/paclitaxel
- Rao RD, Holtan SG, Ingle JN, et al. Combination of paclitaxel and carboplatin as second-line therapy for patients with metastatic melanoma. Cancer 2006;106:375-382.
- Homsi J, Bedikian AY, Papadopoulos NE, et al. Phase 2 open-label study of weekly docosahexaenoic acid-paclitaxel in patients with metastatic uveal melanoma. Melanoma Res 2010;20:507-510.

Targeted Therapy

Trametinib
- Falchook GS, Lewis KD, Infante JR, et al. Activity of the oral MEK inhibitor trametinib in patients with advanced melanoma: a phase 1 dose-escalation trial. Lancet Oncol 2012;13:782-789.
- Shoushtari AN, Kudchadkar RR, Panageas K, et al. A randomized phase 2 study of trametinib with or without GSK2141795 in patients with advanced uveal melanoma. J Clin Oncol 2016;34:9511-9511.

Note: All recommendations are category 2A unless otherwise indicated.

Version 1.2026, 02/10/26 © 2026 National Comprehensive Cancer Network® (NCCN®), All rights reserved. NCCN Guidelines® and this illustration may not be reproduced in any form without the express written permission of NCCN.

PLEASE NOTE that use of this NCCN Content is governed by the End-User License Agreement, and you MAY NOT distribute this Content or use it with any artificial intelligence model or tool.
Printed by Galya Basol Kochav on 2/13/2026 11:27:31 AM. Copyright © 2026 National Comprehensive Cancer Network, Inc. All Rights Reserved.

RISK FACTORS FOR DEVELOPMENT OF UVEAL MELANOMA

- Patients with the following risk factors are at increased risk of developing uveal melanoma:
  - Choroidal nevi[a]
  - Ocular/oculodermal melanocytosis (hyperpigmentation of episclera, uvea, and skin)
  - Familial uveal melanoma (eg, germline pathogenic variants in *BAP1*, *PALB2*, *POT1*, or *MBD4*)[1-9]
  - Light skin color, propensity to sunburn, and/or light eye (iris) color[10]
  - Strong personal or family history of cancer[b,11]
  - Occupational history of welding[12]
- The presence of cutaneous melanoma does not increase the risk of uveal melanoma. Among patients with cutaneous melanoma, routine screening for uveal melanoma is not required.

[a] Risk factors for growth of small melanocytic tumors: presence of symptoms, tumor thickness >2 mm, tumor diameter >5 mm, presence of subretinal fluid and orange pigment, tumor margin within 3 mm of optic disc, and ultrasound hollowness. Documented growth may indicate progression to uveal melanoma (UM-2).

[b] Evaluate for evidence of hereditary syndrome and refer for genetic counseling and testing if indicated:
- Early age of diagnosis (<30 years of age)
- History of other primary cancers in the patient
- Family or personal history of other cancers known to be associated with a hereditary syndrome:
  - *BRCA1/BRCA2,*[8] *PALB2, POT1*: breast, ovarian, or pancreatic cancers
  - *BAP1*: Mesothelioma, cutaneous melanoma, renal cell carcinoma, basal cell carcinoma, hepatocellular carcinoma, cholangiocarcinoma, or meningioma[1]

Note: All recommendations are category 2A unless otherwise indicated.

References

Version 1.2026, 02/10/26 © 2026 National Comprehensive Cancer Network® (NCCN®), All rights reserved. NCCN Guidelines® and this illustration may not be reproduced in any form without the express written permission of NCCN.

PLEASE NOTE that use of this NCCN Content is governed by the End-User License Agreement, and you MAY NOT distribute this Content or use it with any artificial intelligence model or tool.
Printed by Galya Basol Kochav on 2/13/2026 11:27:31 AM. Copyright © 2026 National Comprehensive Cancer Network, Inc. All Rights Reserved.

RISK FACTORS FOR DEVELOPMENT OF UVEAL MELANOMA
REFERENCES

[1] Walpole S, Pritchard AL, Cebulla CM, et al. Comprehensive study of the clinical phenotype of germline BAP1 variant-carrying families worldwide. J Natl Cancer Inst 2018;110:1328-1341.
[2] Abdel-Rahman MH, Pilarski R, Cebulla CM, et al. Germline BAP1 mutation predisposes to uveal melanoma, lung adenocarcinoma, meningioma, and other cancers. J Med Genet 2011;48:856-859.
[3] Pilarski R, Byrne L, Carlo MI, et al. BAP1 Tumor Predisposition Syndrome. In: Adam MP, Feldman J, Mirzaa GM, et al, eds. GeneReviews. Seattle (WA): University of Washington, Seattle; October 13, 2016 [updated 2024 Dec 5].
[4] Derrien AC, Rodrigues M, Eeckhoutte A, et al. Germline MBD4 mutations and predisposition to uveal melanoma. J Natl Cancer Inst 2021;113:80-87.
[5] Abdel-Rahman MH, Sample KM, Pilarski R, et al. Whole exome sequencing identifies candidate genes associated with hereditary predisposition to uveal melanoma. Ophthalmology 2020;127:668-678.
[6] Abdel-Rahman MH, Pilarski R, Ezzat S, et al. Cancer family history characterization in an unselected cohort of 121 patients with uveal melanoma. Fam Cancer 2010;9:431-438.
[7] Singh N, Singh R, Bowen RC, et al. Uveal melanoma in BAP1 tumor predisposition syndrome: Estimation of risk. Am J Ophthalmol 2020;224:172-177.
[8] Repo PE, Jakkula E, Hiltunen J, et al. Pathogenic germline variants in uveal melanoma driver and BAP1-associated genes in Finnish patients with uveal melanoma. Pigment Cell Melanoma Res 2025;38:e13198.
[9] Nisanova A, Park SS, Amin A, et al. Novel risk factors for uveal melanoma in adolescent and young adult patients: A comprehensive case-control analysis. Ophthalmol Sci 2024;5:100687.
[10] Houtzager LE, Annemijn PA, Wierenga APA, et al. Iris colour and the risk of developing uveal melanoma. Int J Mol Sci 2020;21:7172.
[11] Le Ven A, Villy MC, Silveira AB, et al. Uveal melanoma and the Lynch syndrome tumor spectrum. JAMA Ophthalmol 2025;143:661-668.
[12] Falcone LM, Zeidler-Erdely PC. Skin cancer and welding. Clin Exp Dermatol 2019;44:130-134.

Note: All recommendations are category 2A unless otherwise indicated.

Version 1.2026, 02/10/26 © 2026 National Comprehensive Cancer Network® (NCCN®), All rights reserved. NCCN Guidelines® and this illustration may not be reproduced in any form without the express written permission of NCCN.

PLEASE NOTE that use of this NCCN Content is governed by the End-User License Agreement, and you MAY NOT distribute this Content or use it with any artificial intelligence model or tool.
Printed by Galya Basol Kochav on 2/13/2026 11:27:31 AM. Copyright © 2026 National Comprehensive Cancer Network, Inc. All Rights Reserved.

PRINCIPLES OF RADIATION THERAPY

PRIMARY TUMOR RADIOTHERAPY

Plaque Brachytherapy

- Treatment Information
  - Plaque brachytherapy is a common form of definitive radiotherapy for the primary tumor.[1] A prospective trial found no difference in cause-specific survival among patients with tumors 2.5–10 mm in apical height (2.5–8 mm if peripapillary) and ≤16 mm in maximum basal diameter randomized to plaque brachytherapy or enucleation.[2]
  - Plaque brachytherapy is appropriate for patients with tumors ≤19 mm[a] in largest basal diameter and ≤10 mm in thickness. It may be used selectively in patients with larger tumors.
  - Plaque brachytherapy is appropriate as an upfront therapy after initial diagnosis, or after local recurrence following a prior local therapy.
  - Plaque brachytherapy should be performed by an experienced multidisciplinary team including an ophthalmic oncologist, radiation oncologist, and brachytherapy physicist.[3]
  - Tumor localization for brachytherapy may be performed using indirect ophthalmoscopy, transillumination, light pipe diathermy, and/or ultrasound (intraoperative and/or preoperative).[4] MRI or CT may be used for preoperative planning.
  - Round or custom plaques are most commonly used. Custom plaques, such as notched plaques, are commonly used for tumors in specific locations (peripapillary).
- Treatment Dosing Information
  - Using iodine-125 Collaborative Ocular Melanoma Study (COMS) plaques, 85 Gy should be prescribed to the tumor apex at low dose-rate (≥0.6 Gy/h). Dose adjustments may need to be made for non-COMS plaques.[5-7] The plaque margin on the tumor border should be ≥2 mm when feasible (diameter of plaque ≥4 mm larger than largest basal diameter of tumor). The exception is for tumors near the optic nerve where it may be impossible to achieve adequate coverage of the margins. The largest commercially available brachytherapy plaque is 23 mm[a] in diameter; thus, plaque brachytherapy is recommended only for tumors with largest basal diameter ≤19 mm.
  - Using other radioisotopes (eg, ruthenium-106, palladium-103, strontium-90, cobalt-60, cesium-131), or non-COMS iodine-125 plaques, 60–100 Gy may be prescribed at low dose-rate to the tumor apex; alternatively, a minimum dose may be prescribed to the tumor base. The plaque margin on the tumor border may vary for other radioisotopes.

[a] The cutoff for largest basal diameter depends on the dimensions of the largest brachytherapy plaque available, so it may depend on the type of plaque and isotope selected if brachytherapy is used.

Note: All recommendations are category 2A unless otherwise indicated.

References

Version 1.2026, 02/10/26 © 2026 National Comprehensive Cancer Network® (NCCN®), All rights reserved. NCCN Guidelines® and this illustration may not be reproduced in any form without the express written permission of NCCN.

PLEASE NOTE that use of this NCCN Content is governed by the End-User License Agreement, and you MAY NOT distribute this Content or use it with any artificial intelligence model or tool.
Printed by Galya Basol Kochav on 2/13/2026 11:27:31 AM. Copyright © 2026 National Comprehensive Cancer Network, Inc. All Rights Reserved.

PRINCIPLES OF RADIATION THERAPY

Particle Beam Therapy

- Treatment Dosing Information
  - Particle beam therapy is a common form of definitive radiotherapy for the primary tumor.[1] A prospective trial found no difference in cause-specific survival among patients with tumors ≤15 mm in maximum basal diameter and ≤11 mm in apical height randomized to plaque brachytherapy or particle beam therapy.[8]
  - Particle beam therapy is appropriate as upfront therapy after initial diagnosis, after margin-positive enucleation, or for intraocular or orbital recurrence.
  - Particle beam therapy should be performed by an experienced multidisciplinary team including an ophthalmic oncologist, radiation oncologist, and particle beam physicist.[9]
  - Tumor localization for particle beam therapy may be performed using indirect ophthalmoscopy, transillumination, and/or ultrasound (intraoperative, preoperative, and/or postoperative), X-ray, MRI, and/or CT.[10]
  - For intraocular tumors:
    - Using protons, 50–70 cobalt Gray equivalent (CGyE) in 4–5 fractions should be prescribed to encompass the planning target volume surrounding the tumor.[9-12,b]
    - Using carbon ions, 60–85 CGyE in 5 fractions should be prescribed to encompass the planning target volume surrounding the tumor.[13]
    - Fiducial markers (tantalum clips) are encouraged to permit eye and tumor position verification for image-guided radiotherapy delivery.
    - Volumetric planning in 3 dimensions (with or without CT and/or MRI) is encouraged to maximize radiation delivery to tumor and minimize radiation delivery to organs and tissues at risk of injury from radiation.

Photon Stereotactic Radiosurgery (SRS)

- Treatment Information
  - SRS is the least often used form of definitive radiotherapy for the treatment of primary or recurrent intraocular tumors.[14,15]
  - Few prospective studies have assessed the efficacy and safety of radiosurgery.[16,17]
  - Tumor localization, fiducial marker use, and planning for SRS are generally consistent with particle beam therapy approaches.
- Treatment Dosing Information
  - Using fractionated SRS: 45–70 Gy in 2–5 fractions should be prescribed.
  - Using single-fraction SRS: 18–45 Gy in 1 fraction should be prescribed.

Fractionated Photon Radiotherapy

- Treatment Information
  - Fractionated photon radiotherapy is a preferred option as an adjuvant to surgery for orbital involvement.
    - Adjuvant radiotherapy can be used in patients at risk for local recurrence (margin-positive enucleation or exenteration) or regional recurrence (resected regional metastases).
- Adjuvant RT Dosing
  - A dose of 20–30 Gy in 5 fractions should be prescribed to the clinical target volume at risk for recurrence[18,19] using intensity-modulated RT (IMRT) with image guidance.

[b] The prospective trial showing no difference in local control for 50 CGyE and 70 CGyE in 5 fractions was for tumors <15 mm in diameter and <5 mm in height and near the optic disc or macula (within 4 disc diameters of either structure) (Gragoudas ES, Lane AM, Regan S, et al. A randomized controlled trial of varying radiation doses in the treatment of choroidal melanoma. Arch Ophthalmol 2000;118:773-778).

Note: All recommendations are category 2A unless otherwise indicated.

References

Version 1.2026, 02/10/26 © 2026 National Comprehensive Cancer Network® (NCCN®), All rights reserved. NCCN Guidelines® and this illustration may not be reproduced in any form without the express written permission of NCCN.

PLEASE NOTE that use of this NCCN Content is governed by the End-User License Agreement, and you MAY NOT distribute this Content or use it with any artificial intelligence model or tool.
Printed by Galya Basol Kochav on 2/13/2026 11:27:31 AM. Copyright © 2026 National Comprehensive Cancer Network, Inc. All Rights Reserved.

PRINCIPLES OF RADIATION THERAPY

METASTASIS DIRECTED RADIOTHERAPY

Ablative Radiotherapy for Limited Metastases

- Stereotactic ablative radiation therapy of oligometastases uses doses of 16–24 Gy/1 fraction or 24–60 Gy/2–8 fractions and should be prescribed to the appropriate target volume using appropriate stereotactic body RT (SBRT) techniques with image guidance.[20-23]
- Selective internal RT for patients with liver metastases using yttrium-90 has been reported in retrospective studies and in one prospective study.[24,25]
  - Further study is required to determine the appropriate patients for and risks and benefits of this approach.

Palliative Radiotherapy for Symptomatic Metastases

- For symptom palliation, photon beam radiotherapy can be used for treatment of distant metastases at risk for causing symptoms or for palliation of symptomatic distant metastases using doses of 8–30 Gy in 1–10 fractions should be prescribed to the appropriate target volume[26] using appropriate 3D or IMRT techniques with or without image guidance.

References

Note: All recommendations are category 2A unless otherwise indicated.

Version 1.2026, 02/10/26 © 2026 National Comprehensive Cancer Network® (NCCN®), All rights reserved. NCCN Guidelines® and this illustration may not be reproduced in any form without the express written permission of NCCN.

PLEASE NOTE that use of this NCCN Content is governed by the End-User License Agreement, and you MAY NOT distribute this Content or use it with any artificial intelligence model or tool.
Printed by Galya Basol Kochav on 2/13/2026 11:27:31 AM. Copyright © 2026 National Comprehensive Cancer Network, Inc. All Rights Reserved.

PRINCIPLES OF RADIATION THERAPY
REFERENCES

[1] Abrams MJ, Gagne NL, Melhus CS, Mignano JE. Brachytherapy vs. external beam radiotherapy for choroidal melanoma: Survival and patterns-of-care analyses. Brachytherapy 2016;15:216-223.
[2] Collaborative Ocular Melanoma Study Group. The COMS randomized trial of iodine 125 brachytherapy for choroidal melanoma: V. Twelve-year mortality rates and prognostic factors: COMS report No. 28. Arch Ophthalmol 2006;124:1684-1693.
[3] American Brachytherapy Society - Ophthalmic Oncology Task Force. The American Brachytherapy Society consensus guidelines for plaque brachytherapy of uveal melanoma and retinoblastoma. Brachytherapy 2014;13:1-14.
[4] Almony A, Breit S, Zhao H, et al. Tilting of radioactive plaques after initial accurate placement for treatment of uveal melanoma. Arch Ophthalmol 2008;126:65-70.
[5] Rivard MJ, Chiu-Tsao ST, Finger PT, et al. Comparison of dose calculation methods for brachytherapy of intraocular tumors. Med Phys 2011;38:306-316.
[6] Kheir WJ, Stinnett SS, Meltsner, et al. Preliminary results of uveal melanoma treated with iodine-125 plaques: Analysis of disease control and visual outcomes with 63 Gy to the target volume. Adv Radiat Oncol 2022;7:100869.
[7] Echegaray JJ, Bechrakis NE, Singh N, et al. Iodine-125 brachytherapy for uveal melanoma: A systematic review of radiation dose. Ocul Oncol Pathol 2017;3:193-198.
[8] Mishra KK, Quivey JM, Daftari IK, et al. Long-term results of the UCSF-LBNL randomized trial: Charged particle with helium ion versus iodine-125 plaque therapy for choroidal and ciliary body melanoma. Int J Radiat Oncol Biol Phys 2015;92:376-383.
[9] Hrbacek J, Mishra KK, Kacperek A, et al. Practice patterns analysis of ocular proton therapy centers: The International OPTIC Survey. Int J Radiat Oncol Biol Phys 2016;95:336-343.
[10] Lu JE, Welch RJ, Mishra KK, et al. Ultrasonography and transillumination for uveal melanoma localisation in proton beam treatment planning. Eye (Lond) 2019;33:1904-1910.
[11] Hartsell WF, Kapur R, Hartsell SO, et al. Feasibility of proton beam therapy for ocular melanoma using a novel 3D treatment planning technique. Int J Radiat Oncol Biol Phys 2016;95:353-359.
[12] Gragoudas ES, Lane AM, Regan S, et al. A randomized controlled trial of varying radiation doses in the treatment of choroidal melanoma. Arch Ophthalmol 2000;118:773-778.
[13] Tsuji H, Ishikawa H, Yanagi T, et al. Carbon-ion radiotherapy for locally advanced or unfavorably located choroidal melanoma: a phase I/II dose-escalation study. Int J Radiat Oncol Biol Phys 2007;67:857-862.
[14] Muller K, Naus N, Nowak PJ, et al. Fractionated stereotactic radiotherapy for uveal melanoma, late clinical results. Radiother Oncol 2012;102:219-224.
[15] Dunavoelgyi R, Georg D, Zehetmayer M, et al. Dose-response of critical structures in the posterior eye segment to hypofractioned stereotactic photon radiotherapy of choroidal melanoma. Radiother Oncol 2013;108:348-353.
[16] Muller K, Nowak PJ, de Pan C, et al. Effectiveness of fractionated stereotactic radiotherapy for uveal melanoma. Int J Radiat Oncol Biol Phys 2005;63:116-122.
[17] Zehetmayer M, Kitz K, Menapace R, et al. Local tumor control and morbidity after one to three fractions of stereotactic external beam irradiation for uveal melanoma. Radiother Oncol 2000;55:135-144.
[18] The Collaborative Ocular Melanoma Study (COMS) randomized trial of pre-enucleation radiation of large choroidal melanoma III: local complications and observations following enucleation COMS report no. 11. Am J Ophthalmol 1998;126:362-372.
[19] Ang KK, Peters LJ, Weber RS, et al. Postoperative radiotherapy for cutaneous melanoma of the head and neck region. Int J Radiat Oncol Biol Phys 1994;30:795-798.
[20] Curti B, Crittenden M, Seung SK, et al. Randomized phase II study of stereotactic body radiotherapy and interleukin-2 versus interleukin-2 in patients with metastatic melanoma. J Immunother Cancer 2020;8:e000773.
[21] Palma DA, Olsen R, Harrow S, et al. Stereotactic ablative radiotherapy for the comprehensive treatment of oligometastatic cancers: Long-term results of the SABR-COMET phase II randomized trial. J Clin Oncol 2020;38:2830-2838.
[22] Palma DA, Olsen R, Harrow S, et al. Stereotactic ablative radiotherapy for the comprehensive treatment of oligometastatic cancers: Long-term results of the SABR-COMET phase II randomized trial. Lancet 2019;393:2051-2058.
[23] Chalkidou A, MacMillan T, Grzeda MT, et al. Stereotactic ablative body radiotherapy in patients with oligometastatic cancers: a prospective, registry-based, single-arm, observational, evaluation study. Lancet Oncol 2021;22:98-106.
[24] Jia Z, Jiang G, Zhu C, et al. A systematic review of yttrium-90 radioembolization for unresectable liver metastases of melanoma. Eur J Radiol 2017;92:111-115.
[25] Gonsalves CF, Eschelman DJ, Adamo RD, et al. A prospective phase II trial of radioembolization for treatment of uveal melanoma hepatic metastasis. Radiology 2019;293:223-231.
[26] Huguenin PU, Kieser S, Glanzmann C, et al. Radiotherapy for metastatic carcinomas of the kidney or melanomas: an analysis using palliative end points. Int J Radiat Oncol Biol Phys 1998;41:401-405.

Note: All recommendations are category 2A unless otherwise indicated.

Version 1.2026, 02/10/26 © 2026 National Comprehensive Cancer Network® (NCCN®), All rights reserved. NCCN Guidelines® and this illustration may not be reproduced in any form without the express written permission of NCCN.

PLEASE NOTE that use of this NCCN Content is governed by the End-User License Agreement, and you MAY NOT distribute this Content or use it with any artificial intelligence model or tool.
Printed by Galya Basol Kochav on 2/13/2026 11:27:31 AM. Copyright © 2026 National Comprehensive Cancer Network, Inc. All Rights Reserved.

American Joint Committee on Cancer (AJCC)
Definitions of TNM for Choroidal and Ciliary Melanoma (8th ed., 2017)
***Table 1.* Definitions for T, N, M**
Choroidal and Ciliary Body Melanomas

T	**Primary Tumor**
TX	Primary tumor cannot be assessed
T0	No evidence of primary tumor
T1	Tumor size category 1
T1a	Tumor size category 1 without ciliary body involvement and extraocular extension
T1b	Tumor size category 1 with ciliary body involvement
T1c	Tumor size category 1 without ciliary body involvement but with extraocular extension ≤5 mm in largest diameter
T1d	Tumor size category 1 with ciliary body involvement and extraocular extension ≤5 mm in largest diameter
T2	Tumor size category 2
T2a	Tumor size category 2 without ciliary body involvement and extraocular extension
T2b	Tumor size category 2 with ciliary body involvement
T2c	Tumor size category 2 without ciliary body involvement but with extraocular extension ≤5 mm in largest diameter
T2d	Tumor size category 2 with ciliary body involvement and extraocular extension ≤5 mm in largest diameter
T3	Tumor size category 3
T3a	Tumor size category 3 without ciliary body involvement and extraocular extension
T3b	Tumor size category 3 with ciliary body involvement
T3c	Tumor size category 3 without ciliary body involvement but with extraocular extension ≤5 mm in largest diameter
T3d	Tumor size category 3 with ciliary body involvement and extraocular extension ≤5 mm in largest diameter
T4	Tumor size category 4
T4a	Tumor size category 4 without ciliary body involvement and extraocular extension
T4b	Tumor size category 4 with ciliary body involvement
T4c	Tumor size category 4 without ciliary body involvement but with extraocular extension ≤5 mm in largest diameter
T4d	Tumor size category 4 with ciliary body involvement and extraocular extension ≤5 mm in largest diameter
T4e	Any tumor size category with extraocular extension >5 mm in largest diameter

Notes

1. Primary ciliary body and choroidal melanomas are classified according to the four tumor size categories defined in Figure 1. (ST-3)
2. In clinical practice, the largest tumor basal diameter may be estimated in optic disc diameters (DD; average: 1 DD = 1.5 mm), and tumor thickness may be estimated in diopters (average: 2.5 diopters = 1 mm). Ultrasonography and fundus photography are used to provide more accurate measurements.
3. When histopathologic measurements are recorded after fixation, tumor diameter and thickness may be underestimated because of tissue shrinkage.

Used with permission of the American College of Surgeons, Chicago, Illinois. The original source for this information is the AJCC Cancer Staging Manual, Eighth Edition (2017) published by Springer International Publishing.

Continued

Version 1.2026, 02/10/26 © 2026 National Comprehensive Cancer Network® (NCCN®), All rights reserved. NCCN Guidelines® and this illustration may not be reproduced in any form without the express written permission of NCCN.

PLEASE NOTE that use of this NCCN Content is governed by the End-User License Agreement, and you MAY NOT distribute this Content or use it with any artificial intelligence model or tool.
Printed by Galya Basol Kochav on 2/13/2026 11:27:31 AM. Copyright © 2026 National Comprehensive Cancer Network, Inc. All Rights Reserved.

American Joint Committee on Cancer (AJCC)
Definitions of TNM for Choroidal and Ciliary Melanoma (8th ed., 2017)
***Table 1.* Definitions for T, N, M (continued)**

N	**Regional Lymph Nodes**
NX	Regional lymph nodes cannot be assessed
N0	No regional lymph node involvement
N1	Regional lymph node metastases or discrete tumor deposits in the orbit
N1a	Metastasis in one or more regional lymph node(s)
N1b	No regional lymph nodes are positive, but there are discrete tumor deposits in the orbit that are not contiguous to the eye (choroidal and ciliary body).

M	**Distant Metastasis**
M0	No distant metastasis by clinical classification
M1	Distant metastasis
M1a	Largest diameter of the largest metastasis ≤3.0 cm
M1b	Largest diameter of the largest metastasis 3.1–8.0 cm
M1c	Largest diameter of the largest metastasis ≥8.1 cm

G	**Histologic Grade**
GX	Grade cannot be assessed
G1	Spindle cell melanoma (>90% spindle cells)
G2	Mixed cell melanoma (>10% epithelioid cells and <90% spindle cells)
G3	Epithelioid cell melanoma (>90% epithelioid cells)

Note: Because of the lack of universal agreement regarding which proportion of epithelioid cells classifies a tumor as mixed or epithelioid, some ophthalmic pathologists currently combine grades 2 and 3 (non-spindle, ie, epithelioid cells detected) and contrast them with grade 1 (spindle, ie, no epithelioid cells detected).

***Table 2.* AJCC Prognostic Stage Groups**

	T	N	M
Stage I	T1a	N0	M0
Stage IIA	T1b-d	N0	M0
	T2a	N0	M0
Stage IIB	T2b	N0	M0
	T3a	N0	M0
Stage IIIA	T2c-d	N0	M0
	T3b-c	N0	M0
	T4a	N0	M0
Stage IIIB	T3d	N0	M0
	T4b-c	N0	M0
Stage IIIC	T4d-e	N0	M0
Stage IV	Any T	N1	M0
	Any T	Any N	M1a-c

Used with permission of the American College of Surgeons, Chicago, Illinois. The original source for this information is the AJCC Cancer Staging Manual, Eighth Edition (2017) published by Springer International Publishing.

Version 1.2026, 02/10/26 © 2026 National Comprehensive Cancer Network® (NCCN®), All rights reserved. NCCN Guidelines® and this illustration may not be reproduced in any form without the express written permission of NCCN.

PLEASE NOTE that use of this NCCN Content is governed by the End-User License Agreement, and you MAY NOT distribute this Content or use it with any artificial intelligence model or tool.
Printed by Galya Basol Kochav on 2/13/2026 11:27:31 AM. Copyright © 2026 National Comprehensive Cancer Network, Inc. All Rights Reserved.

***Figure 1*: Classification of Ciliary Body and Choroid Uveal Melanoma Based on Thickness and Diameter**

Thickness (mm)	≤3.0	3.1–6.0	6.1–9.0	9.1–12.0	12.1–15.0	15.1–18.0	>18.0
>15.0					4	4	4
12.1–15.0				3	3	4	4
9.1–12.0		3	3	3	3	3	4
6.1–9.0	2	2	2	2	3	3	4
3.1–6.0	1	1	1	2	2	3	4
≤3.0	1	1	1	1	2	2	4

Largest basal diameter (mm)

Used with permission of the American College of Surgeons, Chicago, Illinois. The original source for this information is the AJCC Cancer Staging Manual, Eighth Edition (2017) published by Springer International Publishing.

Version 1.2026, 02/10/26 © 2026 National Comprehensive Cancer Network® (NCCN®), All rights reserved. NCCN Guidelines® and this illustration may not be reproduced in any form without the express written permission of NCCN.

PLEASE NOTE that use of this NCCN Content is governed by the End-User License Agreement, and you MAY NOT distribute this Content or use it with any artificial intelligence model or tool.
Printed by Galya Basol Kochav on 2/13/2026 11:27:31 AM. Copyright © 2026 National Comprehensive Cancer Network, Inc. All Rights Reserved.

ABBREVIATIONS

CGyE	cobalt Gray equivalent
COMS	Collaborative Ocular Melanoma Study
CNS	central nervous system
FDG	fluorodeoxyglucose
FNA	fine-needle aspiration
GEP	gene expression profiling
H&P	history and physical
IMRT	intensity-modulated radiation therapy
LDH	lactate dehydrogenase
LFT	liver function test
OS	overall survival
PD-1	programmed cell death protein 1
PFS	progression-free survival
SBRT	stereotactic body radiation therapy
SRS	stereotactic radiosurgery

Version 1.2026, 02/10/26 © 2026 National Comprehensive Cancer Network® (NCCN®), All rights reserved. NCCN Guidelines® and this illustration may not be reproduced in any form without the express written permission of NCCN.

PLEASE NOTE that use of this NCCN Content is governed by the End-User License Agreement, and you MAY NOT distribute this Content or use it with any artificial intelligence model or tool.
Printed by Galya Basol Kochav on 2/13/2026 11:27:31 AM. Copyright © 2026 National Comprehensive Cancer Network, Inc. All Rights Reserved.

NCCN Categories of Evidence and Consensus	
Category 1	Based upon high-level evidence (≥1 randomized phase 3 trials or high-quality, robust meta-analyses), there is uniform NCCN consensus (≥85% support of the Panel) that the intervention is appropriate.
Category 2A	Based upon lower-level evidence, there is uniform NCCN consensus (≥85% support of the Panel) that the intervention is appropriate.
Category 2B	Based upon lower-level evidence, there is NCCN consensus (≥50%, but <85% support of the Panel) that the intervention is appropriate.
Category 3	Based upon any level of evidence, there is major NCCN disagreement that the intervention is appropriate.

All recommendations are category 2A unless otherwise indicated.

NCCN Categories of Preference	
Preferred	Interventions that are based on superior efficacy, safety, and evidence; and, when appropriate, affordability.
Other recommended	Other interventions that may be somewhat less efficacious, more toxic, or based on less mature data; or significantly less affordable for similar outcomes.
Useful in certain circumstances	Other interventions that may be used for selected patient populations (defined with recommendation).

All recommendations are considered appropriate.

PLEASE NOTE that use of this NCCN Content is governed by the End-User License Agreement, and you MAY NOT distribute this Content or use it with any artificial intelligence model or tool.
Printed by Galya Basol Kochav on 2/13/2026 11:27:31 AM. Copyright © 2026 National Comprehensive Cancer Network, Inc. All Rights Reserved.

Discussion

This discussion corresponds to the NCCN Guidelines for Melanoma: Uveal. Last updated: November 6, 2025.

Table of Contents

Overview MS-2
Guidelines Update Methodology MS-2
Literature Search Criteria MS-2
Sensitive/Inclusive Language Usage MS-3
Risk Factors for Uveal Melanoma MS-3
- Choroidal Nevi MS-3
- Ocular/Oculodermal Melanocytosis MS-4
- Familial Uveal Melanoma MS-4
- Other Potential Risk Factors MS-4
- The Relationship Between Uveal and Cutaneous Melanoma MS-4

Diagnosis and Workup MS-5
- Characteristics, Detection, and Differential Diagnosis MS-5
- Initial Workup of Suspicious Pigmented Uveal Lesion MS-5
- Imaging Methods MS-6
- Features to Record MS-9
- Biopsy MS-10
- Observation for Uncertain Diagnosis in Patients with Low Risk MS-11
- Further Workup Prior to Treatment MS-12

Treatment for Localized Primary Uveal Melanoma MS-12
- Enucleation MS-13
- Radiation Therapy MS-14
- Other Ablative Techniques MS-16
- Treatment for Extraocular Extension MS-17

Follow-up MS-18
- Follow-up for the Treated Eye MS-18
- Risk in Contralateral (Fellow) Eye MS-18
- Patterns of Metastases MS-19
- Risk Factors for Metastasis MS-19
- Follow-up for Distant Metastasis MS-20
- Risk of Developing Secondary Cancers During Follow-up MS-21

Management of Ocular Recurrence MS-22
- Workup for Ocular Recurrence MS-22
- Treatment for Ocular Recurrence MS-22

Management of Metastatic Disease MS-23
- Workup for Distant Metastatic Disease MS-24
- Treatment for Distant Metastatic Disease MS-24
- Liver-Directed Therapy MS-25
- External Beam Radiation for Uveal Melanoma Metastases MS-27
- Systemic Therapy for Distant Metastatic Disease MS-27

References MS-31

Discussion update in progress

Version 1.2026 © 2026 National Comprehensive Cancer Network© (NCCN©), All rights reserved. NCCN Guidelines® and this illustration may not be reproduced in any form without the express written permission of NCCN.

PLEASE NOTE that use of this NCCN Content is governed by the End-User License Agreement, and you MAY NOT distribute this Content or use it with any artificial intelligence model or tool.
Printed by Galya Basol Kochav on 2/13/2026 11:27:31 AM. Copyright © 2026 National Comprehensive Cancer Network, Inc. All Rights Reserved.

Overview

Uveal melanoma is the most common type of primary intraocular malignancy in adults, with an incidence of approximately 5 people per million annually in the United States.[1] Uveal melanomas can arise anywhere in the uveal tract, with <85% arising in the choroid, and the remainder arising in the iris or ciliary body.[2] Additionally, the distribution of uveal melanoma by sex, race, and geography differs from that of cutaneous melanoma.

Most uveal melanomas are localized at first presentation, and <3% present with metastases.[3] Risk of metastasis varies by stage at presentation, with 5-year risk of metastasis ranging from 3% to 5% for stage I to ≥44% for stage III.[4,5] Large population-based analyses have reported disease-specific survival (DSS) between 70% to 81% at 5 years. For those with early-stage disease (stage I–II), 5-year DSS is ≥85%.[4,6,7] For those with distant metastatic disease, most studies report an estimated 5-year survival of <20%,[4,6,8-11] which has not improved over the past few decades.[12]

These NCCN Clinical Practice Guidelines in Oncology (NCCN Guidelines®) include recommendations for management of melanomas arising in the choroid or ciliary body. Recommendations for iris melanomas are not included in these guidelines, because iris melanomas are rare (3%–5% of uveal melanomas),[5,13] have a low rate of systemic metastasis (~5% at 5 years compared with 15%–20% for ciliary body or choroidal melanomas),[5,14-18] have a better prognosis than other types of uveal melanoma,[18,19] have a different AJCC staging system,[20] and have a different molecular signature.[21-25]

Treatments for iris melanoma may differ from other types of uveal melanoma due to these factors, as well as anatomic considerations, ease of resection,[26,27] and the negative effects of radiation to the iris.[28-31] Moreover, patients with iris melanomas were excluded from many of the large randomized trials that inform treatment recommendations for uveal melanomas.[32-34]

The patterns of presentation and prognosis for uveal melanoma are different from cutaneous melanoma. The AJCC Staging Manual 8th Edition includes separate staging systems for cutaneous, uveal, and conjunctival melanoma.[20] The staging system for uveal melanoma is further subdivided into separate T-staging for iris versus choroidal or ciliary body melanoma.[20]

Cutaneous, uveal, and conjunctival melanomas also have different molecular signatures. Whereas *BRAF*, *NRAS*, *KIT*, and *TERT* promoter mutations are extremely rare in uveal melanoma,[23,35,36] they are more common in conjunctival and cutaneous melanomas.[37-42] Molecular markers common in uveal melanomas that may have prognostic significance are not often found in conjunctival or cutaneous melanoma. These include chromosomal abnormalities (particularly chromosomes 3 and 8)[43-46] and mutations in *GNAQ* or *GNA11* (>80% of uveal melanomas),[23,47,48] *BAP1*,[49,50] *SF3B1*, and *EIFAX*.[25,51,52] The NCCN Panel recommends referral to centers with expertise in the management of uveal melanoma upon clinical presentation.

Guidelines Update Methodology

The complete details of the Development and Update of the NCCN Guidelines are available at www.NCCN.org.

Literature Search Criteria

Prior to the update of the NCCN Guidelines® for Melanoma: Uveal, an electronic search of the PubMed database was performed to obtain key literature in uveal melanoma published since the previous Guidelines update, using the following search terms: uveal, uvea, choroid, choroidal,

Discussion update in progress

Version 1.2026 © 2026 National Comprehensive Cancer Network© (NCCN©), All rights reserved. NCCN Guidelines® and this illustration may not be reproduced in any form without the express written permission of NCCN.

PLEASE NOTE that use of this NCCN Content is governed by the End-User License Agreement, and you MAY NOT distribute this Content or use it with any artificial intelligence model or tool.
Printed by Galya Basol Kochav on 2/13/2026 11:27:31 AM. Copyright © 2026 National Comprehensive Cancer Network, Inc. All Rights Reserved.

or ciliary in conjunction with the term melanoma. The PubMed database was chosen because it remains the most widely used resource for medical literature and indexes peer-reviewed biomedical literature.[53]

The search results were narrowed by selecting studies in humans published in English. Results were confined to the following article types: Clinical Trial, Phase 2; Clinical Trial, Phase 3; Clinical Trial, Phase 4; Guideline; Meta-Analysis; Practice Guideline; Randomized Controlled Trial; Systematic Reviews; and Validation Studies. The data from key PubMed articles as well as articles from additional sources deemed as relevant to these guidelines as discussed by the Panel during the Guidelines update have been included in this version of the Discussion section. Recommendations for which high-level evidence is lacking are based on the Panel's review of lower-level evidence and expert opinion.

Sensitive/Inclusive Language Usage

NCCN Guidelines strive to use language that advances the goals of equity, inclusion, and representation.[54] NCCN Guidelines endeavor to use language that is person-first; not stigmatizing; anti-racist, anti-classist, anti-misogynist, anti-ageist, anti-ableist, and anti-weight-biased; and inclusive of individuals of all sexual orientations and gender identities. NCCN Guidelines incorporate non-gendered language, instead focusing on organ-specific recommendations. This language is both more accurate and more inclusive and can help fully address the needs of individuals of all sexual orientations and gender identities. NCCN Guidelines will continue to use the terms men, women, female, and male when citing statistics, recommendations, or data from organizations or sources that do not use inclusive terms. Most studies do not report how sex and gender data are collected and use these terms interchangeably or inconsistently. If sources do not differentiate gender from sex assigned at birth or organs present, the information is presumed to predominantly represent cisgender individuals. NCCN encourages researchers to collect more specific data in future studies and organizations to use more inclusive and accurate language in their future analyses.

Risk Factors for Uveal Melanoma

Choroidal Nevi

Large population-based studies have found that choroidal nevi occur in 1.9% to 6.5% of the population, depending on the population studied.[55-57] Choroidal nevi can transform into choroidal melanoma, and one study reported that of uveal melanomas diagnosed, 8% arose from a previously documented nevus.[58,59] Others have argued that the fraction of uveal melanomas that arise from nevi may in fact be much higher, as many patients diagnosed with uveal melanoma have not had an ophthalmologic exam for many years.[60] The rate of transformation from nevi to uveal melanoma is an issue of much debate.[61-63] Besides, choroidal nevi can be difficult to distinguish from choroidal melanoma, as there is evidence that many small lesions presumed to be nevi may actually be melanoma.[64,65] Due to uncertainty regarding uveal melanoma diagnosis, especially for small tumors, studies have looked at the likelihood of lesion growth in patients with untreated melanocytic choroidal lesions.[61,66-73] Documented growth has been correlated with progression to uveal melanoma and risk of metastasis,[66] even though some growing choroidal nevi do not undergo malignant transformation.[61,69,74,75] It is important to note that for patients with small lesions presumed to be nevi or indeterminate, who are observed and treated upon evidence of transformation, the risk of metastasis and death is low.[66,71] However, these risks increase with increasing baseline tumor size.[70] Patient characteristics that increase the likelihood of choroidal nevi growth or choroidal/ocular melanoma include Birt-Hogg-Dubé syndrome,[76,77] myotonic dystrophy,[78-80] and immunocompromise.[81,82]

Discussion update in progress

Version 1.2026 © 2026 National Comprehensive Cancer Network© (NCCN©), All rights reserved. NCCN Guidelines® and this illustration may not be reproduced in any form without the express written permission of NCCN.

PLEASE NOTE that use of this NCCN Content is governed by the End-User License Agreement, and you MAY NOT distribute this Content or use it with any artificial intelligence model or tool.
Printed by Galya Basol Kochav on 2/13/2026 11:27:31 AM. Copyright © 2026 National Comprehensive Cancer Network, Inc. All Rights Reserved.

Ocular/Oculodermal Melanocytosis

The rate of ocular/oculodermal melanocytosis, which causes hyperpigmentation of the episclera, uvea, and skin, is much higher in patients with uveal melanoma than in the general population.[83-88]

Familial Uveal Melanoma

Although only a small percentage of patients with uveal melanoma have at least one family member with uveal melanoma,[89,90] this rate is higher than would be expected, given the very low incidence of uveal melanoma in the population as a whole.[91,92] Having a family member with uveal melanoma is therefore considered a risk factor for melanoma. Studies of families with more than one member with uveal melanoma have shown that there are several family cancer syndromes associated with increased risk of uveal melanoma.

Certain *BAP1* germline mutations have been associated with predisposition for uveal melanoma, malignant mesothelioma, cutaneous melanoma, renal cell carcinoma, and cholangiocarcinoma.[93-99] Some families with *BAP1* tumor predisposition syndrome also tend to have atypical Spitz tumors, which are benign/precursor melanocytic lesions with distinctive clinical and pathologic features.[95,100,101] In individuals with germline *BAP1* mutations associated with this syndrome, the risk of uveal melanoma is high, uveal melanoma tends to develop at a younger age, primary lesions tend to be larger and involve the ciliary body, and the disease has a more aggressive course.[50,97,100,102-104] Some individuals with this syndrome develop more than one type of primary cancer and there is a high likelihood of *BAP1*-associated cancers in first- or second-degree relatives.[94,102,103,105]

Mutations in *PALB2* have been associated with increased risk for developing breast, ovarian, and pancreatic cancer. Pathogenic variants leading to biallelic inactivation of *PALB2* were identified in tumors of two patients with familial uveal melanoma.[106] This finding from a retrospective case series might warrant further investigation into *PALB2* as a uveal melanoma susceptibility gene.

MBD4 deleterious mutations have been identified in uveal melanoma tumors at increased incidence compared with the general population and associated with high tumor mutational burden.[107,108] Questions remain whether *MBD4* germline variants or somatic loss predisposes individuals to uveal melanoma.[109] How *MBD4* inactivation might affect immunotherapy response is also worth further investigation.[107,110]

Other Potential Risk Factors

Patient characteristics associated with increased uveal melanoma risk are lighter skin and eye color and propensity to sunburn.[111-114] Occupational history of welding and a dose-response relationship with job duration have also been associated with increased uveal melanoma risk.[115]

In conclusion, the NCCN Panel recommends evaluation for evidence of hereditary syndrome and referral for genetic counseling and testing in case of: early age of diagnosis (<30 years of age), history of other primary cancers in the patient, or family or personal history of other cancers known to be associated with a hereditary syndrome.

The Relationship Between Uveal and Cutaneous Melanoma

Clinic-based studies (N < 250) evaluating the likelihood of finding concurrent cutaneous melanoma in patients with ocular melanoma suggest a relationship between these two cancers.[116-119] Most large population-based studies reveal no relationship between preexisting cutaneous melanoma and the subsequent development of uveal melanoma.[120-124] However, one SEER-based study revealed a potential relationship between these two cancers.[125] For patients who present with uveal melanoma as their first primary cancer, some population-based studies have shown increased risk of subsequent cutaneous

Discussion update in progress

Version 1.2026 © 2026 National Comprehensive Cancer Network© (NCCN©), All rights reserved. NCCN Guidelines® and this illustration may not be reproduced in any form without the express written permission of NCCN.

PLEASE NOTE that use of this NCCN Content is governed by the End-User License Agreement, and you MAY NOT distribute this Content or use it with any artificial intelligence model or tool.
Printed by Galya Basol Kochav on 2/13/2026 11:27:31 AM. Copyright © 2026 National Comprehensive Cancer Network, Inc. All Rights Reserved.

melanoma,[121-123,126] and others have not found the risk to be significantly higher than in the general population.[124,127] Currently the NCCN Panel does not consider cutaneous melanoma to be a risk factor for uveal melanoma, and patients with cutaneous melanoma do not need more frequent ocular screening than the general population.

Diagnosis and Workup

Characteristics, Detection, and Differential Diagnosis

Uveal melanoma typically presents as a pigmented lesion.[128] One study of 8033 eyes with uveal melanoma found that the lesion was pigmented in 55%, nonpigmented in 15%, and 30% had a mixture of pigmented and nonpigmented areas.[129] Uveal melanoma most often presents as a dome-shaped tumor (75%), but approximately 20% of uveal melanomas present with a mushroom shape due to the rupture of Bruch's membrane and growth into the sub-retinal space.[129] A small number of tumors present as diffuse, flat, plateau-shaped or having a multinodular tapioca appearance.[129] Subretinal fluid is present in the majority of patients (75%).[129]

The majority of uveal melanomas are symptomatic at presentation, but studies have reported 13% to 30% of patients were asymptomatic at diagnosis (and are discovered by routine eye exam).[58,128,130-132] The most common symptom is blurred vision; other common symptoms include visual field defect/loss, photopsia, irritation and pain, metamorphopsia, floaters, redness, and pressure. Although current imaging techniques provide high accuracy of diagnosis of medium to large uveal melanomas,[133,134] real-world studies have reported relatively high rates of delay in diagnosis and treatment (23%–37%) due to the inability to detect these lesions in the initial ophthalmologic exam.[58,131,132,135] Surprisingly, the rate of delayed diagnosis is also high in symptomatic patients.[58,131] Furthermore, conditions such as choroidal nevus, congenital hypertrophy of the retinal pigment epithelium (RPE), and choroidal hemangioma can be mistaken for uveal melanoma.[136-139] Therefore, full dilation of the pupil and meticulous examination of the fundus in any patient presenting with symptoms is critical.[60]

Ciliary body melanoma can be difficult to detect, as it is often hidden behind the iris, and symptoms often do not develop until the tumor is large.[28,131,140,141] Ciliary body melanoma can cause lens tilting or displacement, cataract development, and elevated intraocular pressure, and is often associated with dilated episcleral "sentinel" vessels.[140-142] Ciliary body melanomas usually present with a dome shape, but occasionally have a circumferential ring shape.[140,141,143]

As described above, several risk factors have been identified that may increase the risk of uveal melanoma. When a pigmented lesion on the ciliary body or choroid is discovered, these factors should be evaluated, as they may inform the index of suspicion.

It is also important to rule out metastasis to the uvea from other cancers—either known cancers based on patient history or occult primary cancer. Among patients with metastases to the eye or orbit, the most common primary cancer diagnosis is breast cancer, followed by lung cancer, which together account for over half of the patients.[144-146] The remainder of uveal metastases can arise from cancers of the kidney, gastrointestinal (GI) tract, skin, prostate, thyroid, pancreas, and others.[145,146]

Initial Workup of Suspicious Pigmented Uveal Lesion

Upon discovery of a suspicious pigmented lesion in the ciliary body or choroid, clinical evaluation should include a complete history and physical (H&P), including personal or family history of prior or current cancers (outside the eye), as this may help determine whether the lesion is primary uveal cancer or a metastasis from another primary cancer. A wide variety of imaging and clinical exam techniques have been tested for their utility in diagnosis and characterization of uveal melanoma. Predominantly, the

Discussion update in progress

Version 1.2026 © 2026 National Comprehensive Cancer Network© (NCCN©), All rights reserved. NCCN Guidelines® and this illustration may not be reproduced in any form without the express written permission of NCCN.

PLEASE NOTE that use of this NCCN Content is governed by the End-User License Agreement, and you MAY NOT distribute this Content or use it with any artificial intelligence model or tool.
Printed by Galya Basol Kochav on 2/13/2026 11:27:31 AM. Copyright © 2026 National Comprehensive Cancer Network, Inc. All Rights Reserved.

diagnosis of uveal melanoma and characterization for treatment planning (or follow-up) can be achieved based on comprehensive exam of the front and back of the eye including biomicroscopy and dilated fundus exam (indirect ophthalmoscopy).[60,141,147,148] In some instances, additional imaging may be needed to confirm diagnosis or better characterize the tumor for treatment planning (or monitoring). Additional imaging options that may be useful include color fundus photography, conventional ocular ultrasound (US), autofluorescence of the ocular fundus, optical coherence tomography (OCT), retinal fluorescein angiography of the ocular fundus, transillumination, and MRI with or without IV contrast as clinically indicated.

Features that are essential to measure and document as part of workup include visual acuity (VA), location and size of the tumor (ie, diameter, thickness), distance from the tumor to the disc and to the fovea, ciliary body involvement, and subretinal fluid and orange pigment, if present.

Biopsy may be considered if needed to confirm diagnosis or for prognostic analysis for risk stratification. Biopsy of the primary tumor may provide prognostic information that can help inform frequency of follow-up and may be needed for clinical trial eligibility. Biopsy is usually not necessary for initial diagnosis of uveal melanoma and selection of first-line treatment but may be useful in patients with uncertainty regarding diagnosis, such as for amelanotic tumors or retinal detachment. If biopsy is performed, molecular/chromosomal testing for prognostication is preferred over cytology alone. The risks/benefits of biopsy for prognostic analysis should be carefully considered and discussed.

Imaging Methods

Comprehensive Eye Exam (biomicroscopy)

Meticulous analysis of the fundus after full pupil dilation will allow detection of most choroidal melanomas,[60] and can be used to record many of the relevant features needed for diagnosis and treatment planning. Whereas ciliary body melanomas can be difficult to detect by this method, fundus exam with good indentation can sometimes help.[28]

Color Fundus Photography

Color fundus photography is useful for documenting the clinical features of lesions, with the advantage of giving the most identical appearance to clinical examination.[149] Color fundus photography can be used to evaluate the borders of the lesion, and thereby record the location and shape; calculate lesion basal diameter and area; and be used to detect orange pigment, drusen, and halo.[150,151] Areas of orange pigment seen by color fundus photography have been shown to correlate with those seen by fundus autofluorescence. It is important to note that color fundus photography alone is not sufficient for a differential diagnosis, and diagnostic accuracy based on color fundus photography has wide interobserver variation.[152]

Ocular Ultrasound

In addition to comprehensive clinical ophthalmologic exam and color fundus photography, US of the eye (ocular echography) is one of the most useful tools for diagnosis of choroidal melanomas.[147,153] In experienced hands, US in combination with complete ophthalmologic clinical exam results in a high level of diagnostic accuracy (>99%) for studies of medium to large uveal melanomas.[134,154] Melanomas tend to exhibit low internal reflectivity as well as an intrinsic acoustic quiet zone on US,[153] features that distinguish them from a variety of other intraocular conditions. US is particularly useful when a mass cannot be visually inspected due to

Discussion update in progress

Version 1.2026 © 2026 National Comprehensive Cancer Network© (NCCN©), All rights reserved. NCCN Guidelines® and this illustration may not be reproduced in any form without the express written permission of NCCN.

PLEASE NOTE that use of this NCCN Content is governed by the End-User License Agreement, and you MAY NOT distribute this Content or use it with any artificial intelligence model or tool.
Printed by Galya Basol Kochav on 2/13/2026 11:27:31 AM. Copyright © 2026 National Comprehensive Cancer Network, Inc. All Rights Reserved.

opacity or pathology of structures in the anterior portion of the eye such as corneal scars, cataract, or blood in the vitreous.[147]

US can help in the detection of ciliary body melanomas that may be missed by fundoscopy.[155] US is particularly useful for determining the thickness of the tumor, and has been shown to have a high level of accuracy compared with tumor height measurements based on histopathology of enucleated specimens.[142,156,157] By facilitating measurement of tumor dimensions, US is useful for detecting lesion growth.[140,158] US can also be used to detect extraocular extension, which shows hyporeflectivity on US.[60,147] There are two modes of US to evaluate the eye, A-mode and B-mode. Uveal melanomas show low reflectivity on both A-scan and B-scan ultrasonography, although other features differ.[60]

A-Scan Ultrasonography

Uveal melanomas typically show low to medium internal reflectivity on A-mode US, which further decreases toward the sclera.[60,140,147,158,159] Other A-scan US hallmarks specific to uveal melanoma are: 1) a regular internal structure with similar height of the inner tumor spikes or regular decrease in height (positive angle kappa sign); 2) solid consistency with no aftermovement of tumor spikes; and 3) echographic sign of vascularization with a fast, spontaneous, continuous, flickering vertical motion of single tumor spikes. In contrast, choroidal metastases from other types of cancer typically show an irregular structure on A-mode US, hemangiomas show much higher reflectivity, and nevi and melanocytomas show higher reflectivity and more irregular structures than malignant melanoma.[147,158,159] Fresh choroidal hemorrhages may have similar structure and reflectivity as melanomas, but will show aftermovement following small eye movements.[159]

B-Scan Ultrasound

On B-scan US, posterior uveal melanomas appear as hyperchromic mass with lower reflectivity than the surrounding choroid, thus giving an acoustically hollow appearance.[28,147] Posterior uveal melanomas, particularly the larger ones, show choroidal excavation and orbital shadowing on B-scan US.[134,158] These features help confirm clinical diagnosis, and are distinct from hemangiomas or metastases to the eye, which typically show high reflectivity.[140,160] However, some other lesions that may show choroidal excavation include: hemangiomas, long-standing nevi, and choroidal metastases.[154] B-scan US is used for obtaining tumor dimensions, extent, and shape, and is useful for characterizing larger ciliary body tumors.[28,158] Extraocular extension can be observed by B-scan US as areas of hyporeflectivity compared to normal orbital tissue.[60,140]

Autofluorescence of Ocular Fundus

Fundus autofluorescence has been proposed as a method to help in the diagnosis and characterization of uveal melanomas.[150,161] Choroidal melanoma generally shows slight intrinsic hyperautofluorescence and the brightness increases with tumor pigmentation and disrupted RPE.[162,163] Orange pigment is the most highly autofluorescent uveal melanoma feature.[162,164,165] Drusen can also be detected by autofluorescence, and have increased, normal, or decreased autofluorescence.[165] Fibrous metaplasia also shows elevated autofluorescence.[164] Autofluorescence can be used to distinguish orange pigment from drusen in both pigmented and non-pigmented tumors.[166] Unlike uveal melanoma and choroidal nevi, melanocytomas show hypofluorescence.[167] Comparative studies have shown that the autofluorescence pattern often matches that of orange pigment and hyperpigmentation seen by color fundus photography.[151] Based on comparative studies, it is not clear that fundus autofluorescence increases the detection rate of orange pigment relative to standard ophthalmologic exam.[166]

Discussion update in progress

Version 1.2026 © 2026 National Comprehensive Cancer Network© (NCCN©), All rights reserved. NCCN Guidelines® and this illustration may not be reproduced in any form without the express written permission of NCCN.

PLEASE NOTE that use of this NCCN Content is governed by the End-User License Agreement, and you MAY NOT distribute this Content or use it with any artificial intelligence model or tool.
Printed by Galya Basol Kochav on 2/13/2026 11:27:31 AM. Copyright © 2026 National Comprehensive Cancer Network, Inc. All Rights Reserved.

Optical Coherence Tomography

OCT is another imaging method proposed for assisting diagnosis of uveal melanoma.[147,168] Spectral domain OCT (SD-OCT) allows the detailed evaluation of the retina and RPE, changes which are more common in choroidal melanoma versus choroidal nevi.[161] OCT can help identify overlying retinal detachment or edema, even before clinically apparent.[161] OCT can detect subretinal and intraretinal fluid, subretinal lipofuscin, retinal epithelium atrophy and degeneration, shaggy photoreceptors, and structural loss of photoreceptors in the neurosensory retina.[161,169,170] These features are more likely in choroidal melanoma than in choroidal nevi, although some features are more useful than others for differential diagnosis, especially in small lesions.[169,171,172] Results differ across comparative studies regarding whether OCT is more sensitive than standard ophthalmologic exam plus US for detecting subretinal fluid.[166,173]

In OCT, the structure of the lesion differed between choroidal nevi, melanomas, hemangiomas, and metastases.[170] Optical density ratio based on OCT can also be used to distinguish choroidal melanomas from choroidal metastases.[174] Enhanced depth imaging OCT (EDI-OCT) is particularly useful for detecting small lesions, and distinguishing small nevi from small choroidal melanoma.[28] OCT angiography (OCT-A) can be used to distinguish choroidal nevi from choroidal melanoma based on margin characteristics (well-delimited vs. imprecise), reflectivity of choroid capillary vasculature (hyper vs. hypo), and characteristics of lesion vasculature.[168,175] Compared to US biomicroscopy, OCT provides better resolution of the anterior segment anatomy and margin, while the former provides better overall visualization and resolution of the posterior margin.[176]

Retinal Fluorescein Angiography

Retinal fluorescein angiography can be used to characterize lesion vasculature, which can aid in diagnosis because choroidal melanomas may have intrinsic tumor circulation, sometimes called “double circulation,” in addition to normal choroidal vasculature.[140,177] Observation of the tumor vasculature is helpful in distinguishing melanomas from choroidal nevi, hemorrhagic degeneration, or choroidal melanoma.[60,147,178] After treatment with brachytherapy, fluorescein angiography is also useful for detection of complications such as radiation retinopathy.[147]

Transillumination

Transillumination has been tested as a method for detecting and measuring uveal melanomas that may be difficult to detect or fully characterize by other techniques. Examples include large ciliary body melanomas, or tumors obscured by cataracts.[60,179] Compared with tumor dimension measurements based on histology of enucleated eyes, transillumination tends to overestimate both the thickness and diameter of tumors, and is prone to shadowing artifacts.[180] Therefore, it is only used if other methods have proven inadequate.

MRI

MRI is generally not needed for diagnosis and workup, but occasionally is necessary with features that may make other imaging methods difficult, such as secondary vitreous hemorrhage, extensive retinal detachment, or cataract.[147,181] MRI with or without IV contrast may be useful in determining whether cataract is caused by an underlying ciliary body melanoma, and can help distinguish uveal melanomas from hemangiomas.[147] Uveal melanomas usually have high signal intensity in T1-weighted MRI images and low signal intensity in T2-weighted images.[60,140] Although similar signal pattern can be caused by hemorrhage or necrosis, hemangiomas typically have hyperintense signal on T-weighted images and T2-weighted images are isointense with the vitreous.[60,147] MRI is useful for detecting and characterizing extraocular extension, and is also used for radiation therapy (RT) planning.[60,182-185]

Discussion update in progress

Version 1.2026 © 2026 National Comprehensive Cancer Network© (NCCN©), All rights reserved. NCCN Guidelines® and this illustration may not be reproduced in any form without the express written permission of NCCN.

PLEASE NOTE that use of this NCCN Content is governed by the End-User License Agreement, and you MAY NOT distribute this Content or use it with any artificial intelligence model or tool.
Printed by Galya Basol Kochav on 2/13/2026 11:27:31 AM. Copyright © 2026 National Comprehensive Cancer Network, Inc. All Rights Reserved.

Features to Record

Visual Acuity

It is important to measure VA during workup, as many uveal melanomas can disturb vision, and changes in VA can be an indication of progression, response to treatment, or a side effect of certain treatments. VA or changes in VA can contribute to the differential diagnosis, as benign nevi rarely cause visual impairment,[56] whereas malignancy does.[63,72] In patients with uveal melanoma, VA in the affected eye tends to be worse than in the fellow eye.[32] A baseline measure of VA is also important to determine effects of uveal melanoma treatment. RT can cause a decline in VA, although the effects are highly variable.[186] Larger tumor size and tumor location near the optic disc are associated with greater loss of VA and higher rates of local complications.[187]

Size

Although size alone does not determine diagnosis, it can contribute to differential diagnosis, as uveal melanomas are generally larger than choroidal nevi, and size (thickness >2 mm, tumor diameter >5 mm) is predictive of growth in melanocytic lesions.[69,72] For lesions thought to be nevi, or small lesions with uncertain diagnosis, accurate measurements of size are important for monitoring for growth, as rapid growth is a sign of likely malignancy.[66] Baseline tumor size is needed to determine the T stage of the tumor, which helps determine the prognostic risk category used to inform post-treatment surveillance. Tumor size is also important for selecting and planning treatment. For brachytherapy, selection of the appropriate size plaque is important to ensure that the lesion is fully covered, and alternative or additional treatment options need to be considered for tumors that exceed the size of the largest commercially available plaque. Selection of alternative treatment options (eg, particle beam RT, stereotactic radiosurgery [SRS], enucleation) should also depend on tumor size. Accurate measurements of size and shape of the tumor are also needed for monitoring response or progression after treatment.

Location, Distance from Disc and Fovea, Ciliary Body Involvement

Lesion location is one of the features that can contribute to diagnosis. Proximity to the optic disc is considered a diagnostic feature of uveal melanomas, as it is correlated with likelihood of growth in melanocytic choroidal lesions.[69] Lesion location, including distance from disc and fovea, and ciliary body involvement, can impact imaging results, such as the ability to detect certain diagnostic features and accurately discern borders for measurement of tumor size. In some instances, color fundus photography, US, and complete clinical exam may not be sufficient for detection and/or characterization of ciliary body involvement; this is a feature that may require additional imaging approaches.[148] Lesion location can help explain visual symptoms and may impact the efficacy and safety of specific treatments. Ciliary body involvement is one of the elements that determines the T stage of the tumor and prognostic risk category used to inform post-treatment follow-up surveillance.

Subretinal Fluid

Subretinal fluid is a feature that supports the diagnosis of uveal melanoma, as it is rare in benign choroidal nevi, and has been shown to develop during growth of choroidal nevi and transformation to melanoma.[62,188] The presence of subretinal fluid has been shown to be predictive of growth in choroidal nevi or small indeterminate melanocytic lesions.[62] One study of a large number of uveal melanomas (N = 8033) reported that subretinal fluid was present in 75% of patients.[129] However, ocular metastases from other primary cancers (eg, breast, lung) can also give rise to subretinal fluid.[145]

Orange Pigment

Orange pigment, also called lipofuscin, can be present in benign choroidal nevi; however, it has been shown to develop during nevi growth and

Discussion update in progress

Version 1.2026 © 2026 National Comprehensive Cancer Network© (NCCN©), All rights reserved. NCCN Guidelines® and this illustration may not be reproduced in any form without the express written permission of NCCN.

PLEASE NOTE that use of this NCCN Content is governed by the End-User License Agreement, and you MAY NOT distribute this Content or use it with any artificial intelligence model or tool.
Printed by Galya Basol Kochav on 2/13/2026 11:27:31 AM. Copyright © 2026 National Comprehensive Cancer Network, Inc. All Rights Reserved.

transformation to uveal melanoma.[62,188] In nevi or indeterminate small lesions, the presence of orange pigment is predictive of future growth and increases the likelihood of a future uveal melanoma diagnosis.[62,72]

Biopsy

The use of biopsy as part of workup for uveal melanoma is an issue of some debate. Potential benefits of biopsy during workup are: 1) cytologic/histologic confirmation of diagnosis; 2) potential for molecular analysis that may impact eligibility for current or future clinical trials; and 3) potential for molecular analyses that may provide more accurate prognostic assessment for risk of metastasis, which may inform future follow-up surveillance. Potential harms of biopsy of the primary tumor include: 1) risk of complications from the procedure that damage the eye; 2) risk of tumor seeding leading to local or distant recurrence; and 3) risk of inadequate sampling resulting in misdiagnoses or inaccurate or inconclusive molecular testing results. The likelihood of these potential benefits and harms is debated and may vary across practitioners.

There are a wide variety of biopsy techniques that have been tested and are sometimes used for choroidal or ciliary body tumors. Some involve a transscleral (direct) approach while others use a transvitreal (indirect) approach.[189] Tumor location is a major determinant of which approach is likely to be successful and safe. Techniques for biopsying choroidal and ciliary body tumors such as fine-needle aspiration biopsy (FNAB), vitrectomy-assisted biopsy, and incisional biopsy have been used to assist with diagnosis and/or prognostication in primary uveal melanomas. Any of these biopsy procedures can result in intraocular complications/morbidities (eg, hemorrhage, decrease in VA, retinal detachment, retinal perforation, hypotony, endophthalmitis) which if severe may require secondary procedures or other interventions for management.[190-195] Longitudinal population-based studies have shown that biopsy does not impact all-cause mortality or disease-specific death (DSD) in patients with uveal melanoma.[196-198]

Fine-Needle Aspiration Biopsy

FNAB is the simplest, most inexpensive, and most commonly used method for biopsy of choroid or ciliary body tumors presumed to be melanoma.[199-201] FNAB can be done via a transvitreal or transscleral approach depending on the location of the tumor. The transvitreal approach is generally easier due to better intraoperative illumination and visualization options.

The disadvantage to FNAB is that multiple passes may be needed to obtain enough material for cytologic and molecular genetic analysis.[190,202] The yield from FNAB varies across studies. Some studies suggest that transvitreal (vs. transscleral) approach is associated with improved FNAB yield, but some studies have disagreed.[190,203,204] It has also been postulated that FNAB yield is higher for larger and thicker tumors,[203,205] but a study showed that high yields can be obtained even in thin tumors (<3.5-mm thick), with both the transscleral and transvitreal approach.[190] FNAB can help distinguish between uveal melanoma and borderline or benign melanocytic nevus, even among small lesions, and between a primary uveal melanoma versus metastasis from another cancer, another type of primary ocular tumor, a melanocytoma, or RPE proliferation.[64,206,207] Concerns about FNAB causing tumor seeding have been raised based on findings of melanoma cells left in the needle track, and some have suggested procedure adjustments for reducing the likelihood of tumor cell seeding by FNAB.[201,208,209] A few case reports found local recurrences at FNAB entry sites.[210,211] However, multiple follow-up studies with large patient populations have revealed no local recurrences after FNAB.[190,212-214] Additionally, one case series found no increased risk of metastasis among untreated patients who had post-biopsy evidence of melanoma cell

Discussion update in progress

Version 1.2026 © 2026 National Comprehensive Cancer Network© (NCCN©), All rights reserved. NCCN Guidelines® and this illustration may not be reproduced in any form without the express written permission of NCCN.

PLEASE NOTE that use of this NCCN Content is governed by the End-User License Agreement, and you MAY NOT distribute this Content or use it with any artificial intelligence model or tool.
Printed by Galya Basol Kochav on 2/13/2026 11:27:31 AM. Copyright © 2026 National Comprehensive Cancer Network, Inc. All Rights Reserved.

dissemination inside the eye.[208] FNAB is therefore generally thought to be safe and to have low risk of seeding.

Other Biopsy Techniques

Other biopsy techniques that have been tested in large uveal melanoma populations use tools from vitrectomy systems to access tumors via a transvitreal/transretinal approach and to extract tumor tissue using the vitreous cutter and aspiration through the canula. These procedures do not necessarily include a vitrectomy. There are a variety of procedures that fall into this category used in clinical practices in both the United States and Europe.[201] These techniques have been used successfully on anterior, posterior, equatorial, and peripapillary lesions.[192,193,215,216] They generally result in larger sample sizes than FNAB, although like FNAB multiple passes may be necessary. For this reason, it has been suggested that these methods may be useful in patients with tumors that are too small or inaccessible for FNAB, or for tumors where FNAB has been unsuccessful. One study reported that for choroidal melanomas with thickness of ≤2.0 mm, sufficient sample for prognostic evaluation was obtained in 100% of patients.[215] Reported yields from these procedures range from 89% to 99% for diagnosis of choroidal lesions, and 97% to 100% for prognostic testing on uveal melanomas.[189,192,193Bechrakis, 2002 #8974,215] Studies have shown that these biopsy techniques can be used to diagnose tumors that are unclassifiable based on standard noninvasive diagnostic techniques, and can differentiate uveal melanoma from benign nevus, metastases from other cancers, vasoproliferative tumor, hemorrhage, gliosis, and scleritis.[216,217]

Generally, these approaches are less broadly used than FNAB, are more expensive, and require additional expertise. Like FNAB, hemorrhage is the most common complication with these biopsy procedures, is normally localized, and usually resolves without intervention.[193,215] Since these techniques are more invasive, however, retinal detachment and severe hemorrhage are more common, and more patients require intervention for management.[192,193,201] Decrease in VA due to these procedures is not uncommon.

Like FNAB, studies have published evidence that these procedures may leave tumor cells along the access pathways. Nevertheless, most studies, including those with large patient samples, have not observed local recurrence during follow-up.[193,217] There are a few case reports of local recurrences at biopsy entry sites.[210,216,218]

Incisional biopsy techniques are more invasive than vitrectomy system-assisted biopsies, and likewise yield more material, but also are more likely to lead to complications.[194,195,219] These methods have been used for uveal melanomas that are particularly hard to diagnose. Excisional biopsy, using either transscleral resection or endoresection, was also explored as an option for both biopsy and primary treatment.[220]

Observation for Uncertain Diagnosis in Patients with Low Risk

Findings from the clinical workup should be used to determine initial management. Observation may be appropriate for patients with uncertain diagnosis, especially for small tumors, and/or fewer than three risk factors for lesion growth. Studies have found that for patients with small choroidal lesions presumed to be nevi or indeterminate, deferring treatment until evidence of growth or features of malignancy develop (eg, orange pigment, subretinal fluid, symptoms) is associated with a very low risk of metastasis, and even lower risk of death from uveal melanoma.[66,70,71] For patients whose disease meets the criteria for observation, regular follow-up is recommended to periodically re-evaluate for growth or features of malignancy. Follow-up tests should include the same tests recommended for initial workup and diagnosis that would help clarify if there is progression and determine the natural history of the indeterminate lesion. Initially, these patients should be re-evaluated every 2 to 6 months to

Discussion update in progress

Version 1.2026 © 2026 National Comprehensive Cancer Network© (NCCN©), All rights reserved. NCCN Guidelines® and this illustration may not be reproduced in any form without the express written permission of NCCN.

PLEASE NOTE that use of this NCCN Content is governed by the End-User License Agreement, and you MAY NOT distribute this Content or use it with any artificial intelligence model or tool.
Printed by Galya Basol Kochav on 2/13/2026 11:27:31 AM. Copyright © 2026 National Comprehensive Cancer Network, Inc. All Rights Reserved.

determine rate of growth (if any) and to monitor for other changes indicative of malignancy. Close follow-up for 5 years is recommended to firmly establish whether or not there is any growth or progression; some lesions that initially seem stable may suddenly begin to grow and transform. The frequency of re-evaluation should depend on the index of suspicion, patient age, and medical frailty. For example, the presence of one to two risk factors for growth, or evidence of changes would increase suspicion. If the size and features of a lesion appear static after 5 years of follow-up, the patient can be followed annually thereafter. Lesions that demonstrate growth or develop additional risk factors for growth (>3 total) per clinical diagnostic criteria should be managed as uveal melanoma, even if diagnosis is still uncertain.

Further Workup Prior to Treatment

Further workup prior to treatment may be needed for some patients to aid in treatment selection and planning. For example, for tumors that are large, close to the optic nerve, or have suspected extraocular extension, MRI should be performed, if not previously done, to confirm extraocular extension, determine whether RT or enucleation is needed, and for RT planning.[140,183-185] MRI should be performed with and without contrast unless contraindicated. Ciliary body involvement or extraocular extension should be assessed and documented, as these features may impact the feasibility, safety, and efficacy of certain treatment options. Biopsy is typically performed before the tumor is irradiated and can often be performed at the time of primary treatment depending on the procedure modality. There is some evidence to suggest that RT may alter molecular genetic features of the tumors, reducing the accuracy of prognostication based on samples taken after RT treatment.[221]

Baseline imaging to screen for systemic disease is also recommended prior to treatment. For patients who have small, low-risk tumors, deferring extraocular baseline imaging until after primary treatment can be considered. The most frequent site of metastasis is the liver, and other sides include the lungs, skin/soft tissue, and bones.[10] At minimum, all patients should have contrast-enhanced MR or US of the liver, with modality preference determined by expertise at the treating institution. Additional imaging modalities may include chest/abdomen/pelvis CT with contrast. However, screening should limit radiation exposure whenever possible.

Treatment for Localized Primary Uveal Melanoma

Most uveal melanomas are localized at first presentation, and <3% of patients present with metastases.[3] Local treatment for primary uveal melanoma is effective in preventing local recurrence in >85% of patients,[222] yet the rate of metastasis within 20 years after treatment is approximately 20% to 70% for patients who present with localized uveal melanoma, depending on tumor stage/size at diagnosis.[4,5,14,223] Whereas surgical approaches historically are the mainstay of treatment for localized cutaneous melanoma, the field has moved away from using surgery in all patients.[224,225] Different modalities, primarily various forms of RT, have been found to be just as safe and effective for those with limited disease, and can preserve the affected eye. [226-231] Some surgical approaches are still used in patients with extensive local disease, but most patients with localized primary uveal melanoma are treated with some form of RT.[224,232] There are a number of other ablative techniques that are occasionally used for localized primary melanoma, including laser therapy, cryotherapy, and photodynamic therapy.

Selection among these techniques is guided by many patient-specific factors, including the size and location of the tumor, presence of extraocular extension, visual potential, patient age, and preference. The recommended treatment options are largely based on data from choroidal melanomas. For small ciliary body and iris tumors (<3 clock hours), surgical excision may be considered.

Discussion update in progress

Version 1.2026 © 2026 National Comprehensive Cancer Network© (NCCN©), All rights reserved. NCCN Guidelines® and this illustration may not be reproduced in any form without the express written permission of NCCN.

PLEASE NOTE that use of this NCCN Content is governed by the End-User License Agreement, and you MAY NOT distribute this Content or use it with any artificial intelligence model or tool.
Printed by Galya Basol Kochav on 2/13/2026 11:27:31 AM. Copyright © 2026 National Comprehensive Cancer Network, Inc. All Rights Reserved.

For thin tumors (<2.5 mm) with largest diameter ranging from 5 to 19 mm, the recommended primary treatment options are regular ophthalmologic follow-up in select patients, plaque brachytherapy, particle beam RT, or other options in highly select patients. For these highly select patients who are not good candidates for brachytherapy or particle beam RT, other options to consider include laser treatment or enucleation per patient preference. For patients whose disease meets criteria for observation, regular ophthalmologic follow-up is recommended to re-evaluate for growth. Brachytherapy with scleral patch graft and proton beam radiation are recommended for patients with limited extraocular extension (see *Principles of Radiation Therapy* in the algorithm).

For tumors with largest diameter ≤19 mm and thickness 2.5 mm to 10 mm, brachytherapy and particle beam RT are also options. If there is concern that adequate response was not achieved from initial RT, additional treatment with resection, laser ablation, transpupillary thermotherapy (TTT), or cryotherapy can be considered. Although there is a trend toward avoiding enucleation, it is recommended for patients with neovascular glaucoma, tumor replacing >50% of globe, or blind, painful eyes. Enucleation should also be considered for patients with extensive extraocular extension. Pathologic evaluation should follow the uveal melanoma synoptic report recommendations by the College of American Pathologists (available at: http://documents.cap.org/protocols/cp-uveal-melanoma-17protocol-4000.pdf).

Given the limitations in the size and RT penetrance of commercially available brachytherapy plaques (diameter ≤23 mm), this method is not recommended for tumors that are too large in diameter (>19 mm; any thickness), too thick (>10 mm; any diameter), or have optic nerve involvement and thickness (>8 mm; any diameter). RT options for such tumors include particle beam RT and SRS. The choice between these two RT modalities usually depends on which modality is available at the treating institution. In the rare scenario that the institution has both SRS and particle beam facilities, some practitioners would opt for particle beam because there are more data supporting its efficacy (see *Principles of Radiation Therapy* in the algorithm). Enucleation is recommended for patients with extensive extraocular extension, neovascular glaucoma, tumor replacing >50% of globe, or blind, painful eyes.

Enucleation

Enucleation is historically the most widely used treatment for uveal melanoma. Results from the Collaborative Ocular Melanoma Study (COMS) prospective randomized trial suggest that enucleation is associated with a very low risk of local recurrence (~1%),[233-235] notably lower than the rate of local recurrence reported for retrospective studies in patients treated with primary local resection.[236-239] The few patients whose disease developed local recurrences after enucleation all had distant metastases before the local recurrence developed.[233] Retrospective studies reported similar findings, suggesting that development of distant metastasis is due to micrometastasis that developed prior to enucleation.[235]

Postoperative complications include pain, hemorrhage, nausea/vomiting, cardiovascular or pulmonary problems, urinary retention, fever, and local surgical problems.[233] Enucleation procedures have been standardized; they involve complete removal of the eye and in most cases include insertion of an orbital implant.[140,240-242] Both porous and nonporous implants have been shown to result in similar outcomes, although there may be a higher incidence of ptosis with acrylic implants, and a greater need for ocularists' treatment (eg, topical antibiotics, polishing or refitting of prosthesis) with hydroxyapatite implants.[243]

Pre-enucleation RT is generally not used. Results from the COMS randomized trial in large tumors (height ≥2 mm and diameter ≥16 mm; or

Discussion update in progress

Version 1.2026 © 2026 National Comprehensive Cancer Network© (NCCN©), All rights reserved. NCCN Guidelines® and this illustration may not be reproduced in any form without the express written permission of NCCN.

PLEASE NOTE that use of this NCCN Content is governed by the End-User License Agreement, and you MAY NOT distribute this Content or use it with any artificial intelligence model or tool.
Printed by Galya Basol Kochav on 2/13/2026 11:27:31 AM. Copyright © 2026 National Comprehensive Cancer Network, Inc. All Rights Reserved.

height ≥10 mm and any diameter; or height ≥8 mm, any diameter, if proximal tumor border <2 mm to optic disc) showed that pre-enucleation RT had no impact on survival compared with enucleation alone,[233,244,245] confirming results of prior retrospective studies.[246] The 5- and 10-year DSD reported in this trial were 28% and 40%, respectively, for patients treated with enucleation.[244]

In the COMS randomized trial in small-to-medium choroidal melanomas (2.5–10.0 mm in apical height [2.5–8.0 mm if peripapillary] and ≤16 mm in maximum basal diameter, no extrascleral extension ≥2.0 mm thick), survival outcomes for enucleation were similar to those with iodine-125 brachytherapy.[226,247] The 5- and 10-year DSD reported in this trial were 11% and 17%, respectively, for patients treated with enucleation, compared with 10% and 18%, respectively, for the brachytherapy arm.[226] Even after adjustment for age and maximum basal diameter, there were no treatment-dependent differences in all-cause mortality or mortality with confirmed melanoma metastasis at time of death.[226] One prospective and several retrospective studies also found that survival was similar after enucleation versus cobalt plaque brachytherapy,[227,248-251] or a mix of brachytherapy plaque types,[252] versus proton beam RT,[228] or versus SRS.[230,231,253] Relative to RT, enucleation is associated with worse effects on certain visual functions and physical and functional well-being. However, some studies have found that overall quality of life was similar between the two treatment modalities.[254,255]

Radiation Therapy

Brachytherapy and charged particle RT are considered appropriate for primary therapy for most patients with uveal melanoma, whereas photon RT and SRT are less often used as primary treatment for uveal melanoma. SRS is sometimes used for large primary tumors, and photon RT is generally only used as an adjuvant to surgery.

Plaque Brachytherapy

Plaque brachytherapy is a commonly used form of definitive RT for the primary tumor.[256] Prospective studies in patients with small choroidal tumors found that iodine-125 brachytherapy resulted in a high rate of tumor regression (98%) and 98% rate of globe conservation.[257,258] DSD at 5 years was 3.9%.[258] As discussed previously, results from the COMS trial showed that long-term outcomes were not significantly different with plaque brachytherapy versus enucleation for patients with small- to medium-sized choroidal melanomas.[226,247] Local recurrence after brachytherapy, although rare, is more common than with enucleation. Prospective studies have reported local recurrence rates ranging from 0% to ~20%, with most studies reporting rates of <10%.[256,259-265] A systematic review (N >3000) found that the weighted mean rate of local recurrence after brachytherapy was 9.45%.[266] Whereas some studies report median time to local recurrence between 2 and 4 years, most also show curves that never really plateau, with recurrences developing as late as 12 years or more after treatment.[33,259,261,264,265,267,268]

More serious postoperative complications commonly reported for brachytherapy include radiation retinopathy, optic neuropathy, papillopathy, maculopathy, neovascular glaucoma, retinal detachment, and various types of hemorrhages and vascular abnormalities.[258,261,265,269] The 5-year cumulative rate of enucleation as a result of brachytherapy complications or growth of tumor was approximately 12% in prospective trials, most often due to progression on treatment during the first 3 years after brachytherapy, and to eye pain beyond 3 years after treatment.[259] Loss of VA and cataracts are common long-term complications of brachytherapy, with approximately half of patients having lost ≥6 lines of VA after 3 years of follow-up.[187]

Other studies have reported local recurrence rates ranging from 0% to 20% for patients treated with iodine-125, ruthenium-106, and palladium-

Discussion update in progress

Version 1.2026 © 2026 National Comprehensive Cancer Network© (NCCN©), All rights reserved. NCCN Guidelines® and this illustration may not be reproduced in any form without the express written permission of NCCN.

PLEASE NOTE that use of this NCCN Content is governed by the End-User License Agreement, and you MAY NOT distribute this Content or use it with any artificial intelligence model or tool.
Printed by Galya Basol Kochav on 2/13/2026 11:27:31 AM. Copyright © 2026 National Comprehensive Cancer Network, Inc. All Rights Reserved.

103 brachytherapy plaques.[263,264,270-273] It is important to note that late treatment progression (up to 12 years) after brachytherapy has been observed.[264] Several studies also found that survival was similar after enucleation versus cobalt plaque,[272] or a mix of brachytherapy plaque types.[249,250,252] A meta-analysis of studies testing Ru plaques reported a 5-year DSD of 6% for small and medium tumors (T1/T2), and 26% for large tumors (T3).[274] Palladium-103 brachytherapy plaques appear to perform similarly to iodine-125 plaques.[275]

When evaluating patients for brachytherapy, it is important to consider the entry criteria and treatment parameters used in the COMS trial. The COMS trial included only patients with tumors that were choroidal;[247] those with tumors contiguous with the optic disc were excluded, as were those with metastases from melanoma or another cancer (except nonmelanoma skin cancers).[226] Only 16% of patients had tumors <2.0 mm from the optic disc.[247]

Plaque Brachytherapy Dosing Considerations
Using iodine-125 COMS plaques, 85 Gy should be prescribed to the apex of the tumor at low dose-rate (≥0.6 Gy/h), as this was the dose used in the COMS study of medium-sized uveal melanomas, showing similar survival with brachytherapy versus enucleation.[226,247] Other studies using iodine-125 brachytherapy dosing similar to COMS have reported similarly high rates of local control,[264,276-278] and a retrospective study found that efficacy outcomes were similar to those in patients treated with SRT.[279] Studies using iodine-125 brachytherapy doses higher than in COMS also reported recurrence rates that compared favorably with other treatment modalities (eg, TTT, proton beam RT).[257,280] In contrast, studies using iodine-125 brachytherapy doses ≤80 Gy reported recurrence rates higher than with particle beam RT.[33,262,281-283] Whereas a few studies have associated a lower iodine-125 brachytherapy dose with local tumor recurrence and decreased systemic control,[284,285] others have found no such correlation.[286,287]

Another issue of debate is the relationship between brachytherapy dose and long-term complications. Several studies have found correlations between increasing iodine-125 dose and loss of VA, risk of RT-related complications (eg, cataract, optic neuropathy, glaucoma), and the need for secondary enucleation.[288-292] Results are mixed, however, and retrospective analyses did not always find significant correlations between dose and these negative outcomes.[290,293,294]

Studies testing a wide range of doses for brachytherapy plaques made of other radioisotopes, such as ruthenium-106, palladium-103, strontium-90, and cobalt-60, have reported mean/median dose to the apex between 80 and 130 Gy.[186,268,280,295-299] Although there is evidence to suggest that results differ between isotopes, the optimal dose has not been determined for any of these isotopes.[280,296] Results are inconsistent across retrospective studies that evaluated the impact of dose on local/distant recurrence rate, or the impact of dose on RT-related complications and VA loss.[186,295,300,301]

Particle Beam Radiation Therapy
Particle beam RT includes radiation with protons, carbon ions, or helium ions, and is a common form of definitive RT for the primary tumor.[302] DSS in patients with uveal melanoma treated with particle beam RT was similar or better than for plaque brachytherapy.[33,303] Compared with brachytherapy, particle beam RT was associated with higher rates of local control and similar or lower rates of enucleation during follow-up.[33,303] Specifically, local control for particle versus plaque treatment was 100% versus 84% at 5 years, and 98% versus 79% at 12 years, respectively (P = .0006). Enucleation rate was 11% versus 22% at 5 years, and 17% versus 37% at 12 years, respectively (P = .01).[33] Across studies, local recurrence rates with charged particle therapy ranged from 3% to 10%.[266,304] Tumor regression following particle beam RT can begin within 6

Discussion update in progress

Version 1.2026 © 2026 National Comprehensive Cancer Network© (NCCN©), All rights reserved. NCCN Guidelines® and this illustration may not be reproduced in any form without the express written permission of NCCN.

PLEASE NOTE that use of this NCCN Content is governed by the End-User License Agreement, and you MAY NOT distribute this Content or use it with any artificial intelligence model or tool.
Printed by Galya Basol Kochav on 2/13/2026 11:27:31 AM. Copyright © 2026 National Comprehensive Cancer Network, Inc. All Rights Reserved.

months of treatment, and tumor shrinkage may continue to occur throughout 5 years of follow-up.[304,305] As with brachytherapy, local recurrence after particle beam RT as treatment for primary localized uveal melanoma occurs over a long time range, as early as 2 months after treatment and as late as 12 years.[33,306-308] These studies have found that most local recurrences occurred in the first 4 to 5 years, with median time to recurrence of < 2 years. Multivariate analysis of a real-world database found that treatment with protons was associated with poorer overall survival (OS) compared with brachytherapy treatment (5-year OS 51% vs. 77%; P = .008).[309]

Decrease in VA and loss of vision, similar to brachytherapy, can occur with particle beam RT.[304,306,307,310] Commonly reported toxicities include vitreous hemorrhage, subretinal exudation in macula, posterior subcapsular opacity, radiation keratopathy, rubeosis/neovascular glaucoma, retinal detachment, radiation maculopathy, and papillopathy.

Stereotactic Radiation

Stereotactic RT (SRT) includes both single-fraction and hypofractionated stereotactic techniques, referred to collectively as SRS in these NCCN Guidelines. Compared with brachytherapy and particle beam RT, there are fewer prospective comparative study data on SRS for treatment of primary uveal melanoma. Studies using SRT as primary treatment for uveal melanoma have reported local recurrence rates ranging between 0% to 16%.[279,311-318] Following SRT of the primary tumor, many uveal melanomas showed a transient increase in tumor height, volume, or both.[319] Responses to SRT first began to appear 6 months after treatment, with progressive decreases in tumor height and volume continuing for at least 3 years.[316,319-322]

Available data suggest that SRS may be as effective as other RT modalities, albeit with a higher risk of complications. [279,293,311,323-327] One series that compared SRS with iodine-125 brachytherapy found that rates of tumor recurrence, distant metastasis, and secondary enucleation were similar across treatments.[279] Risk of cataract appeared similar across treatments, but SRS appeared to be associated with higher rates of neovascular glaucoma, radiation retinopathy, and radiation papillopathy.[279,324] Another study also reported similar rates of local control with brachytherapy versus SRS.[299] A comparison of ruthenium-106 brachytherapy versus SRS found a nonsignificant trend toward increased secondary glaucoma after SRS.[298] SRS versus proton beam RT reported similar rates of local control and eye retention across treatments, but higher rates of VA decline and vitreous hemorrhage with SRS.[311,318]

RT Toxicity (Ocular)

In order to avoid secondary enucleation, a variety of methods for preventing or managing RT-associated complications have been tested in prospective studies. Toxicity management methods tested include panretinal photocoagulation for ocular ischemia,[328] transscleral local resection for exudative retinal detachment,[329] and intravitreal anti-vascular endothelial growth factor (VEGF) (eg, bevacizumab, ranibizumab, aflibercept) or intravitreal corticosteroids (eg, triamcinolone, dexamethasone) for treating optic neuropathy, macular radiation vasculopathy, or papillopathy or macular edema.[293,330-335] These intravitreal therapies have also been tested for prophylaxis.[336-338] The NCCN Guidelines for Melanoma: Uveal do not currently have recommendations for management of RT side effects.

Other Ablative Techniques

Laser photocoagulation has been used for treatment of primary or recurrent uveal melanomas, sometimes as monotherapy but more often as an adjunct to RT or surgery.[142,293,339-343] The sparse data available suggest that laser photocoagulation is associated with high rates of recurrence if used as the sole primary therapy,[339,341] but that when used as a supplement to brachytherapy can increase rate of tumor regression.[344]

Discussion update in progress

Version 1.2026 © 2026 National Comprehensive Cancer Network© (NCCN©), All rights reserved. NCCN Guidelines® and this illustration may not be reproduced in any form without the express written permission of NCCN.

PLEASE NOTE that use of this NCCN Content is governed by the End-User License Agreement, and you MAY NOT distribute this Content or use it with any artificial intelligence model or tool.
Printed by Galya Basol Kochav on 2/13/2026 11:27:31 AM. Copyright © 2026 National Comprehensive Cancer Network, Inc. All Rights Reserved.

TTT, also called diode laser hyperthermia, can be used to treat a large spot and has deep tissue penetration. TTT has been tested as the sole primary treatment for uveal melanoma tumors, but local recurrence rates varied widely across studies, with some reporting high rates of recurrence (>50%), even for small tumors.[257,345-347] TTT has also been tested as an adjunct therapy to RT to reduce the risk of local recurrence.[261,284,348] One prospective randomized trial found that TTT administered at 1, 6, and 12 months after proton RT reduced the likelihood of retinal detachment and lowered the secondary enucleation rate.[349] A retrospective study found that addition of TTT to brachytherapy improved rate of tumor regression, 5-year tumor recurrence rate, eye-globe preservation, and recurrence-free survival.[350] There was no impact on metastasis-free survival, OS, rate of complications, or visual outcomes.[350] However, two other studies showed that adding TTT to brachytherapy did not improve the rate of globe conservation, and was associated with greater loss of VA.[268,351] The larger of these studies (N = 449) also showed that rate of local recurrence, distant metastasis, and cause-specific death were not improved by TTT.[268]

Use of cryotherapy for treatment of primary or recurrent uveal melanomas, either alone or in conjunction with other therapies, has been previously described.[352-355] Retrospective reports and review articles suggest that this method is occasionally being used in clinical practice.[14,252,356]

Treatment for Extraocular Extension

Extraocular extension has been reported to be present in approximately 3% of patients at diagnosis of uveal melanoma, is more common among tumors with higher T stage (12% of T4 tumors), and is associated with poor prognosis.[7,129,223,357,358] Extraocular extension can be detected by preoperative imaging, or found or confirmed at the time of enucleation.[233,359] In the COMS trial of patients with large uveal melanomas, unexpected extrascleral extension was found in 2% of patients who underwent enucleation, despite extensive clinical and imaging workup.[233,245]

Sometimes the evidence of extraocular extension is microscopically positive or close margins after enucleation, without clinical, intraoperative, or radiographic evidence of gross residual disease to the orbit. In this case, the patient can be observed or RT to the orbit can be considered. Conversely, extraocular tumors may be visible intraoperatively or intraoperative findings suggest that there may be gross disease to the orbit. Biopsy of the extraocular tissue should be carried out, if possible, with consideration of one or more of the following options for local control: cryotherapy, orbital exenteration, or RT to the orbit.

For patients with extraocular extension and/or orbital invasion, orbital exenteration, the surgical removal of the globe and adjacent orbital contents, is recommended.[28,153,360] Retrospective studies of large databases suggest that exenteration is used in <1% of patients,[14] and among patients undergoing enucleation, 2.5% need orbital exteneration.[361] The value of orbital exenteration is disputed in the literature, largely based on low-quality data such as case reports and retrospective studies. Some studies support orbital exenteration because it provided superior outcomes compared with other (nonsurgical) approaches,[362] whereas others report poor outcomes after orbital exenteration, arguing that it may not be justified.[363,364]

A retrospective study (N = 202) found that in patients treated with enucleation, postoperative RT improved survival, particularly in young patients (age <30 years) and those with choroidal tumor height >3 mm.[361] Another small retrospective study reported a local recurrence rate of 6% in patients with extrascleral extension who were treated with enucleation followed by adjuvant external beam RT to the orbit.[365]

Discussion update in progress

Version 1.2026 © 2026 National Comprehensive Cancer Network© (NCCN©), All rights reserved. NCCN Guidelines® and this illustration may not be reproduced in any form without the express written permission of NCCN.

PLEASE NOTE that use of this NCCN Content is governed by the End-User License Agreement, and you MAY NOT distribute this Content or use it with any artificial intelligence model or tool.
Printed by Galya Basol Kochav on 2/13/2026 11:27:31 AM. Copyright © 2026 National Comprehensive Cancer Network, Inc. All Rights Reserved.

Follow-up

For patients whose primary uveal melanoma was treated with RT or surgery, the subsequent disease-free interval is highly variable, ranging from a few months to many years.[261,262,264,265,267,307,322] Uveal melanoma is characterized by early micrometastasis (often before treatment) followed by variable latency period before emergence of overt metastasis.[366] Local recurrence is rare, occurring in <10% of patients after treatment with the modalities recommended in these guidelines.[33,129,234,258, 1998 #7432,259Shields, 2002 #5740,262,266] Development of detectable distant metastatic disease is much more common than local recurrence, and happens in up to 70% of patients, depending on the stage and other risk factors at the time of diagnosis.[4,5,14,223]

Follow-up for the Treated Eye

At NCCN Member Institutions, standard follow-up in the affected eye includes imaging with color fundus photography and ultrasonography every 3 to 6 months for 3 to 5 years, then every 6 to 12 months thereafter, if stable. Serial orbital MRI may be used as clinically indicated. The frequency of follow-up should depend on the size and location (eg, juxtapapillary location, ciliary body involvement) of the tumor at presentation, as these factors impact the risk for recurrence. Radiation-related retinopathy and other treatment-related complications may occur at any time following treatment.

For patients treated with enucleation in the COMS trial, there were follow-up clinical and ophthalmologic exams at 1 to 2 weeks after surgery to assess healing status, and at 6 months, 12 months, and annually thereafter, in which the eye socket and eyelids were examined for possible recurrence or complications, and the fit of prosthesis checked.[245,247,367]

For patients treated with RT, follow-up exams typically included complete ophthalmologic exam of the treated eye, with indirect ophthalmoscopy, slit-lamp exam, tonometry, color fundus photography, A-scan and B-scan US, and measurement of VA and visual field. Many studies also included fluorescein angiography in follow-up exams, either at regular intervals or as needed, in addition to gonioscopy, OCT, or MRI.[187,257,259,268,316,322,367-371] For patients whose disease was treated with brachytherapy in the COMS study, follow-up included an exam within 6 weeks of surgery, at 6 months after treatment, then every 6 months for 5 years, and every 12 months thereafter.[247] Patients with suspected tumor growth had more frequent follow-up exams.

Risk in Contralateral (Fellow) Eye

All patients should receive follow-up for the affected eye. In patients with uveal melanoma, the contralateral eye is not at increased risk of uveal melanoma,[372] and should be followed with routine ophthalmologic care including routine eye protection for the remaining eye (eg, polycarbonate glasses).

In the COMS trials of patients with medium or large primary uveal melanoma tumors, prospective monitoring showed that <1% of patients developed disease in the contralateral eye during follow-up after primary treatment.[234,373,374] Moreover, for the majority of patients who did not develop disease in the contralateral eye, results from regular ophthalmologic exams showed that good VA was retained in their fellow eye throughout the 10 years of follow-up, regardless of the modality used to treat the primary lesion.[372] Analysis of 8165 patients with ocular melanoma in the SEER database found bilateral involvement in 0.1% of patients.[375] One retrospective study of 52 patients with bilateral uveal melanoma suggests prognosis is similar to that of patients with unilateral disease.[376] Rare instances of uveal melanoma metastasizing to the contralateral eye are described in case studies.[377-385]

Discussion update in progress

Version 1.2026 © 2026 National Comprehensive Cancer Network© (NCCN©), All rights reserved. NCCN Guidelines® and this illustration may not be reproduced in any form without the express written permission of NCCN.

PLEASE NOTE that use of this NCCN Content is governed by the End-User License Agreement, and you MAY NOT distribute this Content or use it with any artificial intelligence model or tool.
Printed by Galya Basol Kochav on 2/13/2026 11:27:31 AM. Copyright © 2026 National Comprehensive Cancer Network, Inc. All Rights Reserved.

Patterns of Metastases

Most uveal melanomas are localized at first presentation, and <3% of patients with T3 classified disease have detectable metastatic disease at the time of diagnosis.[386] Development of distant metastatic disease is much more common, occurring in 20% to 70% of patients within 20 years after treatment for primary uveal melanoma, depending on stage/size and genetic characteristics of the tumor at diagnosis.[4,5,14,34,45,223] Large retrospective studies (N > 7000) found that after long-term follow-up, 20% of patients with stage I disease at diagnosis developed metastasis, in contrast to ~70% for those with stage III disease.[4,223] Prospective studies have shown that the cumulative rate of development of distant metastatic disease steadily increases even after 6 to 20 years of follow-up.[258,316,374,387,388] In the COMS studies, the Kaplan-Meier estimates of 2-, 5-, and 10-year metastasis rates were 10%, 25%, and 34%.[374]

Sites of Metastasis

Uveal melanoma most often metastasizes to the liver (90% of the time).[389] Other common sites of metastasis, listed in order of decreasing prevalence, are lung, bone, skin/soft tissue, and lymph nodes.[10,310,374,390] In large prospective studies following patients after treatment for primary uveal melanoma, metastasis to the lung was observed in 20% to 30% of patients who developed distant metastatic disease, to the bone in 16% to 18%, to skin/soft tissue in 11% to 12%, and to lymph nodes in 10% to 11%.[234,373] Retrospective studies show similar trends.[10,391] Brain metastases were reported in 4% to 5% of patients who developed distant metastatic disease.[10,234,373] Most patients who develop metastatic disease ultimately have multiple sites involved; however, the first site is typically the liver. [8,10,11,234,384,392]

Risk Factors for Metastasis

Risk factors for metastasis include a variety of genetic markers as well as tumor size at presentation. The NCCN Guidelines list specific risk factors to be used for risk stratification to determine the frequency of surveillance imaging during follow-up. The NCCN Guidelines recommend using AJCC T stage for risk stratifying according to primary tumor size. T1 is considered low risk, T2 and T3 medium risk, and T4 high risk. For patients who had a biopsy of the primary tumor, certain molecular features have been shown to be prognostic for risk of distant spread and should be used for risk stratification. Gene expression profiling (GEP) as described by Onken et al[34] is recommended to determine whether the tumor is Class 1A (low risk), Class 1B (medium risk), or Class 2 (high risk) to inform frequency of follow-up.[393-395] It has been shown that Class 2 was associated with a 5-fold to 20-fold higher risk of metastasis than Class 1.[34,202,396-406] The following chromosomal abnormalities are also considered risk factors that should inform frequency of follow-up: disomy 3 (low risk), gain of chromosome 6p (low risk), monosomy 3 (high risk), and gain of chromosome 8q (high risk). Mutations in several genes have also been shown to be prognostic for distant metastasis and should be used for risk stratification: *EIF1AX* (low risk), *SF3B1* (medium risk), and *BAP1* (high risk). PRAME expression is also an indicator of risk to be used to inform frequency of follow-up and surveillance. Patients are considered low risk for distant metastasis with Class 1 PRAME (-) expression and medium risk with Class 1 PRAME (+).[407] Patients with Class 2 expression may be associated with shorter time to metastases. If biopsy was not performed, medium- or high-risk pathways should be followed, depending on whether any high-risk features are present.

Although the AJCC staging system is based on survival data from large epidemiologic studies,[4,7,44] characteristics used for AJCC staging have also been shown to be prognostic for development of distant metastasis. T stage is based on the largest basal diameter and thickness of the primary tumor, as well as the presence or absence of ciliary body involvement and presence and size of extraocular extension.[20] Multiple large studies (N > 1000) have shown that primary tumor diameter and/or thickness is

Discussion update in progress

Version 1.2026 © 2026 National Comprehensive Cancer Network© (NCCN©), All rights reserved. NCCN Guidelines® and this illustration may not be reproduced in any form without the express written permission of NCCN.

PLEASE NOTE that use of this NCCN Content is governed by the End-User License Agreement, and you MAY NOT distribute this Content or use it with any artificial intelligence model or tool.
Printed by Galya Basol Kochav on 2/13/2026 11:27:31 AM. Copyright © 2026 National Comprehensive Cancer Network, Inc. All Rights Reserved.

associated with risk of metastasis after primary treatment.[66,357,400,408] Additionally, several retrospective studies on large patient populations have found that risk of metastasis is correlated with AJCC T stage and with AJCC staging.[4,5,222,405,409]

Multiple tumor molecular markers have been shown to be associated with increased risk and/or shorter time to development of distant metastases. Chromosomal changes were among the first molecular markers to be found to be associated with risk of distant metastasis in patients with uveal melanoma.[410] Multiple studies have found that monosomy 3 and gain of chromosome 8q, especially when numerous copies are found, in the primary uveal melanoma is associated with increased risk of metastasis.[13,34,45Chang, 2013 #7694,406,408,411-416] Risk of metastasis is even higher when both of these abnormalities are present.[13,45,415] Some studies have identified additional chromosomal abnormalities associated with increased risk of metastasis, such as loss of 8p, loss of 1p, loss of 16q, and loss of 6q.[13,411,417-419] Gain of 6q may be protective against metastasis, at least in the context of monosomy 3 and gain of 8q.[13,419]

Mutation and expression of certain genes have also been associated with risk of metastasis in patients with uveal melanoma. Multiple studies have found that *BAP1* mutation/deletion (observed in approximately half of uveal melanomas) and loss of *BAP* expression in the primary tumor is associated with increased risk of metastasis.[401,406,416,420,421] One study showed that risk of metastasis is highest with *BAP1* somatic mutation, and somewhat elevated with *BAP1* germline mutation.[422] Other studies found that *BAP1* mutation was associated with early metastasis.[423,424] Mutation in *EIF1AX*, found in up to 20% of uveal melanomas, has been associated with lower risk of distant metastasis.[25,401,423-427] *SF3B1* mutation, which is present in approximately 20% of uveal melanomas, was associated with lower risk of metastasis,[25,51] while some studies reported that patients with this mutation developed late metastases.[423,424,427] PRAME expression, present in about a third of uveal melanomas, has also been associated with increased risk of metastasis.[402,405,428]

Follow-up for Distant Metastasis

Given the lack of high-quality data to inform the frequency or modality of follow-up screening for distant metastatic disease, the NCCN recommendations are based on clinical practice at NCCN Member Institutions. Patients with no evidence of disease (NED) after treatment for uveal melanoma should be followed for signs of metastatic disease. The most frequent site of metastasis is the liver and other sites include lungs, skin/soft tissue, and bones. Recommended follow-up for distant metastatic disease includes imaging to evaluate signs or symptoms of distant metastasis and may include regular surveillance imaging. Liver function tests (LFTs) may be considered as a component of follow-up visits, although some studies showed poor sensitivity for early detection of liver metastases.

For patients who elect to have surveillance imaging to screen for distant metastatic disease, options include contrast-enhanced MR or US of the liver, with modality preference determined by expertise at the treating institution. Additional imaging modalities may include chest/abdomen/pelvis CT with contrast, or dual-energy subtraction chest x-ray. However, screening should limit radiation exposure whenever possible. Scans should be performed with IV contrast unless contraindicated. Recommendations for imaging modality are based on clinical practice at NCCN Member Institutions, as there are very few data to inform selection of modality. Providers may also want to discuss mental health resources with patients. See the NCCN Guidelines for Survivorship (www.NCCN.org). Participation in a clinical trial is strongly encouraged.

For those choosing to have regular surveillance, the recommended frequency is based on the risk of distant metastasis. The NCCN

Discussion update in progress

Version 1.2026 © 2026 National Comprehensive Cancer Network© (NCCN©), All rights reserved. NCCN Guidelines® and this illustration may not be reproduced in any form without the express written permission of NCCN.

PLEASE NOTE that use of this NCCN Content is governed by the End-User License Agreement, and you MAY NOT distribute this Content or use it with any artificial intelligence model or tool.
Printed by Galya Basol Kochav on 2/13/2026 11:27:31 AM. Copyright © 2026 National Comprehensive Cancer Network, Inc. All Rights Reserved.

Guidelines recommend risk stratifying patients into low, medium, and high risk of distant metastasis based on the highest risk factor present. For patients with high risk of distant metastasis who opt to have surveillance imaging, the recommended frequency is every 3 to 6 months for 5 years, then every 6 to 12 months for years 6 through 10, then as clinically indicated. For patients with medium risk of distant metastasis who opt to have surveillance imaging, the recommended frequency is every 6 to 12 months for 10 years, then as clinically indicated. For patients with low risk of metastasis who opt to have surveillance imaging, consider imaging every 12 months for 5 years or as clinically indicated. Adjusting follow-up frequency based on risk of metastasis is based on clinical practice at NCCN Member Institutions, and this approach has not been prospectively tested to determine whether it results in better yield from imaging or better outcomes.

There are few data to inform the frequency and modality of follow-up screening for development of metastatic disease. Prospective studies have typically monitored for development of distant metastasis using complete cancer-oriented physical exams, and one or more of the following: chest x-ray, liver US, and serum LFTs. Most of these studies followed patients every 6 months for at least the first 5 years.[8,11,234,300,373,374,392,422] For these studies, the total number of patients who developed distant metastatic disease was usually too small to produce meaningful results regarding the sensitivity and specificity of different surveillance modalities. The value of surveillance imaging and tests is also controversial because it is unclear whether early detection of distant metastases improves outcomes, given that most treatments for distant metastatic disease are relatively ineffective. Some retrospective studies found that survival was better for patients whose distant metastatic disease was asymptomatic at the time of detection,[429,430] whereas other studies observed no such correlation.[10,431,432]

The utility of LFTs for early detection of liver metastases is an issue of ongoing debate. In the COMS trials for patients with medium and large tumors, the sensitivity, specificity, positive predictive value, and negative predictive value associated with at least one abnormal LFT before first diagnosis of metastasis at any site was 14.7%, 92.3%, 45.7%, and 71.0%, respectively. Of the LFTs, alkaline phosphatase (ALP) had the highest diagnostic attributes. These results suggest that the use of LFT results followed by other diagnostic tests has high specificity and predictive values, but low sensitivity.[373] Whereas 739 patients had distant metastases detected during follow-up, 13 did not have their metastasis discovered until time of death.[374] While some analyses supported LFTs as one of the most useful methods for screening,[433-435] others argue that the specificity and sensitivity of these tests is too low to warrant routine use.[436-438]

The optimal strategy for imaging surveillance is also an issue of debate. Each of the methods commonly used (ie, chest x-ray, CT, US, MRI, PET/CT) has produced varying results.[438-442] Due to the low probability of metastasis at any specific time point, the yield of these tests is low, and there is concern regarding cumulative radiation exposure due to the long-term follow-up.[443] Therefore, imaging is usually focused on the liver, and liver US and MRI are favored over CT or PET/CT. Some studies have found MRI to be moderately better than CT or PET/CT,[444-446] and in patients at high risk, showed promising results for early detection of liver metastases.[438,447]

Risk of Developing Secondary Cancers During Follow-up

Due to the long-term surveillance needed for detection of distant metastatic disease in patients with uveal melanoma, it is not uncommon for screens to identify other primary cancers.[123,126,441,448,449] The two COMS randomized trials in patients with medium to large primary uveal melanomas showed that the proportion of patients with secondary cancers increased steadily over the entire duration of follow-up (median 10 years,

Discussion update in progress

Version 1.2026 © 2026 National Comprehensive Cancer Network© (NCCN©), All rights reserved. NCCN Guidelines® and this illustration may not be reproduced in any form without the express written permission of NCCN.

PLEASE NOTE that use of this NCCN Content is governed by the End-User License Agreement, and you MAY NOT distribute this Content or use it with any artificial intelligence model or tool.
Printed by Galya Basol Kochav on 2/13/2026 11:27:31 AM. Copyright © 2026 National Comprehensive Cancer Network, Inc. All Rights Reserved.

range 5–16 years).[448] Various types of secondary malignancies were observed.[123,448] Uveal melanoma may increase the risk of developing other cancers,[124] especially in patients with familial uveal melanoma or other familial cancers.[89,90]

Management of Ocular Recurrence

Workup for Ocular Recurrence

If a recurrence is detected, workup should include H&P to identify any signs or symptoms associated with recurrence or metastasis. Biopsy may also be appropriate. Whereas intraocular recurrence can often be diagnosed and managed without a biopsy, additional prognostic FNA biopsy may be valuable to determine whether the tumor has developed any high-risk features that warrant more frequent surveillance. Extraocular recurrence or metastasis should be confirmed histologically whenever possible or if clinically indicated. Appropriate biopsy techniques in this setting may include core needle biopsy, if possible, or otherwise FNA. For patients with metastasis who are considering treatment with targeted therapy, tissue should be obtained for genetic analysis (screening for mutations that may be potential targets for treatment or to determine eligibility for a clinical trial) from either biopsy of the metastasis (preferred) or archival material. Broader genomic profiling may be considered if the results could inform future treatment decisions or eligibility for clinical trials.

Patients with local recurrence should have ocular orbital imaging (if not previously done or as clinically indicated) to evaluate the extent of local recurrence. Patients who develop distant metastatic disease after treatment of primary uveal melanoma should have ocular orbital imaging as part of workup to check for local recurrence, since asymptomatic local recurrences may be present at the time distant metastasis is discovered. Workup for patients with recurrence should include broader imaging to evaluate the extent of local recurrence/distant metastasis, and/or baseline staging. Since the most frequent site of metastasis is the liver and other sites include lungs, skin/soft tissue, and bones, imaging options for baseline staging in patients with recurrence or metastasis include contrast-enhanced MRI, CT abdomen with or without pelvis, or abdominal US, with modality preference determined by expertise at the treating institution. Chest imaging can be performed with CT without contrast or via chest x-ray.

Treatment for Ocular Recurrence

The recommended treatment options for local recurrence depend on the extent of disease. For intraocular recurrence (limited to the eye, without orbital involvement), the recommended options include RT, either by plaque brachytherapy or particle beam, enucleation, or laser ablation. For small recurrences in patients who cannot undergo RT or surgery, TTT is recommended. TTT is usually reserved for small recurrences, particularly when recurrence is likely due to incomplete plaque coverage during primary brachytherapy; it is generally not appropriate for recurrences occurring within the RT field or recurrences that may be too thick (>3 mm) for laser treatment to reach the base. If there is extraocular involvement, surgical resection is needed but can be coupled with RT to the orbit and/or cryotherapy to the orbital tumor. Surgical resection may potentially include partial orbital tumor resection, enucleation, or exenteration. Besides surgical resection, RT with plaque brachytherapy or particle beam alone might be offered. If there is orbital involvement and the patient has had prior enucleation, options include surgical resection or cryotherapy to the orbital tumor, and/or RT to the orbit (See *Principles of Radiation Therapy* in the algorithm).

Given the rarity of local recurrence after treatment of primary uveal melanoma, data on treatment of local recurrences are scant, and it is unclear which approaches result in the best outcomes. Most studies had <10 patients with local recurrence, and many studies either managed all

Discussion update in progress

Version 1.2026 © 2026 National Comprehensive Cancer Network© (NCCN©), All rights reserved. NCCN Guidelines® and this illustration may not be reproduced in any form without the express written permission of NCCN.

PLEASE NOTE that use of this NCCN Content is governed by the End-User License Agreement, and you MAY NOT distribute this Content or use it with any artificial intelligence model or tool.
Printed by Galya Basol Kochav on 2/13/2026 11:27:31 AM. Copyright © 2026 National Comprehensive Cancer Network, Inc. All Rights Reserved.

local recurrences with enucleation or did not report on retreatment approaches. In the few studies that reported outcomes after treatment of local recurrence (N ≥ 10), reasonably high rates of local control were achieved with the following globe-conserving modalities: laser photocoagulation,[282] TTT,[450] proton-beam RT,[451,452] and plaque brachytherapy RT.[265,453] Similar to the primary treatment setting, some patients treated with globe-conserving therapy for local recurrence subsequently underwent enucleation due to (suspected or confirmed) tumor regrowth or complications such as pain and neovascular glaucoma.[451,453-455] Results from one retrospective study of 73 patients with local recurrence suggest that treating recurrence with proton-beam RT (N = 31) versus enucleation (N = 42) may result in similar metastasis-free survival and OS.[456] Another retrospective analysis of 51 patients with local recurrence found that local control after treatment of recurrence was more likely in those with longer intervals between primary treatment and development of recurrence.[282]

Management of Metastatic Disease

Survival after detection of distant metastatic disease varies widely across studies, including those with large patient samples (N > 100), with median OS ranging from 3 to 30 months.[10-12,457-459] Several studies have found that a small percentage of patients with uveal melanoma metastasis experience long-term survival (≥5 years) after development of distant metastatic disease.[8,10,374] Others have shown a bimodal distribution of separate populations with short-term survival (median OS <1 year) and long-term survival (median OS >2 years).[8,10,460] Conflicting data exist for a wide range of factors that have been associated with OS after detection of metastasis including >50 years, assigned male at birth, and poor performance status.[11,391,459,461,462] Other factors include the presence of symptoms versus asymptomatic metastasis detected by surveillance, shorter disease-free interval before metastasis, higher number of anatomic sites involved, involvement of the liver, and greater disease volume.[8,11,389,391,392,430,432,459,461-467] In addition, elevated liver enzymes at the time of diagnosis of metastasis, particularly lactate dehydrogenase (LDH) and ALP, have been associated with shorter OS.

Whereas the options for treating metastatic cutaneous melanoma have dramatically improved, treatment of distant metastases from uveal melanoma still presents a major clinical challenge in the community. Several retrospective studies suggest that treatment for distant metastases from uveal melanoma improves survival, although it is unclear whether these results are influenced by selection bias.[10,12,389,391,466] Other studies did not find that treatment improved survival.[374,462] Patients treated with supportive care reported a median OS ranging from 1.7 to 4.9 months, although those opting for supportive care are more likely to have risk factors for poor survival.[12,389,391] For treatment of distant metastasis from uveal melanoma, a wide variety of approaches have been tested, including surgery, RT, ablative approaches, vaccines, systemic therapies (chemotherapies, immunotherapies, targeted therapies, and combined regimens), and localized chemotherapy/immunotherapy.[11,458,468] Studies suggest that the best outcomes are seen with receipt of liver-directed treatments, particularly in those treated with surgery when complete resection was achieved.[438,461,463,466,467,469]

Among patients with metastatic uveal melanoma, those who can be treated with surgery have the best outcomes, especially if complete resection is achieved. A median OS >20 months after resection of uveal melanoma metastases was previously reported along with a wide range of complete resection rates for patients with liver metastases.[458,470] It is unclear whether these effects are due to other factors, such as lower volume of metastatic disease, which would make a patient eligible for surgery and/or liver-directed treatments, and more likely to have complete resection.

Discussion update in progress

Version 1.2026 © 2026 National Comprehensive Cancer Network© (NCCN©), All rights reserved. NCCN Guidelines® and this illustration may not be reproduced in any form without the express written permission of NCCN.

PLEASE NOTE that use of this NCCN Content is governed by the End-User License Agreement, and you MAY NOT distribute this Content or use it with any artificial intelligence model or tool.
Printed by Galya Basol Kochav on 2/13/2026 11:27:31 AM. Copyright © 2026 National Comprehensive Cancer Network, Inc. All Rights Reserved.

Workup for Distant Metastatic Disease

Workup for distant metastatic disease includes biopsy if clinically appropriate. Similar to workup for ocular recurrence, metastasis should be confirmed histologically whenever possible or if clinically indicated. Biopsy techniques may include core needle biopsy, if possible, or otherwise FNA. Tissue should be obtained for genetic analysis (screening for mutations that may be potential targets for treatment or determine eligibility for a clinical trial) from either biopsy of the metastasis (preferred) or archival material if the patient is being considered for targeted therapy. Broader genomic profiling should be considered if the test results might guide future decisions or eligibility for participation in a clinical trial. Imaging can be considered for baseline staging and evaluating specific signs and symptoms. The most frequent site of metastasis is the liver and other sites include lungs, skin/soft tissue, and bones. Modalities of choice for detection of metastasis are CT chest/abdomen/pelvis with IV iodinated contrast, CT chest with or without IV contrast, and MRI abdomen with IV gadolinium-based contrast or whole-body FDG-PET/CT. In select patients with renal failure and/or iodinated contrast allergy, MR abdomen with gadolinium-based contrast is the preferred imaging study over CT. If no IV contrast can be administered, MR without contrast is superior to non-enhanced CT. US evaluation of the liver can be used in select patients; however, it has limited value given its operator-dependent nature, limited sensitivity in patients affected with obesity, and lack of specificity. Brain MRI with IV contrast may be performed if neurologic symptoms are present, but routine CNS imaging is not recommended. Abdominal imaging should be performed with IV contrast unless contraindicated. HLA-A*02:01 testing is recommended for patients with distant metastatic disease to evaluate patients for treatment with tebentafusp. Testing of LFTs, including LDH, and ALP should be considered for their potential prognostic value.

Treatment for Distant Metastatic Disease

Given that there are no treatments for metastatic uveal melanoma, except for the FDA-approved tebentafusp, that have clearly and consistently been shown to improve outcomes, it is important to consider all clinical trial options carefully, and when available and clinically appropriate, enrollment in a clinical trial is recommended as preferred. For those who are not appropriate for treatment in the context of a clinical trial, the recommended options are largely based on clinical practice at NCCN Member Institutions separated as hepatic-dominant and non-hepatic dominate disease. It is important to be aware that even among therapies often used at NCCN Member Institutions, efficacy is limited, and it is not clear which approaches are most effective. Therefore, the guidelines indicate that a combination of approaches may be needed, and it is important to consider each patient's prognosis and treatment goals to determine whether palliative care is the most appropriate option.

Selection of treatment should depend on the location and extent of disease. For patients with hepatic-dominant disease where the bulk of overall metastatic disease is confined to the liver, liver-directed therapies should be considered. Options include: melphalan percutaneous hepatic perfusion (PHP), embolization (ie, chemotherapy, radiation, immunotherapy), ablative procedures (ie, thermal ablation, cryotherapy) and consideration of resection and/or RT (photon beam or SRS for limited or symptomatic disease of the liver). Recommendations for treating uveal melanoma metastases with RT can be found within *Principles of Radiation Therapy* in the algorithm. For patients with hepatic-dominant and non-hepatic dominant disease that are not amenable to liver-directed therapy, systemic therapy can be considered.

Following treatment for metastatic disease, patients should receive imaging to assess response or progression. The recommended cross-sectional imaging modalities are the same as those recommended for

Discussion update in progress

Version 1.2026 © 2026 National Comprehensive Cancer Network© (NCCN©), All rights reserved. NCCN Guidelines® and this illustration may not be reproduced in any form without the express written permission of NCCN.

PLEASE NOTE that use of this NCCN Content is governed by the End-User License Agreement, and you MAY NOT distribute this Content or use it with any artificial intelligence model or tool.
Printed by Galya Basol Kochav on 2/13/2026 11:27:31 AM. Copyright © 2026 National Comprehensive Cancer Network, Inc. All Rights Reserved.

workup. Those with NED after treatment for metastases may be eligible for clinical trials testing adjuvant therapies, if available. If patients opt to forgo adjuvant treatment, then the recommended follow-up surveillance is similar to the follow-up for patients with NED after treatment of localized disease (See *Risk of Distant Metastasis – Systemic Imaging Based on Risk Stratification* in the algorithm). If post-treatment imaging shows residual or progressive disease, the NCCN Panel recommends trying other options for treatment of distant metastatic disease.

Liver-Directed Therapy

Regional Isolation Perfusion

Several techniques have been developed for localized delivery of pharmaceutical therapy to the liver since theoretically, higher doses can be administered locally than would be feasible systemically due to toxicity. Methods include isolated hepatic infusion (IHP), PHP, HAI, and embolization techniques. Liver metastases derive most of their blood supply from the hepatic artery, whereas the blood source for benign hepatocytes is primarily the portal vein.[471] IHP and hepatic arterial infusion (HAI) both deliver therapy via the hepatic artery to maximize drug delivery to liver metastases while limiting exposure to healthy parenchyma.[472] Whereas IHP is done during surgery, has risk of morbidity, and usually can only be done once, HAI and PHP are less invasive techniques, with lower risk of morbidity, and have the potential to be performed multiple times to increase depth of response.[458,469,472-474]

PHP is recommended by the NCCN Panel as a liver-directed therapy.[469,473] PHP uses a double-balloon catheter inserted into the inferior vena cava to isolate hepatic venous blood that is then filtered extracorporeally.[469,473] Melphalan PHP was tested in patients with hepatic-dominant metastatic uveal melanoma with <50% liver involvement and associated with a 36.6% response rate in a phase II trial (N = 91),[475] and with improved response rate (36.3% vs. 12.5%) and median PFS (9 vs. 3.1 months) compared with best alternative care in a phase III trial (n = 123 treated).[476] Median OS was similar (19.3 vs. 14.5 months, *P* = .14). Overnight stay in an intensive care unit is recommended for hemodynamic monitoring; this therapy is recommended only at experienced centers.

Retrospective studies suggest good response rates (>40%), especially if multiple rounds are used.[477-480] In all these studies melphalan was the agent used. PHP appears to be somewhat better tolerated than IHP, with no treatment-related fatalities, but many patients still experienced hematologic grade 3–4 events, some had non-hematologic grade 3–4 adverse events (AEs) (eg, bleeds, thromboembolism), and some had extended hospital stays (4–5 days) or had to be readmitted.[477,478,481,482]

Hepatic Embolization

Hepatic arterial embolization is a liver delivery method for chemotherapy, immunotherapy, or radioactive agents, that increases dwell time and provides selective ischemia.[469,474]

Hepatic Chemoembolization

There are no standard protocols for hepatic chemoembolization, also called hepatic TACE or hepatic arterial chemoembolization (HACE). In general, two approaches have been used for treatment of uveal melanoma metastases to the liver. One involves HAI with the active agent, followed by addition of either a transient or permanent embolic agent.[469,474] The active agent is usually mixed with ethiodized oil (to increase dwell time), and embolization agents include absorbable gelatin sponge or polyvinyl alcohol particles.[469,474] The other approach uses drug-eluting beads produced from a polyvinyl alcohol hydrogel that has been modified with sulfonate groups for the controlled loading and delivery of chemotherapy agents.[474] These beads provide localized drug delivery and serve as an embolic agent to render tumors ischemic.[474]

Discussion update in progress

Version 1.2026 © 2026 National Comprehensive Cancer Network© (NCCN©), All rights reserved. NCCN Guidelines® and this illustration may not be reproduced in any form without the express written permission of NCCN.

PLEASE NOTE that use of this NCCN Content is governed by the End-User License Agreement, and you MAY NOT distribute this Content or use it with any artificial intelligence model or tool.
Printed by Galya Basol Kochav on 2/13/2026 11:27:31 AM. Copyright © 2026 National Comprehensive Cancer Network, Inc. All Rights Reserved.

Studies have evaluated chemoembolization for the treatment of hepatic metastasis in patients with uveal melanoma. Using traditional methods (active agent infusion + addition of embolic agent), response rates have varied widely.[483,484] A phase II study reported 100% ORR in the 10 patients treated with irinotecan-loaded polyvinyl alcohol microspheres.[485] In contrast, a retrospective study of irinotecan-loaded beads in 28 patients reported much lower response rates.[486] A retrospective study including 58 patients treated with TACE using irinotecan-charged microbeads reported an overall response rate (ORR) of 27.5% (all partial responses).[487]

Comparisons of hepatic chemoembolization with other treatments for uveal melanoma liver metastasis are limited. One retrospective study compared cisplatin-based chemoembolization (TACE) versus HAI or systemic therapy, and found that chemoembolization was associated with the best response rate, although OS did not differ between the groups.[488] The correlation between chemoembolization and OS remains an ongoing debate.[484,487,489-493]

Chemoembolization seems to be generally well tolerated, with few or no treatment-related deaths. AEs reported include abdominal pain, fever, nausea, vomiting, liver dysfunction, and thrombocytopenia.[484,487,494] Some studies recommend supportive treatment with antibiotic and antiemetic prophylaxis, IV hydration, and major analgesic before and after the procedure.[483,485]

Hepatic Radioembolization

Hepatic radioembolization, also called hepatic transarterial radioembolization (TARE) or selective internal RT (SIRT), is a procedure in which glass or resin yttrium-90 microspheres are introduced to the hepatic artery, both as a mechanism for radiation delivery and for embolization.[474] Response rates from retrospective studies varied widely (6%–100%), but disease control rate (DCR) was consistently >50%.[495-497] A phase II study reported an ORR of 39% in the 23 patients who received radioembolization as first-line treatment for liver metastasis, and an ORR of 33% in the 24 patients who received radioembolization after progression on immunoembolization, with DCRs of 87% and 58%, respectively.[498] Across studies, radioembolization was well tolerated, with most toxicities being grade 1–2 and self-limiting, and there were no treatment-related deaths.[495,499-502] AEs included abdominal pain/discomfort, nausea and vomiting, and LFT elevation.

Hepatic Immunoembolization

Hepatic immunoembolization involves infusion of an immunologic stimulant into the hepatic artery, followed by addition of an embolizing agent.[474] Several studies have tested immunoembolization using granulocyte-macrophage colony-stimulating factor (GM-CSF) ethiodized oil plus a gelatin sponge.[503,504] A phase I trial with 34 patients with uveal melanoma and unresectable liver metastases occupying <50% of total liver volume reported an ORR in the liver of 32%, and response correlated with better OS.[503] A phase II randomized trial with 52 patients with uveal melanoma and hepatic metastases only (also <50% liver volume) reported an ORR of 21.2% for the 25 patients treated with immunoembolization versus 16.7% for the 27 who received bland embolization (GM-CSF replaced with saline).[504] In this study hepatic response was not correlated with OS, but was associated with better PFS. AEs associated with immunoembolization in these studies included abdominal pain, fever, nausea, and transient increases in hepatic enzymes and there were no treatment-related deaths.[503,504]

Discussion update in progress

Version 1.2026 © 2026 National Comprehensive Cancer Network© (NCCN©), All rights reserved. NCCN Guidelines® and this illustration may not be reproduced in any form without the express written permission of NCCN.

PLEASE NOTE that use of this NCCN Content is governed by the End-User License Agreement, and you MAY NOT distribute this Content or use it with any artificial intelligence model or tool.
Printed by Galya Basol Kochav on 2/13/2026 11:27:31 AM. Copyright © 2026 National Comprehensive Cancer Network, Inc. All Rights Reserved.

Ablative Procedures for Liver Metastases

Although ablative procedures such as thermal ablation and cryotherapy have been used with some success for liver metastases from other kinds of cancer, there are very few reported clinical data on the efficacy of these techniques for liver metastases from uveal melanoma. [505-511] The supposed advantage of ablative techniques is that these techniques can be useful for tumors that are difficult to resect, and compared to surgery, are tissue-sparing, less invasive, cost-saving, and have lower rates of complications, while still being potentially curative.[512] The most commonly used methods of thermal ablation for liver tumors include radiofrequency ablation (RFA) and microwave ablation (MWA).[512-514] Both methods use heat induction and destroy tissue through thermally induced coagulative necrosis. MFA and RFA appear to be similarly safe and effective with rare major complications.[514,515] On the other hand, cryoablation dehydrates and causes irreversible cell damage and cell death by using rapid gas expansion at a probe tip to quickly cool surrounding tissues to as low as -140°C.[511] Complications may include pain, infection (eg, wound infection, pneumonia), hemorrhage, biliary injury, thrombocytopenia, pleural effusion, and renal impairment.[511,513,516,517] Whereas some studies found that cryoablation was more likely to cause complications compared with RFA, other analyses suggest that complication rates are similar to RFA.[511,516,517]

Outcomes have been reported for patients with liver metastases from uveal melanoma treated with RFA and laser-induced interstitial thermotherapy (LITT). The efficacy and safety of ablative techniques is difficult to ascertain, because most of these studies contained <20 patients with uveal melanoma, combined results for patients with uveal melanoma and other types of melanoma, or combined results for the ablative therapy with other therapies.[505-510] Nonetheless, several retrospective studies reported relatively long median OS of >20 months in cohorts of patients with uveal melanoma with liver metastases treated with LITT (±TACE), RFA, or percutaneous thermal ablation (± systemic therapy).[505-507] In a retrospective study of patients with uveal melanoma with liver metastases treated with surgery alone (N = 57) or a combined approach in which some metastases were resected and others were treated with RFA (N = 13), those treated with the combination approach had similar disease-free survival as those treated with surgery alone (median 7 vs. 10 months) and OS (median 28 vs. 27 months).[509] Moreover, there were no recurrences at the 22 sites treated with RFA after a median follow-up of 63 months.[509] These results suggest that RFA may be as effective as surgery, and could be used in lieu of surgery for metastases that are difficult to resect.

External Beam Radiation for Uveal Melanoma Metastases

Published data on external beam RT for uveal melanoma metastases are extremely scant with no study reporting outcomes or palliative effects.

Systemic Therapy for Distant Metastatic Disease

Many systemic therapies have been tested as treatments for metastatic uveal melanoma, including immunotherapies, chemotherapies, targeted therapies, and systemic therapy combinations. For treatment of metastatic uveal melanoma, systemic therapies had largely been tested in small phase II studies and with little activity (response rate <10%),[518] especially compared with the efficacy of checkpoint immunotherapies and BRAF/MEK inhibitor combinations in metastatic cutaneous melanoma. The few larger randomized phase II/III trials comparing systemic therapies for metastatic uveal melanoma have not identified any systemic therapies that are consistently more effective than chemotherapy,[519-523] except data for tebentafusp.[524] Meta-analyses suggest that for metastatic uveal melanoma, systemic therapy appears to result in worse outcomes than localized treatment (surgery or liver-directed therapies), although differing patient selection criteria across studies may be a confounding factor.[11,458] For patients whose disease is not appropriate for localized therapy,

Discussion update in progress

Version 1.2026 © 2026 National Comprehensive Cancer Network© (NCCN©), All rights reserved. NCCN Guidelines® and this illustration may not be reproduced in any form without the express written permission of NCCN.

PLEASE NOTE that use of this NCCN Content is governed by the End-User License Agreement, and you MAY NOT distribute this Content or use it with any artificial intelligence model or tool.
Printed by Galya Basol Kochav on 2/13/2026 11:27:31 AM. Copyright © 2026 National Comprehensive Cancer Network, Inc. All Rights Reserved.

selection of systemic therapy is very challenging, necessitating further study into better options.

Immunotherapy

Checkpoint immunotherapies were tested in prospective studies for metastatic uveal melanoma including anti-CTLA-4 agent ipilimumab, anti-programmed cell death protein 1 (PD-1) agents nivolumab and pembrolizumab, nivolumab/ipilimumab combination therapy, and bispecific protein tebentafusp-tebn.

Ipilimumab

Two phase II studies evaluated single-agent ipilimumab as a treatment for patients with metastatic uveal melanoma.[525,526] Piulats et al conducted an open-label, phase II, multicenter, single-arm trial (N = 32) to evaluate ipilimumab in patients with metastatic uveal melanoma. Induction therapy consists of ipilimumab for four cycles at 10 mg/kg every 3 weeks, and every 12 weeks for maintenance therapy. The median OS was 9.8 months, and partial response was seen in 6.5% of patients while grade 3–4 AEs were reported as 10%. The ipilimumab safety profile is similar to prior reports in patients with cutaneous melanoma. Response rate seemed promising at the time while mature OS and PFS results were pending. In 2015, a phase II De-COG study by Zimmer et al. also evaluated ipilimumab in patients with metastatic uveal melanoma. The median OS was 6.8 months, and median progression-free survival (PFS) was 2.8 months. The DCR was 47% and 21% at 12 and 24 weeks, respectively. No patients experienced complete or partial response, but 16 patients had stable disease, and 36% patients had grade 3–4 AEs indicating a limited clinical activity and manageable toxicity in this patient group.

Nivolumab or Pembrolizumab Monotherapy

Nivolumab and pembrolizumab are anti PD-1 antibodies that inhibit the interaction between PD-1 and programmed death ligand 1 (PD-L1). Although one prospective study reported no responses in 17 patients treated with anti-PD-1 systemic therapy,[527] two other prospective trials reported ORRs between 6% to 38%, with eight responses among a total of 81 patients treated (8%).[528,529] Median PFS ranged from 2.3 to 11 months. In a phase II, single-arm, open-label, multicenter CheckMate 172 study evaluating efficacy of nivolumab in patients with disease progression on ipilimumab (N = 734), nivolumab was given at a dose of 3 mg/kg every 2 weeks for up to 2 years until disease progression or unacceptable toxicity.[530] At week 12 the ORR was 32%, with a complete response in 1% of patients. The OS rate at 1 year was 63% and any grade 3 or 4 treatment-related adverse events (TRAEs) occurred in 66% and 17% of patients, respectively. A subsequent study on safety and efficacy demonstrated that the safety profile of nivolumab after ipilimumab is similar across various melanoma subtypes.[531]

Nivolumab and Ipilimumab

Two phase II trials tested nivolumab and ipilimumab in patients with metastatic uveal melanoma.[532,533] [532,533] In Pelster et al previously treated patients received nivolumab 1 mg/kg and ipilimumab 3 mg/kg for four cycles, followed by nivolumab maintenance therapy for up to 2 years.[532] Of the 35 patients enrolled, 33 patients were evaluable for efficacy. The ORR was 18%, including one patient with complete response and five partial responses. The median PFS was 5.5 months, the median OS was 19.1 months, and 40% of patients experienced a grade 3 or 4 TRAEs.

A single-arm, phase II GEM-1402 trial investigated nivolumab plus ipilimumab as a systemic therapy in treatment-naïve patients of >18 years of age, with histologically confirmed metastatic uveal melanoma and ECOG-PS 0/1.[533] Nivolumab (1 mg/kg every 3 weeks) and ipilimumab (3 mg/kg every 3 weeks) were administered during four inductions, followed by nivolumab (3 mg/kg every 2 weeks) until progressive disease, toxicity, or withdrawal.

Discussion update in progress

Version 1.2026 © 2026 National Comprehensive Cancer Network© (NCCN©), All rights reserved. NCCN Guidelines® and this illustration may not be reproduced in any form without the express written permission of NCCN.

PLEASE NOTE that use of this NCCN Content is governed by the End-User License Agreement, and you MAY NOT distribute this Content or use it with any artificial intelligence model or tool.
Printed by Galya Basol Kochav on 2/13/2026 11:27:31 AM. Copyright © 2026 National Comprehensive Cancer Network, Inc. All Rights Reserved.

A total of 52 patients with a median age of 59 years were enrolled. Overall, 78.8%, 56%, and 32% of patients had liver metastases, extra-liver metastases, and elevated LDH. Stable disease was the most common outcome (51.9%). The primary end point was 12-month OS, which was 51.9%. The median OS and PFS were 12.7 months and 3.0 months, respectively. PFS was influenced by higher LDH values. Combination in the first-line setting for metastatic uveal melanoma showed a modest improvement in OS over historical benchmarks of chemotherapy, with a manageable toxicity profile. Comparative studies are needed to determine whether combination anti-CTLA-4/anti-PD-1 consistently improves outcomes in patients with metastatic uveal melanoma.

Tebentafusp-tebn

Tebentafusp is a bispecific gp100-HLA-A*02:01-directed T-cell receptor and CD3 T-cell engager that elicits a polyclonal T-cell response against uveal melanoma cells and can be tested via a blood sample. Tebentafusp-tebn was tested in a large phase III randomized trial (N = 378) in patients previously untreated with HLA-A*02:01-positive metastatic uveal melanoma.[524] Patients were randomized 2:1 to receive tebentafusp or investigator's choice of single-agent pembrolizumab, ipilimumab, or dacarbazine. At 1 year OS was significantly higher in the tebentafusp group versus the control group (73% vs. 59%). The same was true for PFS (31% vs. 19%) at 6 months. The OS advantage but relatively low response rate (9% in the tebentafusp group vs. 5% in the control group) suggests that recipients of tebentafusp live longer but there might not be tumor shrinkage. Therefore, patients who present with symptomatic liver metastases may prefer to start with liver-directed therapies or nivolumab/ipilimumab. Treatment-related events infrequently led to discontinuation of the trial treatment (2%) and no treatment-related death was reported. Tebentafusp was associated with cytokine-release syndrome, at least for the first few cycles; therefore, hospitalization to monitor for and treat this condition should be indicated.[534]

Hassel et al reported 3-year efficacy and safety results for tebentafusp where the median OS was 21.6 months in the tebentafusp group and 16.9 months in the control group.[535] The estimated percentage of patient survival at 3 years was 27% versus 18%, respectively. As previously reported, most tebentafusp TRAEs occurred early during treatment, no new AEs were observed with long-term administration, treatment discontinuation due to TRAEs remained consistent at 2%, and no treatment-related deaths occurred. These data support a continued long-term benefit of tebentafusp for OS. However, it is important to note that tebentafusp has not been compared to the ipilimumab and nivolumab combination nor has it been compared to liver-directed therapy even though ~50% of the patients had liver-only disease.

Cytotoxic Regimens

A wide variety of chemotherapies have been tested in prospective trials in patients with metastatic uveal melanoma, and outcomes have been reported for the following single-agent chemotherapies: dacarbazine,[520,522,536] paclitaxel, [537] temozolomide,[522] DHA-paclitaxel,[538] fotemustine,[539] bendamustine,[540] treosulfan,[541] liposomal vincristine,[542] arsenic trioxide,[543] and lenalidomide.[544] Most studies evaluated patients for response to treatment, but responses to these therapies were rarely observed. The few responses observed were in patients treated with fotemustine (2/83), liposomal vincristine (1/4), dacarbazine (3/36), and DHA-paclitaxel (1/22). For the studies that measured PFS and OS with these single-agent chemotherapy regimens, median PFS was always <4 months, and median OS was nearly always >10 months.[521,522,536,538,539,545] It remains unclear whether any single-agent chemotherapy improves survival relative to best supportive care. However, the NCCN Panel does recommend the use of dacarbazine, temozolomide, paclitaxel, and albumin-bound paclitaxel as single-agent chemotherapies useful in certain circumstances.

Discussion update in progress

Version 1.2026 © 2026 National Comprehensive Cancer Network© (NCCN©), All rights reserved. NCCN Guidelines® and this illustration may not be reproduced in any form without the express written permission of NCCN.

PLEASE NOTE that use of this NCCN Content is governed by the End-User License Agreement, and you MAY NOT distribute this Content or use it with any artificial intelligence model or tool.
Printed by Galya Basol Kochav on 2/13/2026 11:27:31 AM. Copyright © 2026 National Comprehensive Cancer Network, Inc. All Rights Reserved.

Combination chemotherapies that have been tested in prospective trials for metastatic uveal melanoma include carboplatin/paclitaxel,[546] gemcitabine/treosulfan,[541] dacarbazine/treosulfan,[547] cisplatin/gemcitabine/treosulfan,[548,549] cisplatin/dacarbazine/vinblastine,[550] docetaxel/carboplatin,[551] and tirapazamine/cisplatin.[552] All of these were tested in pilot, phase I, or phase II studies, most of which reported response rates of <5%. Carboplatin/paclitaxel was evaluated in a double-blind, randomized, placebo-controlled phase III study.[546] All patients (N = 823) received carboplatin/paclitaxel with random assignment to sorafenib or placebo. The median OS was similar between the carboplatin/paclitaxel and carboplatin/paclitaxel + sorafenib groups (11.3 vs 11.1 months). Median PFS (4.2 vs 4.9 months) and response rates (18% vs 20%) were also not significantly different. Toxicity and grade ≥3 TRAEs were also more prevalent in the group with sorafenib. The NCCN Panel recommends carboplatin/paclitaxel as a combination chemotherapy useful in certain circumstances.

Targeted Therapy

Several targeted therapies have been tested as single-agent therapy for patients with metastatic uveal melanoma; however, only trametinib is recommended by the NCCN Panel as a regimen useful in certain circumstances. Targeted therapy combinations that have been tested in prospective trials include trametinib plus uprosertib, an inhibitor of protein kinase B (AKT);[553] binimetinib (MEK inhibitor) plus sotrastaurin (PKC inhibitor);[554] and everolimus (mTOR inhibitor) plus pasireotide (IG1FR inhibitor).[555] Prospective studies in patients with metastatic uveal melanoma have also tested combinations of chemotherapy plus targeted therapy, including carboplatin/paclitaxel/sorafenib,[546,556] fotemustine/sorafenib,[557] dacarbazine/selumetinib,[520] temozolomide/bevacizumab,[558] and carboplatin/paclitaxel/bevacizumab ± everolimus.[519] These prospective studies were pilot studies, phase I trials, and phase II trials, and in most of them the overall response was <10%.Taken together, most meta-analyses concluded that targeted therapy did not improve outcomes relative to conventional chemotherapy.

Although uveal melanomas often express KIT, they rarely harbor the c-KIT mutations associated with response to imatinib in other cancers.[559] Similarly, *BRAF* mutations are rare in uveal melanoma,[554] yet most uveal melanomas carry mutations in *GNAQ* or *GNA11* that result in constitutive activation of the RAS/RAF/MEK/ERK pathway.[23,47,560] Prospective studies of MEK inhibitors have yielded mixed results in patients with metastatic uveal melanoma.[536,553,561] A large phase II randomized trial in 101 patients with metastatic uveal melanoma reported responses in 14% of the 50 patients treated with selumetinib, and no responses in the 51 patients in the comparator arm (chemotherapy with temozolomide or dacarbazine).[536] Selumetinib modestly improved PFS compared with chemotherapy (median 3.7 vs. 1.6 months), although the effect on OS was not significant (median 11.8 vs. 9.1 months).[536] No responses to trametinib were observed in the 16 patients with metastatic uveal melanoma in a phase I trial, and the median PFS was unremarkable (1.8 months).[561] In a subsequent phase II study, 1 of 18 (5.6%) patients with metastatic uveal melanoma responded to single-agent trametinib, and PFS was slightly better (median 3.6 months).[553] These data show that some patients with uveal melanoma may respond to the MEK inhibitor selumetinib, and there are limited data suggesting that trametinib may also be marginally effective. Trametinib is included as a recommended option useful in certain circumstances based on the positive data for selumetinib and the general lack of systemic therapy options for patients with uveal melanoma. However, further study of trametinib for uveal melanoma is needed.

Discussion update in progress

Version 1.2026 © 2026 National Comprehensive Cancer Network© (NCCN©), All rights reserved. NCCN Guidelines® and this illustration may not be reproduced in any form without the express written permission of NCCN.

PLEASE NOTE that use of this NCCN Content is governed by the End-User License Agreement, and you MAY NOT distribute this Content or use it with any artificial intelligence model or tool.
Printed by Galya Basol Kochav on 2/13/2026 11:27:31 AM. Copyright © 2026 National Comprehensive Cancer Network, Inc. All Rights Reserved.

References

1. Xu Y, Lou L, Wang Y, et al. Epidemiological study of uveal melanoma from US surveillance, epidemiology, and end results program (2010-2015). J Ophthalmol 2020;2020:3614039. Available at: https://www.ncbi.nlm.nih.gov/pubmed/32148939.

2. Mahendraraj K, Lau CS, Lee I, Chamberlain RS. Trends in incidence, survival, and management of uveal melanoma: a population-based study of 7,516 patients from the Surveillance, Epidemiology, and End Results database (1973-2012). Clin Ophthalmol 2016;10:2113–2119. Available at: https://www.ncbi.nlm.nih.gov/pubmed/27822007.

3. Steckler AM, Francis JH, Shoushtari AN, et al. Uveal melanoma metastatic at initial diagnosis: a case series. Melanoma Res 2022;32:120–123. Available at: https://www.ncbi.nlm.nih.gov/pubmed/35152255.

4. Shields CL, Kaliki S, Furuta M, et al. American joint committee on cancer classification of uveal melanoma (anatomic stage) predicts prognosis in 7,731 patients: The 2013 zimmerman lecture. Ophthalmology 2015;122:1180–1186. Available at: https://www.ncbi.nlm.nih.gov/pubmed/25813452.

5. Force AOOT. International validation of the American joint committee on cancer's 7th edition classification of uveal melanoma. JAMA Ophthalmol 2015;133:376–383. Available at: https://www.ncbi.nlm.nih.gov/pubmed/25555246.

6. Chang AE, Karnell LH, Menck HR. The national cancer data base report on cutaneous and noncutaneous melanoma: A summary of 84,836 cases from the past decade. The american college of surgeons commission on cancer and the american cancer society. Cancer 1998;83:1664–1678. Available at: https://www.ncbi.nlm.nih.gov/pubmed/9781962.

7. Kujala E, Damato B, Coupland SE, et al. Staging of ciliary body and choroidal melanomas based on anatomic extent. J Clin Oncol 2013;31:2825–2831. Available at: https://www.ncbi.nlm.nih.gov/pubmed/23816968.

8. Lorenzo D, Ochoa M, Piulats JM, et al. Prognostic factors and decision tree for long-term survival in metastatic uveal melanoma. Cancer Res Treat 2018;50:1130–1139. Available at: https://www.ncbi.nlm.nih.gov/pubmed/29198096.

9. Kolandjian NA, Wei C, Patel SP, et al. Delayed systemic recurrence of uveal melanoma. Am J Clin Oncol 2013;36:443–449. Available at: https://www.ncbi.nlm.nih.gov/pubmed/22706174.

10. Rietschel P, Panageas KS, Hanlon C, et al. Variates of survival in metastatic uveal melanoma. J Clin Oncol 2005;23:8076–8080. Available at: https://www.ncbi.nlm.nih.gov/pubmed/16258106.

11. Khoja L, Atenafu EG, Suciu S, et al. Meta-analysis in metastatic uveal melanoma to determine progression free and overall survival benchmarks: an international rare cancers initiative (IRCI) ocular melanoma study. Ann Oncol 2019;30:1370–1380. Available at: https://www.ncbi.nlm.nih.gov/pubmed/31150059.

12. Lane AM, Kim IK, Gragoudas ES. Survival rates in patients after treatment for metastasis from uveal melanoma. JAMA Ophthalmol 2018;136:981–986. Available at: https://www.ncbi.nlm.nih.gov/pubmed/29955797.

13. Shields CL, Say EAT, Hasanreisoglu M, et al. Personalized prognosis of uveal melanoma based on cytogenetic profile in 1059 patients over an 8-year period: The 2017 Harry S. Gradle lecture. Ophthalmology 2017;124:1523–1531. Available at: https://www.ncbi.nlm.nih.gov/pubmed/28495150.

14. Shields CL, Furuta M, Thangappan A, et al. Metastasis of uveal melanoma millimeter-by-millimeter in 8033 consecutive eyes. Arch Ophthalmol 2009;127:989–998. Available at: https://www.ncbi.nlm.nih.gov/pubmed/19667335.

Discussion update in progress

Version 1.2026 © 2026 National Comprehensive Cancer Network© (NCCN©), All rights reserved. NCCN Guidelines® and this illustration may not be reproduced in any form without the express written permission of NCCN.

PLEASE NOTE that use of this NCCN Content is governed by the End-User License Agreement, and you MAY NOT distribute this Content or use it with any artificial intelligence model or tool.
Printed by Galya Basol Kochav on 2/13/2026 11:27:31 AM. Copyright © 2026 National Comprehensive Cancer Network, Inc. All Rights Reserved.

15. Shields CL, Shields JA, Materin M, et al. Iris melanoma: risk factors for metastasis in 169 consecutive patients. Ophthalmology 2001;108:172–178. Available at: https://www.ncbi.nlm.nih.gov/pubmed/11150284.

16. Geisse LJ, Robertson DM. Iris melanomas. Am J Ophthalmol 1985;99:638–648. Available at: https://www.ncbi.nlm.nih.gov/pubmed/4014387.

17. Khan S, Finger PT, Yu GP, et al. Clinical and pathologic characteristics of biopsy-proven iris melanoma: a multicenter international study. Arch Ophthalmol 2012;130:57–64. Available at: https://www.ncbi.nlm.nih.gov/pubmed/21911649.

18. Shields CL, Di Nicola M, Bekerman VP, et al. Iris melanoma outcomes based on the American joint committee on cancer classification (eighth edition) in 432 patients. Ophthalmology 2018;125:913–923. Available at: https://www.ncbi.nlm.nih.gov/pubmed/29342436.

19. Isager P, Engholm G, Overgaard J, Storm H. Uveal and conjunctival malignant melanoma in denmark 1943-97: observed and relative survival of patients followed through 2002. Ophthalmic Epidemiol 2006;13:85–96. Available at: https://www.ncbi.nlm.nih.gov/pubmed/16581612.

20. Amin MB, Edge S, Greene F, et al., eds. AJCC Cancer Staging Manual (ed 8th). New York: Springer International Publishing; 2017.

21. Henriquez F, Janssen C, Kemp EG, Roberts F. The T1799A BRAF mutation is present in iris melanoma. Invest Ophthalmol Vis Sci 2007;48:4897–4900. Available at: https://www.ncbi.nlm.nih.gov/pubmed/17962436.

22. van Poppelen NM, Vaarwater J, Mudhar HS, et al. Genetic background of iris melanomas and iris melanocytic tumors of uncertain malignant potential. Ophthalmology 2018;125:904–912. Available at: https://www.ncbi.nlm.nih.gov/pubmed/29371009.

23. de Lange MJ, Razzaq L, Versluis M, et al. Distribution of GNAQ and GNA11 mutation signatures in uveal melanoma points to a light dependent mutation mechanism. PLoS One 2015;10:e0138002. Available at: https://www.ncbi.nlm.nih.gov/pubmed/26368812.

24. Onken MD, Worley LA, Long MD, et al. Oncogenic mutations in GNAQ occur early in uveal melanoma. Invest Ophthalmol Vis Sci 2008;49:5230–5234. Available at: https://www.ncbi.nlm.nih.gov/pubmed/18719078.

25. Ewens KG, Kanetsky PA, Richards-Yutz J, et al. Chromosome 3 status combined with BAP1 and EIF1AX mutation profiles are associated with metastasis in uveal melanoma. Invest Ophthalmol Vis Sci 2014;55:5160–5167. Available at: https://www.ncbi.nlm.nih.gov/pubmed/24970262.

26. Singh AD. Small incision guarded hydroaspiration of iris lesions. Br J Ophthalmol 2017;101:1570–1575. Available at: https://www.ncbi.nlm.nih.gov/pubmed/28292778.

27. Klauber S, Jensen PK, Prause JU, Kessing SV. Surgical treatment of iris and ciliary body melanoma: follow-up of a 25-year series of patients. Acta Ophthalmol 2012;90:122–126. Available at: https://www.ncbi.nlm.nih.gov/pubmed/20456258.

28. Kaliki S, Shields CL. Uveal melanoma: relatively rare but deadly cancer. Eye (Lond) 2017;31:241–257. Available at: https://www.ncbi.nlm.nih.gov/pubmed/27911450.

29. Riechardt AI, Karle B, Cordini D, et al. Proton therapy of iris melanoma with 50 CGE : Influence of target volume on clinical outcome. Strahlenther Onkol 2017;193:943–950. Available at: https://www.ncbi.nlm.nih.gov/pubmed/28631017.

30. Boyd SR, Gittos A, Richter M, et al. Proton beam therapy and iris neovascularisation in uveal melanoma. Eye (Lond) 2006;20:832–836. Available at: https://www.ncbi.nlm.nih.gov/pubmed/16167079.

31. Detorakis ET, Engstrom RE, Jr., Wallace R, Straatsma BR. Iris and anterior chamber angle neovascularization after iodine 125 brachytherapy for uveal melanoma. Ophthalmology 2005;112:505–510. Available at: https://www.ncbi.nlm.nih.gov/pubmed/15745782.

Discussion update in progress

Version 1.2026 © 2026 National Comprehensive Cancer Network© (NCCN©), All rights reserved. NCCN Guidelines® and this illustration may not be reproduced in any form without the express written permission of NCCN.

PLEASE NOTE that use of this NCCN Content is governed by the End-User License Agreement, and you MAY NOT distribute this Content or use it with any artificial intelligence model or tool.
Printed by Galya Basol Kochav on 2/13/2026 11:27:31 AM. Copyright © 2026 National Comprehensive Cancer Network, Inc. All Rights Reserved.

32. The collaborative ocular melanoma study (COMS) randomized trial of pre-enucleation radiation of large choroidal melanoma I: characteristics of patients enrolled and not enrolled. COMS report no. 9. Am J Ophthalmol 1998;125:767–778. Available at: https://www.ncbi.nlm.nih.gov/pubmed/9645715.

33. Mishra KK, Quivey JM, Daftari IK, et al. Long-term results of the UCSF-LBNL randomized trial: Charged particle with helium ion versus iodine-125 plaque therapy for choroidal and ciliary body melanoma. Int J Radiat Oncol Biol Phys 2015;92:376–383. Available at: https://www.ncbi.nlm.nih.gov/pubmed/25841624.

34. Onken MD, Worley LA, Char DH, et al. Collaborative ocular oncology group report number 1: prospective validation of a multi-gene prognostic assay in uveal melanoma. Ophthalmology 2012;119:1596–1603. Available at: https://www.ncbi.nlm.nih.gov/pubmed/22521086.

35. Van Raamsdonk CD, Bezrookove V, Green G, et al. Frequent somatic mutations of GNAQ in uveal melanoma and blue naevi. Nature 2009;457:599–602. Available at: https://www.ncbi.nlm.nih.gov/pubmed/19078957.

36. Zuidervaart W, van Nieuwpoort F, Stark M, et al. Activation of the MAPK pathway is a common event in uveal melanomas although it rarely occurs through mutation of BRAF or RAS. Br J Cancer 2005;92:2032–2038. Available at: https://www.ncbi.nlm.nih.gov/pubmed/15928660.

37. Gear H, Williams H, Kemp EG, Roberts F. BRAF mutations in conjunctival melanoma. Invest Ophthalmol Vis Sci 2004;45:2484–2488. Available at: https://www.ncbi.nlm.nih.gov/pubmed/15277467.

38. Lake SL, Jmor F, Dopierala J, et al. Multiplex ligation-dependent probe amplification of conjunctival melanoma reveals common BRAF V600E gene mutation and gene copy number changes. Invest Ophthalmol Vis Sci 2011;52:5598–5604. Available at: https://www.ncbi.nlm.nih.gov/pubmed/21693616.

39. Griewank KG, Westekemper H, Murali R, et al. Conjunctival melanomas harbor BRAF and NRAS mutations and copy number changes similar to cutaneous and mucosal melanomas. Clin Cancer Res 2013;19:3143–3152. Available at: https://www.ncbi.nlm.nih.gov/pubmed/23633454.

40. Larsen AC, Dahmcke CM, Dahl C, et al. A retrospective review of conjunctival melanoma presentation, treatment, and outcome and an investigation of features associated with BRAF mutations. JAMA Ophthalmol 2015;133:1295–1303. Available at: https://www.ncbi.nlm.nih.gov/pubmed/26425792.

41. Beadling C, Jacobson-Dunlop E, Hodi FS, et al. KIT gene mutations and copy number in melanoma subtypes. Clin Cancer Res 2008;14:6821–6828. Available at: https://www.ncbi.nlm.nih.gov/pubmed/18980976.

42. Spendlove HE, Damato BE, Humphreys J, et al. BRAF mutations are detectable in conjunctival but not uveal melanomas. Melanoma Res 2004;14:449–452. Available at: https://www.ncbi.nlm.nih.gov/pubmed/15577314.

43. Damato B, Dopierala JA, Coupland SE. Genotypic profiling of 452 choroidal melanomas with multiplex ligation-dependent probe amplification. Clin Cancer Res 2010;16:6083–6092. Available at: https://www.ncbi.nlm.nih.gov/pubmed/20975103.

44. Bagger M, Andersen MT, Andersen KK, et al. The prognostic effect of American joint committee on cancer staging and genetic status in patients with choroidal and ciliary body melanoma. Invest Ophthalmol Vis Sci 2014;56:438–444. Available at: https://www.ncbi.nlm.nih.gov/pubmed/25537201.

45. Cassoux N, Rodrigues MJ, Plancher C, et al. Genome-wide profiling is a clinically relevant and affordable prognostic test in posterior uveal melanoma. Br J Ophthalmol 2014;98:769–774. Available at: https://www.ncbi.nlm.nih.gov/pubmed/24169649.

46. Caines R, Eleuteri A, Kalirai H, et al. Cluster analysis of multiplex ligation-dependent probe amplification data in choroidal melanoma. Mol Vis 2015;21:1–11. Available at: https://www.ncbi.nlm.nih.gov/pubmed/25684974.

Discussion update in progress

Version 1.2026 © 2026 National Comprehensive Cancer Network© (NCCN©), All rights reserved. NCCN Guidelines® and this illustration may not be reproduced in any form without the express written permission of NCCN.

PLEASE NOTE that use of this NCCN Content is governed by the End-User License Agreement, and you MAY NOT distribute this Content or use it with any artificial intelligence model or tool.
Printed by Galya Basol Kochav on 2/13/2026 11:27:31 AM. Copyright © 2026 National Comprehensive Cancer Network, Inc. All Rights Reserved.

47. Van Raamsdonk CD, Griewank KG, Crosby MB, et al. Mutations in GNA11 in uveal melanoma. N Engl J Med 2010;363:2191–2199. Available at: https://www.ncbi.nlm.nih.gov/pubmed/21083380.

48. Daniels AB, Lee JE, MacConaill LE, et al. High throughput mass spectrometry-based mutation profiling of primary uveal melanoma. Invest Ophthalmol Vis Sci 2012;53:6991–6996. Available at: https://www.ncbi.nlm.nih.gov/pubmed/22977135.

49. Harbour JW, Onken MD, Roberson ED, et al. Frequent mutation of BAP1 in metastasizing uveal melanomas. Science 2010;330:1410–1413. Available at: https://www.ncbi.nlm.nih.gov/pubmed/21051595.

50. Gupta MP, Lane AM, DeAngelis MM, et al. Clinical characteristics of uveal melanoma in patients with germline BAP1 mutations. JAMA Ophthalmol 2015;133:881–887. Available at: https://www.ncbi.nlm.nih.gov/pubmed/25974357.

51. Harbour JW, Roberson ED, Anbunathan H, et al. Recurrent mutations at codon 625 of the splicing factor SF3B1 in uveal melanoma. Nat Genet 2013;45:133–135. Available at: https://www.ncbi.nlm.nih.gov/pubmed/23313955.

52. Martin M, Masshofer L, Temming P, et al. Exome sequencing identifies recurrent somatic mutations in EIF1AX and SF3B1 in uveal melanoma with disomy 3. Nat Genet 2013;45:933–936. Available at: https://www.ncbi.nlm.nih.gov/pubmed/23793026.

53. PubMed Overview. Available at: https://pubmed.ncbi.nlm.nih.gov/about/.

54. Freedman-Cass DA, Fischer T, Alpert AB, et al. The value and process of inclusion: Using sensitive, respectful, and inclusive language and images in NCCN content. J Natl Compr Canc Netw 2023;21:434–441. Available at: https://www.ncbi.nlm.nih.gov/pubmed/37156485.

55. Qiu M, Shields CL. Choroidal nevus in the United States adult population: Racial disparities and associated factors in the national health and nutrition examination survey. Ophthalmology 2015;122:2071–2083. Available at: https://www.ncbi.nlm.nih.gov/pubmed/26255109.

56. Sumich P, Mitchell P, Wang JJ. Choroidal nevi in a white population: The blue mountains eye study. Arch Ophthalmol 1998;116:645–650. Available at: https://www.ncbi.nlm.nih.gov/pubmed/9596501.

57. Smith RE, Ganley JP. Ophthalmic survey of a community. 1. Abnormalities of the ocular fundus. Am J Ophthalmol 1972;74:1126–1130. Available at: https://www.ncbi.nlm.nih.gov/pubmed/4646717.

58. Eskelin S, Kivela T. Mode of presentation and time to treatment of uveal melanoma in Finland. Br J Ophthalmol 2002;86:333–338. Available at: https://www.ncbi.nlm.nih.gov/pubmed/11864894.

59. Shields CL, Pefkianaki M, Mashayekhi A, et al. Cytogenetic results of choroidal nevus growth into melanoma in 55 consecutive cases. Saudi J Ophthalmol 2018;32:28–32. Available at: https://www.ncbi.nlm.nih.gov/pubmed/29755268.

60. Kivela T. Diagnosis of uveal melanoma. Dev Ophthalmol 2012;49:1–15. Available at: https://www.ncbi.nlm.nih.gov/pubmed/22042009.

61. Factors predictive of growth and treatment of small choroidal melanoma: COMS Report No. 5. The Collaborative Ocular Melanoma Study Group. Arch Ophthalmol 1997;115:1537–1544. Available at: https://www.ncbi.nlm.nih.gov/pubmed/9400787.

62. Shields CL, Dalvin LA, Yu MD, et al. Choroidal nevus transformation into melanoma per millimeter increment in thickness using multimodal imaging in 2355 cases: The 2019 Wendell L. Hughes lecture. Retina 2019;39:1852–1860. Available at: https://www.ncbi.nlm.nih.gov/pubmed/30883534.

63. Shields CL, Dalvin LA, Ancona-Lezama D, et al. Choroidal nevus imaging features in 3,806 cases and risk factors for transformation into melanoma in 2,355 cases: The 2020 Taylor R. Smith and Victor T. Curtin lecture. Retina 2019;39:1840–1851. Available at: https://www.ncbi.nlm.nih.gov/pubmed/30608349.

Discussion update in progress

Version 1.2026 © 2026 National Comprehensive Cancer Network© (NCCN©), All rights reserved. NCCN Guidelines® and this illustration may not be reproduced in any form without the express written permission of NCCN.

PLEASE NOTE that use of this NCCN Content is governed by the End-User License Agreement, and you MAY NOT distribute this Content or use it with any artificial intelligence model or tool.
Printed by Galya Basol Kochav on 2/13/2026 11:27:31 AM. Copyright © 2026 National Comprehensive Cancer Network, Inc. All Rights Reserved.

64. Augsburger JJ, Correa ZM, Schneider S, et al. Diagnostic transvitreal fine-needle aspiration biopsy of small melanocytic choroidal tumors in nevus versus melanoma category. Trans Am Ophthalmol Soc 2002;100:225–232; discussion 232–224. Available at: https://www.ncbi.nlm.nih.gov/pubmed/12545696.

65. Augsburger JJ, Correa ZM, Trichopoulos N, Shaikh A. Size overlap between benign melanocytic choroidal nevi and choroidal malignant melanomas. Invest Ophthalmol Vis Sci 2008;49:2823–2828. Available at: https://www.ncbi.nlm.nih.gov/pubmed/18408179.

66. Shields CL, Shields JA, Kiratli H, et al. Risk factors for growth and metastasis of small choroidal melanocytic lesions. Ophthalmology 1995;102:1351–1361. Available at: https://www.ncbi.nlm.nih.gov/pubmed/9097773.

67. Shields CL, Cater J, Shields JA, et al. Combination of clinical factors predictive of growth of small choroidal melanocytic tumors. Arch Ophthalmol 2000;118:360–364. Available at: https://www.ncbi.nlm.nih.gov/pubmed/10721958.

68. Singh AD, Mokashi AA, Bena JF, et al. Small choroidal melanocytic lesions: features predictive of growth. Ophthalmology 2006;113:1032–1039. Available at: https://www.ncbi.nlm.nih.gov/pubmed/16650475.

69. Shields CL, Furuta M, Berman EL, et al. Choroidal nevus transformation into melanoma: analysis of 2514 consecutive cases. Arch Ophthalmol 2009;127:981–987. Available at: https://www.ncbi.nlm.nih.gov/pubmed/19667334.

70. Lane AM, Egan KM, Kim IK, Gragoudas ES. Mortality after diagnosis of small melanocytic lesions of the choroid. Arch Ophthalmol 2010;128:996–1000. Available at: https://www.ncbi.nlm.nih.gov/pubmed/20696999.

71. Butler P, Char DH, Zarbin M, Kroll S. Natural history of indeterminate pigmented choroidal tumors. Ophthalmology 1994;101:710–716; discussion 717. Available at: https://www.ncbi.nlm.nih.gov/pubmed/8152767.

72. Dalvin LA, Shields CL, Ancona-Lezama DA, et al. Combination of multimodal imaging features predictive of choroidal nevus transformation into melanoma. Br J Ophthalmol 2019;103:1441–1447. Available at: https://www.ncbi.nlm.nih.gov/pubmed/30523045.

73. Mims JL, 3rd, Shields JA. Follow-up studies of suspicious choroidal nevi. Ophthalmology 1978;85:929–943. Available at: https://www.ncbi.nlm.nih.gov/pubmed/733186.

74. MacIlwaine WAt, Anderson B, Jr., Klintworth GK. Enlargement of a histologically documented choroidal nevus. Am J Ophthalmol 1979;87:480–486. Available at: https://www.ncbi.nlm.nih.gov/pubmed/443311.

75. Mashayekhi A, Siu S, Shields CL, Shields JA. Slow enlargement of choroidal nevi: a long-term follow-up study. Ophthalmology 2011;118:382–388. Available at: https://www.ncbi.nlm.nih.gov/pubmed/20801518.

76. Fontcuberta IC, Salomao DR, Quiram PA, Pulido JS. Choroidal melanoma and lid fibrofoliculomas in Birt-Hogg-Dube syndrome. Ophthalmic Genet 2011;32:143–146. Available at: https://www.ncbi.nlm.nih.gov/pubmed/21401403.

77. Marous CL, Marous MR, Welch RJ, et al. Choroidal melanoma, sector melanocytosis, and retinal pigment epithelial microdetachments in Birt-Hogg-Dube syndrome. Retin Cases Brief Rep 2019;13:202–206. Available at: https://www.ncbi.nlm.nih.gov/pubmed/28541267.

78. Dalvin LA, Shields CL, Pulido JS, et al. Uveal melanoma associated with myotonic dystrophy: A report of 6 cases. JAMA Ophthalmol 2018;136:543–547. Available at: https://www.ncbi.nlm.nih.gov/pubmed/29596556.

79. Velazquez-Martin JP, Pavlin CJ, Simpson ER. Association between uveal melanoma and myotonic dystrophy: a series of 3 cases. JAMA Ophthalmol 2013;131:246–249. Available at: https://www.ncbi.nlm.nih.gov/pubmed/23411896.

Discussion update in progress

Version 1.2026 © 2026 National Comprehensive Cancer Network© (NCCN©), All rights reserved. NCCN Guidelines® and this illustration may not be reproduced in any form without the express written permission of NCCN.

PLEASE NOTE that use of this NCCN Content is governed by the End-User License Agreement, and you MAY NOT distribute this Content or use it with any artificial intelligence model or tool.
Printed by Galya Basol Kochav on 2/13/2026 11:27:31 AM. Copyright © 2026 National Comprehensive Cancer Network, Inc. All Rights Reserved.

80. Win AK, Perattur PG, Pulido JS, et al. Increased cancer risks in myotonic dystrophy. Mayo Clin Proc 2012;87:130–135. Available at: https://www.ncbi.nlm.nih.gov/pubmed/22237010.

81. Spees EK, Jr., Kramer KK, Light JA, et al. Reactivation of ocular malignant melanoma after renal transplantation. Transplantation 1980;29:421–424. Available at: https://www.ncbi.nlm.nih.gov/pubmed/6990569.

82. Shields JA, Narsipur SS, Shields CL, Sperber DE. Choroidal melanoma in an immunosuppressed child with minimal change nephrotic syndrome. Retina 2004;24:454–455. Available at: https://www.ncbi.nlm.nih.gov/pubmed/15187671.

83. Singh AD, De Potter P, Fijal BA, et al. Lifetime prevalence of uveal melanoma in white patients with oculo(dermal) melanocytosis. Ophthalmology 1998;105:195–198. Available at: https://www.ncbi.nlm.nih.gov/pubmed/9442799.

84. Gonder JR, Shields JA, Albert DM, et al. Uveal malignant melanoma associated with ocular and oculodermal melanocytosis. Ophthalmology 1982;89:953–960. Available at: https://www.ncbi.nlm.nih.gov/pubmed/7133641.

85. Singh AD, Shields CL, Shields JA, Sato T. Uveal melanoma in young patients. Arch Ophthalmol 2000;118:918–923. Available at: https://www.ncbi.nlm.nih.gov/pubmed/10900104.

86. Velazquez N, Jones IS. Ocular and oculodermal melanocytosis associated with uveal melanoma. Ophthalmology 1983;90:1472–1476. Available at: https://www.ncbi.nlm.nih.gov/pubmed/6677847.

87. Gonder JR, Ezell PC, Shields JA, Augsburger JJ. Ocular melanocytosis. A study to determine the prevalence rate of ocular melanocytosis. Ophthalmology 1982;89:950–952. Available at: https://www.ncbi.nlm.nih.gov/pubmed/7133640.

88. Shields CL, Kaliki S, Livesey M, et al. Association of ocular and oculodermal melanocytosis with the rate of uveal melanoma metastasis: analysis of 7872 consecutive eyes. JAMA Ophthalmol 2013;131:993–1003. Available at: https://www.ncbi.nlm.nih.gov/pubmed/23681424.

89. Singh AD, Shields CL, De Potter P, et al. Familial uveal melanoma. Clinical observations on 56 patients. Arch Ophthalmol 1996;114:392–399. Available at: https://www.ncbi.nlm.nih.gov/pubmed/8602775.

90. Abdel-Rahman MH, Pilarski R, Ezzat S, et al. Cancer family history characterization in an unselected cohort of 121 patients with uveal melanoma. Fam Cancer 2010;9:431–438. Available at: https://www.ncbi.nlm.nih.gov/pubmed/20157784.

91. Singh AD, Wang MX, Donoso LA, et al. Familial uveal melanoma, III. Is the occurrence of familial uveal melanoma coincidental? Arch Ophthalmol 1996;114:1101–1104. Available at: https://www.ncbi.nlm.nih.gov/pubmed/8790096.

92. Nielsen M, Dogrusoz M, Bleeker JC, et al. The genetic basis of uveal melanoma. J Fr Ophtalmol 2015;38:516–521. Available at: https://www.ncbi.nlm.nih.gov/pubmed/25976137.

93. Helgadottir H, Hoiom V. The genetics of uveal melanoma: current insights. Appl Clin Genet 2016;9:147–155. Available at: https://www.ncbi.nlm.nih.gov/pubmed/27660484.

94. Masoomian B, Shields JA, Shields CL. Overview of BAP1 cancer predisposition syndrome and the relationship to uveal melanoma. J Curr Ophthalmol 2018;30:102–109. Available at: https://www.ncbi.nlm.nih.gov/pubmed/29988936.

95. Carbone M, Ferris LK, Baumann F, et al. BAP1 cancer syndrome: malignant mesothelioma, uveal and cutaneous melanoma, and MBAITs. J Transl Med 2012;10:179. Available at: https://www.ncbi.nlm.nih.gov/pubmed/22935333.

96. Foretova L, Navratilova M, Svoboda M, et al. BAP1 syndrome - predisposition to malignant mesothelioma, skin and uveal melanoma, renal and other cancers. Klin Onkol 2019;32:118–122. Available at: https://www.ncbi.nlm.nih.gov/pubmed/31409087.

Discussion update in progress

Version 1.2026 © 2026 National Comprehensive Cancer Network© (NCCN©), All rights reserved. NCCN Guidelines® and this illustration may not be reproduced in any form without the express written permission of NCCN.

PLEASE NOTE that use of this NCCN Content is governed by the End-User License Agreement, and you MAY NOT distribute this Content or use it with any artificial intelligence model or tool.
Printed by Galya Basol Kochav on 2/13/2026 11:27:31 AM. Copyright © 2026 National Comprehensive Cancer Network, Inc. All Rights Reserved.

97. Boru G, Grosel TW, Pilarski R, et al. Germline large deletion of BAP1 and decreased expression in non-tumor choroid in uveal melanoma patients with high risk for inherited cancer. Genes Chromosomes Cancer 2019;58:650–656. Available at: https://www.ncbi.nlm.nih.gov/pubmed/30883995.

98. Walpole S, Pritchard AL, Cebulla CM, et al. Comprehensive study of the clinical phenotype of germline BAP1 variant-carrying families worldwide. J Natl Cancer Inst 2018;110:1328–1341. Available at: https://www.ncbi.nlm.nih.gov/pubmed/30517737.

99. Pilarski R, Byrne L, Carlo MI, et al. BAP1 tumor predisposition syndrome. In: Adam MP, Feldman J, Mirzaa GM, et al., eds. GeneReviews((R)). Seattle (WA); 1993.

100. Haugh AM, Njauw CN, Bubley JA, et al. Genotypic and phenotypic features of BAP1 cancer syndrome: A report of 8 new families and review of cases in the literature. JAMA Dermatol 2017;153:999–1006. Available at: https://www.ncbi.nlm.nih.gov/pubmed/28793149.

101. Wang A, Papneja A, Hyrcza M, et al. Gene of the month: BAP1. J Clin Pathol 2016;69:750–753. Available at: https://www.ncbi.nlm.nih.gov/pubmed/27235536.

102. Rai K, Pilarski R, Cebulla CM, Abdel-Rahman MH. Comprehensive review of BAP1 tumor predisposition syndrome with report of two new cases. Clin Genet 2016;89:285–294. Available at: https://www.ncbi.nlm.nih.gov/pubmed/26096145.

103. Carbone M, Flores EG, Emi M, et al. Combined genetic and genealogic studies uncover a large BAP1 cancer syndrome kindred tracing back nine generations to a common ancestor from the 1700s. PLoS Genet 2015;11:e1005633. Available at: https://www.ncbi.nlm.nih.gov/pubmed/26683624.

104. Njauw CN, Kim I, Piris A, et al. Germline BAP1 inactivation is preferentially associated with metastatic ocular melanoma and cutaneous-ocular melanoma families. PLoS One 2012;7:e35295. Available at: https://www.ncbi.nlm.nih.gov/pubmed/22545102.

105. Testa JR, Cheung M, Pei J, et al. Germline BAP1 mutations predispose to malignant mesothelioma. Nat Genet 2011;43:1022–1025. Available at: https://www.ncbi.nlm.nih.gov/pubmed/21874000.

106. Abdel-Rahman MH, Sample KM, Pilarski R, et al. Whole exome sequencing identifies candidate genes associated with hereditary predisposition to uveal melanoma. Ophthalmology 2020;127:668–678. Available at: https://www.ncbi.nlm.nih.gov/pubmed/32081490.

107. Derrien AC, Rodrigues M, Eeckhoutte A, et al. Germline MBD4 mutations and predisposition to uveal melanoma. J Natl Cancer Inst 2021;113:80–87. Available at: https://www.ncbi.nlm.nih.gov/pubmed/32239153.

108. Rodrigues M, Mobuchon L, Houy A, et al. Evolutionary routes in metastatic uveal melanomas depend on MBD4 alterations. Clin Cancer Res 2019;25:5513–5524. Available at: https://www.ncbi.nlm.nih.gov/pubmed/31227496.

109. Repo P, Jantti JE, Jarvinen RS, et al. Germline loss-of-function variants in MBD4 are rare in Finnish patients with uveal melanoma. Pigment Cell Melanoma Res 2020;33:756–762. Available at: https://www.ncbi.nlm.nih.gov/pubmed/32421892.

110. Rodrigues M, Mobuchon L, Houy A, et al. Outlier response to anti-PD1 in uveal melanoma reveals germline MBD4 mutations in hypermutated tumors. Nat Commun 2018;9:1866. Available at: https://www.ncbi.nlm.nih.gov/pubmed/29760383.

111. Nayman T, Bostan C, Logan P, Burnier MN, Jr. Uveal melanoma risk factors: A systematic review of meta-analyses. Curr Eye Res 2017;42:1085–1093. Available at: https://www.ncbi.nlm.nih.gov/pubmed/28494168.

112. Seddon JM, Gragoudas ES, Glynn RJ, et al. Host factors, UV radiation, and risk of uveal melanoma. A case-control study. Arch Ophthalmol 1990;108:1274–1280. Available at: https://www.ncbi.nlm.nih.gov/pubmed/2400347.

Discussion update in progress

Version 1.2026 © 2026 National Comprehensive Cancer Network© (NCCN©), All rights reserved. NCCN Guidelines® and this illustration may not be reproduced in any form without the express written permission of NCCN.

PLEASE NOTE that use of this NCCN Content is governed by the End-User License Agreement, and you MAY NOT distribute this Content or use it with any artificial intelligence model or tool.
Printed by Galya Basol Kochav on 2/13/2026 11:27:31 AM. Copyright © 2026 National Comprehensive Cancer Network, Inc. All Rights Reserved.

113. Houtzagers LE, Wierenga APA, Ruys AAM, et al. Iris colour and the risk of developing uveal melanoma. Int J Mol Sci 2020;21. Available at: https://www.ncbi.nlm.nih.gov/pubmed/32998469.

114. Zhang H, Liu Y, Zhang K, et al. Validation of the relationship between iris color and uveal melanoma using artificial intelligence with multiple paths in a large chinese population. Front Cell Dev Biol 2021;9:713209. Available at: https://www.ncbi.nlm.nih.gov/pubmed/34490264.

115. Falcone LM, Zeidler-Erdely PC. Skin cancer and welding. Clin Exp Dermatol 2019;44:130–134. Available at: https://www.ncbi.nlm.nih.gov/pubmed/30280417.

116. Bataille V, Pinney E, Hungerford JL, et al. Five cases of coexistent primary ocular and cutaneous melanoma. Arch Dermatol 1993;129:198–201. Available at: https://www.ncbi.nlm.nih.gov/pubmed/8434978.

117. Bataille V, Sasieni P, Cuzick J, et al. Risk of ocular melanoma in relation to cutaneous and iris naevi. Int J Cancer 1995;60:622–626. Available at: https://www.ncbi.nlm.nih.gov/pubmed/7860135.

118. van Hees CL, Jager MJ, Bleeker JC, et al. Occurrence of cutaneous and uveal melanoma in patients with uveal melanoma and their first degree relatives. Melanoma Res 1998;8:175–180. Available at: https://www.ncbi.nlm.nih.gov/pubmed/9610873.

119. Richtig E, Langmann G, Mullner K, Smolle J. Ocular melanoma: epidemiology, clinical presentation and relationship with dysplastic nevi. Ophthalmologica 2004;218:111–114. Available at: https://www.ncbi.nlm.nih.gov/pubmed/15004500.

120. Lischko AM, Seddon JM, Gragoudas ES, et al. Evaluation of prior primary malignancy as a determinant of uveal melanoma. A case-control study. Ophthalmology 1989;96:1716–1721. Available at: https://www.ncbi.nlm.nih.gov/pubmed/2622616.

121. Shors AR, Iwamoto S, Doody DR, Weiss NS. Relationship of uveal and cutaneous malignant melanoma in persons with multiple primary tumors. Int J Cancer 2002;102:266–268. Available at: https://www.ncbi.nlm.nih.gov/pubmed/12397648.

122. Hemminki K, Zhang H, Czene K. Association of first ocular melanoma with subsequent cutaneous melanoma: results from the Swedish Family-Cancer Database. Int J Cancer 2003;104:257–258. Available at: https://www.ncbi.nlm.nih.gov/pubmed/12569585.

123. Scelo G, Boffetta P, Autier P, et al. Associations between ocular melanoma and other primary cancers: an international population-based study. Int J Cancer 2007;120:152–159. Available at: https://www.ncbi.nlm.nih.gov/pubmed/17036322.

124. Bergman L, Nilsson B, Ragnarsson-Olding B, Seregard S. Uveal melanoma: a study on incidence of additional cancers in the Swedish population. Invest Ophthalmol Vis Sci 2006;47:72–77. Available at: https://www.ncbi.nlm.nih.gov/pubmed/16384946.

125. Spanogle JP, Clarke CA, Aroner S, Swetter SM. Risk of second primary malignancies following cutaneous melanoma diagnosis: a population-based study. J Am Acad Dermatol 2010;62:757–767. Available at: https://www.ncbi.nlm.nih.gov/pubmed/20223559.

126. Lains I, Bartosch C, Mondim V, et al. Second primary neoplasms in patients with uveal melanoma: A SEER database analysis. Am J Ophthalmol 2016;165:54–64. Available at: https://www.ncbi.nlm.nih.gov/pubmed/26940164.

127. Swerdlow AJ, Storm HH, Sasieni PD. Risks of second primary malignancy in patients with cutaneous and ocular melanoma in Denmark, 1943-1989. Int J Cancer 1995;61:773–779. Available at: https://www.ncbi.nlm.nih.gov/pubmed/7790110.

128. Vidal JL, Bacin F, Albuisson E, et al. ["Melanoma 92". epidemiological study of uveal melanoma in France]. J Fr Ophtalmol 1995;18:520–528. Available at: https://www.ncbi.nlm.nih.gov/pubmed/7560797.

Discussion update in progress

Version 1.2026 © 2026 National Comprehensive Cancer Network© (NCCN©), All rights reserved. NCCN Guidelines® and this illustration may not be reproduced in any form without the express written permission of NCCN.

PLEASE NOTE that use of this NCCN Content is governed by the End-User License Agreement, and you MAY NOT distribute this Content or use it with any artificial intelligence model or tool.
Printed by Galya Basol Kochav on 2/13/2026 11:27:31 AM. Copyright © 2026 National Comprehensive Cancer Network, Inc. All Rights Reserved.

129. Shields CL, Kaliki S, Furuta M, et al. Clinical spectrum and prognosis of uveal melanoma based on age at presentation in 8,033 cases. Retina 2012;32:1363–1372. Available at: https://www.ncbi.nlm.nih.gov/pubmed/22466491.

130. Damato B. Detection of uveal melanoma by optometrists in the United Kingdom. Ophthalmic Physiol Opt 2001;21:268–271. Available at: https://www.ncbi.nlm.nih.gov/pubmed/11430620.

131. Damato EM, Damato BE. Detection and time to treatment of uveal melanoma in the United Kingdom: an evaluation of 2,384 patients. Ophthalmology 2012;119:1582–1589. Available at: https://www.ncbi.nlm.nih.gov/pubmed/22503229.

132. Ah-Fat FG, Damato BE. Delays in the diagnosis of uveal melanoma and effect on treatment. Eye (Lond) 1998;12 (Pt 5):781–782. Available at: https://www.ncbi.nlm.nih.gov/pubmed/10070508.

133. Accuracy of diagnosis of choroidal melanomas in the Collaborative Ocular Melanoma Study. COMS report no. 1. Arch Ophthalmol 1990;108:1268–1273. Available at: https://www.ncbi.nlm.nih.gov/pubmed/2205183.

134. Collaborative Ocular Melanoma Study G, Boldt HC, Byrne SF, et al. Baseline echographic characteristics of tumors in eyes of patients enrolled in the collaborative ocular melanoma study: COMS report no. 29. Ophthalmology 2008;115:1390–1397, 1397 e1391–1392. Available at: https://www.ncbi.nlm.nih.gov/pubmed/18267342.

135. Bove R, Char DH. Nondiagnosed uveal melanomas. Ophthalmology 2004;111:554–557. Available at: https://www.ncbi.nlm.nih.gov/pubmed/15019335.

136. Shields JA, Augsburger JJ, Brown GC, Stephens RF. The differential diagnosis of posterior uveal melanoma. Ophthalmology 1980;87:518–522. Available at: https://www.ncbi.nlm.nih.gov/pubmed/7413140.

137. Shields JA, Mashayekhi A, Ra S, Shields CL. Pseudomelanomas of the posterior uveal tract: the 2006 Taylor R. Smith Lecture. Retina 2005;25:767–771. Available at: https://www.ncbi.nlm.nih.gov/pubmed/16141866.

138. Ghassemi F, Bazvand F, Hosseini SS. Pseudomelanoma at a referral center in iran. J Ophthalmic Vis Res 2014;9:50–53. Available at: https://www.ncbi.nlm.nih.gov/pubmed/24982732.

139. Saari JM, Kivela T, Summanen P, et al. Digital imaging in differential diagnosis of small choroidal melanoma. Graefes Arch Clin Exp Ophthalmol 2006;244:1581–1590. Available at: https://www.ncbi.nlm.nih.gov/pubmed/16636839.

140. Grisanti S, Tura A. Uveal melanoma. In: Scott JF, Gerstenblith MR, eds. Noncutaneous Melanoma. Brisbane (AU): Codon Publications; 2018.

141. Jovanovic P, Mihajlovic M, Djordjevic-Jocic J, et al. Ocular melanoma: an overview of the current status. Int J Clin Exp Pathol 2013;6:1230–1244. Available at: https://www.ncbi.nlm.nih.gov/pubmed/23826405.

142. Damato B. Progress in the management of patients with uveal melanoma. The 2012 Ashton lecture. Eye (Lond) 2012;26:1157–1172. Available at: https://www.ncbi.nlm.nih.gov/pubmed/22744385.

143. Demirci H, Shields CL, Shields JA, et al. Ring melanoma of the ciliary body: report on twenty-three patients. Retina 2002;22:698–706; quiz 852–693. Available at: https://www.ncbi.nlm.nih.gov/pubmed/12476094.

144. Freedman MI, Folk JC. Metastatic tumors to the eye and orbit. Patient survival and clinical characteristics. Arch Ophthalmol 1987;105:1215–1219. Available at: https://www.ncbi.nlm.nih.gov/pubmed/3307718.

145. Shields CL, Shields JA, Gross NE, et al. Survey of 520 eyes with uveal metastases. Ophthalmology 1997;104:1265–1276. Available at: https://www.ncbi.nlm.nih.gov/pubmed/9261313.

146. Shields CL, Welch RJ, Malik K, et al. Uveal metastasis: Clinical features and survival outcome of 2214 tumors in 1111 patients based on

Discussion update in progress

Version 1.2026 © 2026 National Comprehensive Cancer Network© (NCCN©), All rights reserved. NCCN Guidelines® and this illustration may not be reproduced in any form without the express written permission of NCCN.

PLEASE NOTE that use of this NCCN Content is governed by the End-User License Agreement, and you MAY NOT distribute this Content or use it with any artificial intelligence model or tool.
Printed by Galya Basol Kochav on 2/13/2026 11:27:31 AM. Copyright © 2026 National Comprehensive Cancer Network, Inc. All Rights Reserved.

primary tumor origin. Middle East Afr J Ophthalmol 2018;25:81–90. Available at: https://www.ncbi.nlm.nih.gov/pubmed/30122853.

147. Tarlan B, Kiratli H. Uveal melanoma: Current trends in diagnosis and management. Turk J Ophthalmol 2016;46:123–137. Available at: https://www.ncbi.nlm.nih.gov/pubmed/27800275.

148. Nathan P, Cohen V, Coupland S, et al. Uveal melanoma UK national guidelines. Eur J Cancer 2015;51:2404–2412. Available at: https://www.ncbi.nlm.nih.gov/pubmed/26278648.

149. Muftuoglu IK, Gaber R, Bartsch DU, et al. Comparison of conventional color fundus photography and multicolor imaging in choroidal or retinal lesions. Graefes Arch Clin Exp Ophthalmol 2018;256:643–649. Available at: https://www.ncbi.nlm.nih.gov/pubmed/29492687.

150. Albertus DL, Schachar IH, Zahid S, et al. Autofluorescence quantification of benign and malignant choroidal nevomelanocytic tumors. JAMA Ophthalmol 2013;131:1004–1008. Available at: https://www.ncbi.nlm.nih.gov/pubmed/23787920.

151. Garcia MD, Salomao DR, Marmorstein AD, Pulido JS. Histopathologic findings in the areas of orange pigment overlying choroidal melanomas. Transl Vis Sci Technol 2016;5:4. Available at: https://www.ncbi.nlm.nih.gov/pubmed/27190699.

152. Meyer K, Augsburger JJ. Independent diagnostic value of fluorescein angiography in the evaluation of intraocular tumors. Graefes Arch Clin Exp Ophthalmol 1999;237:489–494. Available at: https://www.ncbi.nlm.nih.gov/pubmed/10379610.

153. Chattopadhyay C, Kim DW, Gombos DS, et al. Uveal melanoma: From diagnosis to treatment and the science in between. Cancer 2016;122:2299–2312. Available at: https://www.ncbi.nlm.nih.gov/pubmed/26991400.

154. Fuller DG, Snyder WB, Hutton WL, Vaiser A. Ultrasonographic features of choroidal malignant melanomas. Arch Ophthalmol 1979;97:1465–1472. Available at: https://www.ncbi.nlm.nih.gov/pubmed/464871.

155. Bedi DG, Gombos DS, Ng CS, Singh S. Sonography of the eye. AJR Am J Roentgenol 2006;187:1061–1072. Available at: https://www.ncbi.nlm.nih.gov/pubmed/16985158.

156. Delgado S, Rodriguez Reyes A, Mora Rios L, et al. Ultrasound, histopathological, and genetic features of uveal melanoma in a Mexican-Mestizo population. Arch Soc Esp Oftalmol (Engl Ed) 2018;93:15–21. Available at: https://www.ncbi.nlm.nih.gov/pubmed/28728954.

157. Collaborative Ocular Melanoma Study G. Comparison of clinical, echographic, and histopathological measurements from eyes with medium-sized choroidal melanoma in the collaborative ocular melanoma study: COMS report no. 21. Arch Ophthalmol 2003;121:1163–1171. Available at: https://www.ncbi.nlm.nih.gov/pubmed/12912695.

158. Yonekawa Y, Kim IK. Epidemiology and management of uveal melanoma. Hematol Oncol Clin North Am 2012;26:1169–1184. Available at: https://www.ncbi.nlm.nih.gov/pubmed/23116575.

159. Ossoinig KC. Standardized echography: basic principles, clinical applications, and results. Int Ophthalmol Clin 1979;19:127–210. Available at: https://www.ncbi.nlm.nih.gov/pubmed/395120.

160. Sobottka B, Schlote T, Krumpaszky HG, Kreissig I. Choroidal metastases and choroidal melanomas: comparison of ultrasonographic findings. Br J Ophthalmol 1998;82:159–161. Available at: https://www.ncbi.nlm.nih.gov/pubmed/9613382.

161. Materin MA, Raducu R, Bianciotto C, Shields CL. Fundus autofluorescence and optical coherence tomography findings in choroidal melanocytic lesions. Middle East Afr J Ophthalmol 2010;17:201–206. Available at: https://www.ncbi.nlm.nih.gov/pubmed/20844674.

162. Shields CL, Bianciotto C, Pirondini C, et al. Autofluorescence of choroidal melanoma in 51 cases. Br J Ophthalmol 2008;92:617–622. Available at: https://www.ncbi.nlm.nih.gov/pubmed/18441171.

Discussion update in progress

Version 1.2026 © 2026 National Comprehensive Cancer Network© (NCCN©), All rights reserved. NCCN Guidelines® and this illustration may not be reproduced in any form without the express written permission of NCCN.

PLEASE NOTE that use of this NCCN Content is governed by the End-User License Agreement, and you MAY NOT distribute this Content or use it with any artificial intelligence model or tool.
Printed by Galya Basol Kochav on 2/13/2026 11:27:31 AM. Copyright © 2026 National Comprehensive Cancer Network, Inc. All Rights Reserved.

163. Cennamo G, Romano MR, Velotti N, et al. Fundus autofluorescence of choroidal nevi and melanoma. Acta Ophthalmol 2018;96:e102–e104. Available at: https://www.ncbi.nlm.nih.gov/pubmed/28205424.

164. Gunduz K, Pulido JS, Bakri SJ, Petit-Fond E. Fundus autofluorescence in choroidal melanocytic lesions. Retina 2007;27:681–687. Available at: https://www.ncbi.nlm.nih.gov/pubmed/17621175.

165. Shields CL, Pirondini C, Bianciotto C, et al. Autofluorescence of choroidal nevus in 64 cases. Retina 2008;28:1035–1043. Available at: https://www.ncbi.nlm.nih.gov/pubmed/18779708.

166. Singh AD, Belfort RN, Sayanagi K, Kaiser PK. Fourier domain optical coherence tomographic and auto-fluorescence findings in indeterminate choroidal melanocytic lesions. Br J Ophthalmol 2010;94:474–478. Available at: https://www.ncbi.nlm.nih.gov/pubmed/19822920.

167. Salvanos P, Utheim TP, Moe MC, et al. Autofluorescence imaging in the differential diagnosis of optic disc melanocytoma. Acta Ophthalmol 2015;93:476–480. Available at: https://www.ncbi.nlm.nih.gov/pubmed/25923254.

168. Garcia-Arumi Fuste C, Peralta Iturburu F, Garcia-Arumi J. Is optical coherence tomography angiography helpful in the differential diagnosis of choroidal nevus versus melanoma? Eur J Ophthalmol 2020;30:723–729. Available at: https://www.ncbi.nlm.nih.gov/pubmed/31210061.

169. Shields CL, Kaliki S, Rojanaporn D, et al. Enhanced depth imaging optical coherence tomography of small choroidal melanoma: comparison with choroidal nevus. Arch Ophthalmol 2012;130:850–856. Available at: https://www.ncbi.nlm.nih.gov/pubmed/22776921.

170. Filloy A, Caminal JM, Arias L, et al. Swept source optical coherence tomography imaging of a series of choroidal tumours. Can J Ophthalmol 2015;50:242–248. Available at: https://www.ncbi.nlm.nih.gov/pubmed/26040226.

171. Espinoza G, Rosenblatt B, Harbour JW. Optical coherence tomography in the evaluation of retinal changes associated with suspicious choroidal melanocytic tumors. Am J Ophthalmol 2004;137:90–95. Available at: https://www.ncbi.nlm.nih.gov/pubmed/14700649.

172. Sayanagi K, Pelayes DE, Kaiser PK, Singh AD. 3D Spectral domain optical coherence tomography findings in choroidal tumors. Eur J Ophthalmol 2011;21:271–275. Available at: https://www.ncbi.nlm.nih.gov/pubmed/21038307.

173. Krema H, Habal S, Gonzalez JE, Pavlin CJ. Role of optical coherence tomography in verifying the specificity of ultrasonography in detecting subtle subretinal fluid associated with small choroidal melanocytic tumors. Retina 2014;34:360–365. Available at: https://www.ncbi.nlm.nih.gov/pubmed/23807190.

174. Leshno A, Vishnevskia-Dai V, Barak A, et al. Optical density ratio of the subretinal fluid in choroidal melanoma and metastasis. Retina 2019;39:685–691. Available at: https://www.ncbi.nlm.nih.gov/pubmed/29252972.

175. Toledo JJ, Asencio M, Garcia JR, et al. OCT angiography: Imaging of choroidal and retinal tumors. Ophthalmol Retina 2018;2:613–622. Available at: https://www.ncbi.nlm.nih.gov/pubmed/31047615.

176. Bianciotto C, Shields CL, Guzman JM, et al. Assessment of anterior segment tumors with ultrasound biomicroscopy versus anterior segment optical coherence tomography in 200 cases. Ophthalmology 2011;118:1297–1302. Available at: https://www.ncbi.nlm.nih.gov/pubmed/21377736.

177. Augsburger JJ, Golden MI, Shields JA. Fluorescein angiography of choroidal malignant melanomas with retinal invasion. Retina 1984;4:232–241. Available at: https://www.ncbi.nlm.nih.gov/pubmed/6531518.

178. Sallet G, Amoaku WM, Lafaut BA, et al. Indocyanine green angiography of choroidal tumors. Graefes Arch Clin Exp Ophthalmol 1995;233:677–689. Available at: https://www.ncbi.nlm.nih.gov/pubmed/8566823.

Discussion update in progress

Version 1.2026 © 2026 National Comprehensive Cancer Network© (NCCN©), All rights reserved. NCCN Guidelines® and this illustration may not be reproduced in any form without the express written permission of NCCN.

PLEASE NOTE that use of this NCCN Content is governed by the End-User License Agreement, and you MAY NOT distribute this Content or use it with any artificial intelligence model or tool.
Printed by Galya Basol Kochav on 2/13/2026 11:27:31 AM. Copyright © 2026 National Comprehensive Cancer Network, Inc. All Rights Reserved.

179. Shields CL, Pellegrini M, Kligman BE, et al. Ciliary body and choroidal pseudomelanoma from ultrasonographic imaging of hypermature cataract in 20 cases. Ophthalmology 2013;120:2546–2551. Available at: https://www.ncbi.nlm.nih.gov/pubmed/23916484.

180. Polivogianis L, Seddon JM, Glynn RJ, et al. Comparison of transillumination and histologic slide measurements of tumor diameter in uveal melanoma. Ophthalmology 1988;95:1576–1582. Available at: https://www.ncbi.nlm.nih.gov/pubmed/3062526.

181. Jaarsma-Coes MG, Klaassen L, Marinkovic M, et al. Magnetic resonance imaging in the clinical care for uveal melanoma patients-a systematic review from an ophthalmic perspective. Cancers (Basel) 2023;15. Available at: https://www.ncbi.nlm.nih.gov/pubmed/37296958.

182. Skalicky SE, Holt PE, Giblin M, et al. Australian cancer network clinical practice guidelines for the management of ocular and periocular melanoma: an evidence-based literature analysis. Clin Exp Ophthalmol 2008;36:646–658. Available at: https://www.ncbi.nlm.nih.gov/pubmed/18983550.

183. Recsan Z, Karlinger K, Fodor M, et al. MRI for the evaluation of scleral invasion and extrascleral extension of uveal melanomas. Clin Radiol 2002;57:371–376. Available at: https://www.ncbi.nlm.nih.gov/pubmed/12014934.

184. Wang Y, Li YY, Su F, Xiao LH. [Clinical observation of extraocular extension of choroidal melanoma]. Zhonghua Yan Ke Za Zhi 2011;47:242–247. Available at: https://www.ncbi.nlm.nih.gov/pubmed/21609626.

185. Nguyen HG, Sznitman R, Maeder P, et al. Personalized anatomic eye model from T1-weighted volume interpolated gradient echo magnetic resonance imaging of patients with uveal melanoma. Int J Radiat Oncol Biol Phys 2018;102:813–820. Available at: https://www.ncbi.nlm.nih.gov/pubmed/29970318.

186. Heilemann G, Fetty L, Blaickner M, et al. Retina dose as a predictor for visual acuity loss in (106)Ru eye plaque brachytherapy of uveal melanomas. Radiother Oncol 2018;127:379–384. Available at: https://www.ncbi.nlm.nih.gov/pubmed/29452902.

187. Melia BM, Abramson DH, Albert DM, et al. Collaborative ocular melanoma study (COMS) randomized trial of I-125 brachytherapy for medium choroidal melanoma. I. Visual acuity after 3 years COMS report no. 16. Ophthalmology 2001;108:348–366. Available at: https://www.ncbi.nlm.nih.gov/pubmed/11158813.

188. Li HK, Shields CL, Mashayekhi A, et al. Giant choroidal nevus clinical features and natural course in 322 cases. Ophthalmology 2010;117:324–333. Available at: https://www.ncbi.nlm.nih.gov/pubmed/19969359.

189. Seider MI, Berry DE, Schefler AC, et al. Multi-center analysis of intraocular biopsy technique and outcomes for uveal melanoma: Ocular oncology study consortium report 4. Graefes Arch Clin Exp Ophthalmol 2020;258:427–435. Available at: https://www.ncbi.nlm.nih.gov/pubmed/31807898.

190. Kim RS, Chevez-Barrios P, Divatia M, et al. Yield, techniques, and complications of transvitreal and transscleral biopsies in small uveal melanoma. JAMA Ophthalmol 2018;136:482–488. Available at: https://www.ncbi.nlm.nih.gov/pubmed/29596552.

191. Singh AD, Medina CA, Singh N, et al. Fine-needle aspiration biopsy of uveal melanoma: outcomes and complications. Br J Ophthalmol 2016;100:456–462. Available at: https://www.ncbi.nlm.nih.gov/pubmed/26231747.

192. Grewal DS, Cummings TJ, Mruthyunjaya P. Outcomes of 27-gauge vitrectomy-assisted choroidal and subretinal biopsy. Ophthalmic Surg Lasers Imaging Retina 2017;48:406–415. Available at: https://www.ncbi.nlm.nih.gov/pubmed/28499052.

193. Bagger M, Tebering JF, Kiilgaard JF. The ocular consequences and applicability of minimally invasive 25-gauge transvitreal retinochoroidal biopsy. Ophthalmology 2013;120:2565–2572. Available at: https://www.ncbi.nlm.nih.gov/pubmed/24053996.

Discussion update in progress

Version 1.2026 © 2026 National Comprehensive Cancer Network© (NCCN©), All rights reserved. NCCN Guidelines® and this illustration may not be reproduced in any form without the express written permission of NCCN.

PLEASE NOTE that use of this NCCN Content is governed by the End-User License Agreement, and you MAY NOT distribute this Content or use it with any artificial intelligence model or tool.
Printed by Galya Basol Kochav on 2/13/2026 11:27:31 AM. Copyright © 2026 National Comprehensive Cancer Network, Inc. All Rights Reserved.

194. Seregard S, All-Ericsson C, Hjelmqvist L, et al. Diagnostic incisional biopsies in clinically indeterminate choroidal tumours. Eye (Lond) 2013;27:115–118. Available at: https://www.ncbi.nlm.nih.gov/pubmed/23154498.

195. Akgul H, Otterbach F, Bornfeld N, Jurklies B. Intraocular biopsy using special forceps: a new instrument and refined surgical technique. Br J Ophthalmol 2011;95:79–82. Available at: https://www.ncbi.nlm.nih.gov/pubmed/21163820.

196. Bagger M, Smidt-Nielsen I, Andersen MK, et al. Long-term metastatic risk after biopsy of posterior uveal melanoma. Ophthalmology 2018;125:1969–1976. Available at: https://www.ncbi.nlm.nih.gov/pubmed/29705056.

197. Char DH, Miller T. Accuracy of presumed uveal melanoma diagnosis before alternative therapy. Br J Ophthalmol 1995;79:692–696. Available at: https://www.ncbi.nlm.nih.gov/pubmed/7662638.

198. McCannel TA, Chang MY, Burgess BL. Multi-year follow-up of fine-needle aspiration biopsy in choroidal melanoma. Ophthalmology 2012;119:606–610. Available at: https://www.ncbi.nlm.nih.gov/pubmed/22226884.

199. Bagger MM. Intraocular biopsy of uveal melanoma risk assessment and identification of genetic prognostic markers. Acta Ophthalmol 2018;96 Suppl A112:1–28. Available at: https://www.ncbi.nlm.nih.gov/pubmed/30133961.

200. Eide N, Walaas L. Fine-needle aspiration biopsy and other biopsies in suspected intraocular malignant disease: a review. Acta Ophthalmol 2009;87:588–601. Available at: https://www.ncbi.nlm.nih.gov/pubmed/19719804.

201. Frizziero L, Midena E, Trainiti S, et al. Uveal melanoma biopsy: A review. Cancers (Basel) 2019;11. Available at: https://www.ncbi.nlm.nih.gov/pubmed/31366043.

202. Correa ZM, Augsburger JJ. Sufficiency of FNAB aspirates of posterior uveal melanoma for cytologic versus GEP classification in 159 patients, and relative prognostic significance of these classifications. Graefes Arch Clin Exp Ophthalmol 2014;252:131–135. Available at: https://www.ncbi.nlm.nih.gov/pubmed/24270974.

203. Chang MY, McCannel TA. Comparison of uveal melanoma cytopathologic sample retrieval in trans-scleral versus vitrectomy-assisted transvitreal fine needle aspiration biopsy. Br J Ophthalmol 2014;98:1654–1658. Available at: https://www.ncbi.nlm.nih.gov/pubmed/24997179.

204. Shields CL, Materin MA, Teixeira L, et al. Small choroidal melanoma with chromosome 3 monosomy on fine-needle aspiration biopsy. Ophthalmology 2007;114:1919–1924. Available at: https://www.ncbi.nlm.nih.gov/pubmed/17698199.

205. Cohen VM, Dinakaran S, Parsons MA, Rennie IG. Transvitreal fine needle aspiration biopsy: the influence of intraocular lesion size on diagnostic biopsy result. Eye (Lond) 2001;15:143–147. Available at: https://www.ncbi.nlm.nih.gov/pubmed/11339578.

206. Augsburger JJ, Correa ZM, Trichopoulos N. Prognostic implications of cytopathologic classification of melanocytic uveal tumors evaluated by fine-needle aspiration biopsy. Arq Bras Oftalmol 2013;76:72–79. Available at: https://www.ncbi.nlm.nih.gov/pubmed/23828465.

207. Eide N, Syrdalen P, Walaas L, Hagmar B. Fine needle aspiration biopsy in selecting treatment for inconclusive intraocular disease. Acta Ophthalmol Scand 1999;77:448–452. Available at: https://www.ncbi.nlm.nih.gov/pubmed/10463420.

208. Metz CH, Bornfeld N, Metz KA, Gok M. Suspected vitreous seeding of uveal melanoma: relevance of diagnostic vitrectomy. Br J Ophthalmol 2016;100:660–664. Available at: https://www.ncbi.nlm.nih.gov/pubmed/26359338.

209. Karcioglu ZA, Gordon RA, Karcioglu GL. Tumor seeding in ocular fine needle aspiration biopsy. Ophthalmology 1985;92:1763–1767. Available at: https://www.ncbi.nlm.nih.gov/pubmed/4088631.

Discussion update in progress

Version 1.2026 © 2026 National Comprehensive Cancer Network© (NCCN©), All rights reserved. NCCN Guidelines® and this illustration may not be reproduced in any form without the express written permission of NCCN.

PLEASE NOTE that use of this NCCN Content is governed by the End-User License Agreement, and you MAY NOT distribute this Content or use it with any artificial intelligence model or tool.
Printed by Galya Basol Kochav on 2/13/2026 11:27:31 AM. Copyright © 2026 National Comprehensive Cancer Network, Inc. All Rights Reserved.

210. Schefler AC, Gologorsky D, Marr BP, et al. Extraocular extension of uveal melanoma after fine-needle aspiration, vitrectomy, and open biopsy. JAMA Ophthalmol 2013;131:1220–1224. Available at: https://www.ncbi.nlm.nih.gov/pubmed/24030334.

211. Caminal JM, Sanz S, Carreras M, et al. Epibulbar seeding at the site of a transvitreal fine-needle aspiration biopsy. Arch Ophthalmol 2006;124:587–589. Available at: https://www.ncbi.nlm.nih.gov/pubmed/16606890.

212. Reddy DM, Mason LB, Mason JO, 3rd, et al. Vitrectomy and vitrector port needle biopsy of choroidal melanoma for gene expression profile testing immediately before brachytherapy. Ophthalmology 2017;124:1377–1382. Available at: https://www.ncbi.nlm.nih.gov/pubmed/28461017.

213. Sellam A, Desjardins L, Barnhill R, et al. Fine needle aspiration biopsy in uveal melanoma: Technique, complications, and outcomes. Am J Ophthalmol 2016;162:28–34 e21. Available at: https://www.ncbi.nlm.nih.gov/pubmed/26556006.

214. Shields CL, Ganguly A, Materin MA, et al. Chromosome 3 analysis of uveal melanoma using fine-needle aspiration biopsy at the time of plaque radiotherapy in 140 consecutive cases. Trans Am Ophthalmol Soc 2007;105:43–52; discussion 52–43. Available at: https://www.ncbi.nlm.nih.gov/pubmed/18427593.

215. Nagiel A, McCannel CA, Moreno C, McCannel TA. Vitrectomy-assisted biopsy for molecular prognostication of choroidal melanoma 2 mm or less in thickness with a 27-gauge cutter. Retina 2017;37:1377–1382. Available at: https://www.ncbi.nlm.nih.gov/pubmed/28486310.

216. Bechrakis NE, Foerster MH, Bornfeld N. Biopsy in indeterminate intraocular tumors. Ophthalmology 2002;109:235–242. Available at: https://www.ncbi.nlm.nih.gov/pubmed/11825801.

217. Jensen OA, Prause JU, Scherfig E. Transvitreal retino-choroidal biopsy of suspected malignant lesions of the choroid. Follow-up of cases over 7 years. Acta Ophthalmol Scand 1997;75:409–411. Available at: https://www.ncbi.nlm.nih.gov/pubmed/9374250.

218. Koch KR, Hishmi AM, Ortmann M, Heindl LM. Uveal melanoma cell seeding after transretinal tumor biopsy? Ocul Oncol Pathol 2017;3:164–167. Available at: https://www.ncbi.nlm.nih.gov/pubmed/29071267.

219. Kvanta A, Seregard S, Kopp ED, et al. Choroidal biopsies for intraocular tumors of indeterminate origin. Am J Ophthalmol 2005;140:1002–1006. Available at: https://www.ncbi.nlm.nih.gov/pubmed/16376642.

220. Foulds WS. The uses and limitations of intraocular biopsy. Eye (Lond) 1992;6 (Pt 1):11–27. Available at: https://www.ncbi.nlm.nih.gov/pubmed/1426393.

221. Dogrusoz M, Kroes WG, van Duinen SG, et al. Radiation treatment affects chromosome testing in uveal melanoma. Invest Ophthalmol Vis Sci 2015;56:5956–5964. Available at: https://www.ncbi.nlm.nih.gov/pubmed/26393462.

222. Ophthalmic Oncology Task F. Local recurrence significantly increases the risk of metastatic uveal melanoma. Ophthalmology 2016;123:86–91. Available at: https://www.ncbi.nlm.nih.gov/pubmed/26505803.

223. Shields CL, Kaliki S, Furuta M, et al. American joint committee on cancer classification of posterior uveal melanoma (tumor size category) predicts prognosis in 7731 patients. Ophthalmology 2013;120:2066–2071. Available at: https://www.ncbi.nlm.nih.gov/pubmed/23664467.

224. Singh AD, Turell ME, Topham AK. Uveal melanoma: trends in incidence, treatment, and survival. Ophthalmology 2011;118:1881–1885. Available at: https://www.ncbi.nlm.nih.gov/pubmed/21704381.

225. Isager P, Ehlers N, Overgaard J. Have choroidal and ciliary body melanomas changed during the period 1955-2000? Acta Ophthalmol Scand 2004;82:509–516. Available at: https://www.ncbi.nlm.nih.gov/pubmed/15453845.

Discussion update in progress

Version 1.2026 © 2026 National Comprehensive Cancer Network© (NCCN©), All rights reserved. NCCN Guidelines® and this illustration may not be reproduced in any form without the express written permission of NCCN.

PLEASE NOTE that use of this NCCN Content is governed by the End-User License Agreement, and you MAY NOT distribute this Content or use it with any artificial intelligence model or tool.
Printed by Galya Basol Kochav on 2/13/2026 11:27:31 AM. Copyright © 2026 National Comprehensive Cancer Network, Inc. All Rights Reserved.

226. Collaborative Ocular Melanoma Study G. The COMS randomized trial of iodine 125 brachytherapy for choroidal melanoma: V. Twelve-year mortality rates and prognostic factors: COMS report No. 28. Arch Ophthalmol 2006;124:1684–1693. Available at: https://www.ncbi.nlm.nih.gov/pubmed/17159027.

227. Augsburger JJ, Gamel JW, Lauritzen K, Brady LW. Cobalt-60 plaque radiotherapy vs enucleation for posterior uveal melanoma. Am J Ophthalmol 1990;109:585–592. Available at: https://www.ncbi.nlm.nih.gov/pubmed/2333923.

228. Seddon JM, Gragoudas ES, Egan KM, et al. Relative survival rates after alternative therapies for uveal melanoma. Ophthalmology 1990;97:769–777. Available at: https://www.ncbi.nlm.nih.gov/pubmed/2374681.

229. Mosci C, Lanza FB, Barla A, et al. Comparison of clinical outcomes for patients with large choroidal melanoma after primary treatment with enucleation or proton beam radiotherapy. Ophthalmologica 2012;227:190–196. Available at: https://www.ncbi.nlm.nih.gov/pubmed/22269846.

230. Dinca EB, Yianni J, Rowe J, et al. Survival and complications following gamma knife radiosurgery or enucleation for ocular melanoma: a 20-year experience. Acta Neurochir (Wien) 2012;154:605–610. Available at: https://www.ncbi.nlm.nih.gov/pubmed/22231777.

231. Furdova A, Slezak P, Chorvath M, et al. No differences in outcome between radical surgical treatment (enucleation) and stereotactic radiosurgery in patients with posterior uveal melanoma. Neoplasma 2010;57:377–381. Available at: https://www.ncbi.nlm.nih.gov/pubmed/20429631.

232. Rao YJ, Sein J, Badiyan S, et al. Patterns of care and survival outcomes after treatment for uveal melanoma in the post-coms era (2004-2013): a surveillance, epidemiology, and end results analysis. J Contemp Brachytherapy 2017;9:453–465. Available at: https://www.ncbi.nlm.nih.gov/pubmed/29204166.

233. The collaborative ocular melanoma study (COMS) randomized trial of pre-enucleation radiation of large choroidal melanoma III: local complications and observations following enucleation COMS report no. 11. Am J Ophthalmol 1998;126:362–372. Available at: https://www.ncbi.nlm.nih.gov/pubmed/9744369.

234. Collaborative Ocular Melanoma Study G. Assessment of metastatic disease status at death in 435 patients with large choroidal melanoma in the Collaborative Ocular Melanoma Study (COMS): COMS report no. 15. Arch Ophthalmol 2001;119:670–676. Available at: https://www.ncbi.nlm.nih.gov/pubmed/11346394.

235. Sanke RF, Collin JR, Garner A, Packard RB. Local recurrence of choroidal malignant melanoma following enucleation. Br J Ophthalmol 1981;65:846–849. Available at: https://www.ncbi.nlm.nih.gov/pubmed/7317332.

236. Vidoris AAC, Maia A, Lowen M, et al. Outcomes of primary endoresection for choroidal melanoma. Int J Retina Vitreous 2017;3:42. Available at: https://www.ncbi.nlm.nih.gov/pubmed/29142760.

237. Konstantinidis L, Groenewald C, Coupland SE, Damato B. Long-term outcome of primary endoresection of choroidal melanoma. Br J Ophthalmol 2014;98:82–85. Available at: https://www.ncbi.nlm.nih.gov/pubmed/24169650.

238. Damato BE, Paul J, Foulds WS. Risk factors for residual and recurrent uveal melanoma after trans-scleral local resection. Br J Ophthalmol 1996;80:102–108. Available at: https://www.ncbi.nlm.nih.gov/pubmed/8814738.

239. Shields JA, Shields CL, Shah P, Sivalingam V. Partial lamellar sclerouvectomy for ciliary body and choroidal tumors. Ophthalmology 1991;98:971–983. Available at: https://www.ncbi.nlm.nih.gov/pubmed/1866153.

240. Dogrusoz M, Jager MJ, Damato B. Uveal melanoma treatment and prognostication. Asia Pac J Ophthalmol (Phila) 2017;6:186–196. Available at: https://www.ncbi.nlm.nih.gov/pubmed/28399342.

Discussion update in progress

Version 1.2026 © 2026 National Comprehensive Cancer Network© (NCCN©), All rights reserved. NCCN Guidelines® and this illustration may not be reproduced in any form without the express written permission of NCCN.

PLEASE NOTE that use of this NCCN Content is governed by the End-User License Agreement, and you MAY NOT distribute this Content or use it with any artificial intelligence model or tool.
Printed by Galya Basol Kochav on 2/13/2026 11:27:31 AM. Copyright © 2026 National Comprehensive Cancer Network, Inc. All Rights Reserved.

241. Weis E, Salopek TG, McKinnon JG, et al. Management of uveal melanoma: a consensus-based provincial clinical practice guideline. Curr Oncol 2016;23:e57–64. Available at: https://www.ncbi.nlm.nih.gov/pubmed/26966414.

242. Van Acker E, De Potter P. [Porous polyethylene (Medpor) orbital implant. Prospective study of 75 primary implantations]. J Fr Ophtalmol 2001;24:1067–1073. Available at: https://www.ncbi.nlm.nih.gov/pubmed/11913237.

243. Ho VWM, Hussain RN, Czanner G, et al. Porous versus nonporous orbital implants after enucleation for uveal melanoma: A randomized study. Ophthalmic Plast Reconstr Surg 2017;33:452–458. Available at: https://www.ncbi.nlm.nih.gov/pubmed/27861329.

244. Hawkins BS, Collaborative Ocular Melanoma Study G. The collaborative ocular melanoma study (COMS) randomized trial of pre-enucleation radiation of large choroidal melanoma: IV. Ten-year mortality findings and prognostic factors. COMS report number 24. Am J Ophthalmol 2004;138:936–951. Available at: https://www.ncbi.nlm.nih.gov/pubmed/15629284.

245. The collaborative ocular melanoma study (COMS) randomized trial of pre-enucleation radiation of large choroidal melanoma II: initial mortality findings. COMS report no. 10. Am J Ophthalmol 1998;125:779–796. Available at: https://www.ncbi.nlm.nih.gov/pubmed/9645716.

246. Augsburger JJ, Lauritzen K, Gamel JW, et al. Matched group study of preenucleation radiotherapy versus enucleation alone for primary malignant melanoma of the choroid and ciliary body. Am J Clin Oncol 1990;13:382–387. Available at: https://www.ncbi.nlm.nih.gov/pubmed/2220658.

247. Diener-West M, Earle JD, Fine SL, et al. The COMS randomized trial of iodine 125 brachytherapy for choroidal melanoma, III: initial mortality findings. COMS Report No. 18. Arch Ophthalmol 2001;119:969–982. Available at: https://www.ncbi.nlm.nih.gov/pubmed/11448319.

248. Augsburger JJ, Gamel JW, Sardi VF, et al. Enucleation vs cobalt plaque radiotherapy for malignant melanomas of the choroid and ciliary body. Arch Ophthalmol 1986;104:655–661. Available at: https://www.ncbi.nlm.nih.gov/pubmed/3518677.

249. Augsburger JJ, Correa ZM, Freire J, Brady LW. Long-term survival in choroidal and ciliary body melanoma after enucleation versus plaque radiation therapy. Ophthalmology 1998;105:1670–1678. Available at: https://www.ncbi.nlm.nih.gov/pubmed/9754176.

250. Adams KS, Abramson DH, Ellsworth RM, et al. Cobalt plaque versus enucleation for uveal melanoma: comparison of survival rates. Br J Ophthalmol 1988;72:494–497. Available at: https://www.ncbi.nlm.nih.gov/pubmed/3415941.

251. Markoe AM, Brady LW, Jr., Shields JA, et al. Malignant melanoma of the eye: treatment of posterior uveal lesions by Co-60 plaque radiotherapy versus enucleation. Radiology 1985;156:801–803. Available at: https://www.ncbi.nlm.nih.gov/pubmed/4023247.

252. Brady LW, Hernandez JC. Brachytherapy of choroidal melanomas. Strahlenther Onkol 1992;168:61–65. Available at: https://www.ncbi.nlm.nih.gov/pubmed/1542847.

253. Cohen VM, Carter MJ, Kemeny A, et al. Metastasis-free survival following treatment for uveal melanoma with either stereotactic radiosurgery or enucleation. Acta Ophthalmol Scand 2003;81:383–388. Available at: https://www.ncbi.nlm.nih.gov/pubmed/12859266.

254. van Beek JGM, Buitendijk GHS, Timman R, et al. Quality of life: fractionated stereotactic radiotherapy versus enucleation treatment in uveal melanoma patients. Acta Ophthalmol 2018;96:841–848. Available at: https://www.ncbi.nlm.nih.gov/pubmed/30284368.

255. Klingenstein A, Furweger C, Muhlhofer AK, et al. Quality of life in the follow-up of uveal melanoma patients after enucleation in comparison to CyberKnife treatment. Graefes Arch Clin Exp Ophthalmol 2016;254:1005–1012. Available at: https://www.ncbi.nlm.nih.gov/pubmed/26573389.

Discussion update in progress

Version 1.2026 © 2026 National Comprehensive Cancer Network© (NCCN©), All rights reserved. NCCN Guidelines® and this illustration may not be reproduced in any form without the express written permission of NCCN.

PLEASE NOTE that use of this NCCN Content is governed by the End-User License Agreement, and you MAY NOT distribute this Content or use it with any artificial intelligence model or tool.
Printed by Galya Basol Kochav on 2/13/2026 11:27:31 AM. Copyright © 2026 National Comprehensive Cancer Network, Inc. All Rights Reserved.

256. Buonanno F, Conson M, de Almeida Ribeiro C, et al. Local tumor control and treatment related toxicity after plaque brachytherapy for uveal melanoma: A systematic review and a data pooled analysis. Radiother Oncol 2022;166:15–25. Available at: https://www.ncbi.nlm.nih.gov/pubmed/34774654.

257. Pilotto E, Vujosevic S, De Belvis V, et al. Long-term choroidal vascular changes after iodine brachytherapy versus transpupillary thermotherapy for choroidal melanoma. Eur J Ophthalmol 2009;19:646–653. Available at: https://www.ncbi.nlm.nih.gov/pubmed/19551682.

258. Sobrin L, Schiffman JC, Markoe AM, Murray TG. Outcomes of iodine 125 plaque radiotherapy after initial observation of suspected small choroidal melanomas: a pilot study. Ophthalmology 2005;112:1777–1783. Available at: https://www.ncbi.nlm.nih.gov/pubmed/16095708.

259. Jampol LM, Moy CS, Murray TG, et al. The COMS randomized trial of iodine 125 brachytherapy for choroidal melanoma: IV. Local treatment failure and enucleation in the first 5 years after brachytherapy. COMS report no. 19. Ophthalmology 2002;109:2197–2206. Available at: https://www.ncbi.nlm.nih.gov/pubmed/12466159.

260. Kreusel KM, Bechrakis N, Riese J, et al. Combined brachytherapy and transpupillary thermotherapy for large choroidal melanoma: tumor regression and early complications. Graefes Arch Clin Exp Ophthalmol 2006;244:1575–1580. Available at: https://www.ncbi.nlm.nih.gov/pubmed/16738857.

261. Shields CL, Cater J, Shields JA, et al. Combined plaque radiotherapy and transpupillary thermotherapy for choroidal melanoma: tumor control and treatment complications in 270 consecutive patients. Arch Ophthalmol 2002;120:933–940. Available at: https://www.ncbi.nlm.nih.gov/pubmed/12096964.

262. Char DH, Quivey JM, Castro JR, et al. Helium ions versus iodine 125 brachytherapy in the management of uveal melanoma. A prospective, randomized, dynamically balanced trial. Ophthalmology 1993;100:1547–1554. Available at: https://www.ncbi.nlm.nih.gov/pubmed/8414414.

263. Rospond-Kubiak I, Kociecki J, Damato B. Clinical evaluation of a paper chart for predicting ruthenium plaque placement in relation to choroidal melanoma. Eye (Lond) 2018;32:421–425. Available at: https://www.ncbi.nlm.nih.gov/pubmed/28960216.

264. Sanchez-Tabernero S, Garcia-Alvarez C, Munoz-Moreno MF, et al. Pattern of local recurrence after I-125 episcleral brachytherapy for uveal melanoma in a spanish referral ocular oncology unit. Am J Ophthalmol 2017;180:39–45. Available at: https://www.ncbi.nlm.nih.gov/pubmed/28572063.

265. Shields CL, Naseripour M, Cater J, et al. Plaque radiotherapy for large posterior uveal melanomas (> or =8-mm thick) in 354 consecutive patients. Ophthalmology 2002;109:1838–1849. Available at: https://www.ncbi.nlm.nih.gov/pubmed/12359604.

266. Chang MY, McCannel TA. Local treatment failure after globe-conserving therapy for choroidal melanoma. Br J Ophthalmol 2013;97:804–811. Available at: https://www.ncbi.nlm.nih.gov/pubmed/23645818.

267. Girvigian MR, Astrahan MA, Lim JI, et al. Episcleral plaque 125I radiotherapy with episcleral LCF hyperthermia: a prospective randomized trial. Brachytherapy 2003;2:229–239. Available at: https://www.ncbi.nlm.nih.gov/pubmed/15062131.

268. Marinkovic M, Horeweg N, Fiocco M, et al. Ruthenium-106 brachytherapy for choroidal melanoma without transpupillary thermotherapy: Similar efficacy with improved visual outcome. Eur J Cancer 2016;68:106–113. Available at: https://www.ncbi.nlm.nih.gov/pubmed/27741435.

269. Boldt HC, Melia BM, Liu JC, et al. I-125 brachytherapy for choroidal melanoma photographic and angiographic abnormalities: the collaborative ocular melanoma study: COMS Report No. 30. Ophthalmology 2009;116:106–115 e101. Available at: https://www.ncbi.nlm.nih.gov/pubmed/19118701.

Discussion update in progress

Version 1.2026 © 2026 National Comprehensive Cancer Network© (NCCN©), All rights reserved. NCCN Guidelines® and this illustration may not be reproduced in any form without the express written permission of NCCN.

PLEASE NOTE that use of this NCCN Content is governed by the End-User License Agreement, and you MAY NOT distribute this Content or use it with any artificial intelligence model or tool.
Printed by Galya Basol Kochav on 2/13/2026 11:27:31 AM. Copyright © 2026 National Comprehensive Cancer Network, Inc. All Rights Reserved.

270. Echegaray JJ, Bechrakis NE, Singh N, et al. Iodine-125 brachytherapy for uveal melanoma: A systematic review of radiation dose. Ocul Oncol Pathol 2017;3:193–198. Available at: https://www.ncbi.nlm.nih.gov/pubmed/29071269.

271. Karimi S, Arabi A, Siavashpour Z, et al. Efficacy and complications of ruthenium-106 brachytherapy for uveal melanoma: a systematic review and meta-analysis. J Contemp Brachytherapy 2021;13:358–364. Available at: https://www.ncbi.nlm.nih.gov/pubmed/34122577.

272. Jiang P, Purtskhvanidze K, Kandzia G, et al. (106)Ruthenium eye plaque brachytherapy in the management of medium sized uveal melanoma. Radiat Oncol 2020;15:183. Available at: https://www.ncbi.nlm.nih.gov/pubmed/32727533.

273. Maheshwari A, Finger PT. Regression patterns of choroidal melanoma: After palladium-103 ((103)Pd) plaque brachytherapy. Eur J Ophthalmol 2018;28:722–730. Available at: https://www.ncbi.nlm.nih.gov/pubmed/29788760.

274. Seregard S. Long-term survival after ruthenium plaque radiotherapy for uveal melanoma. A meta-analysis of studies including 1,066 patients. Acta Ophthalmol Scand 1999;77:414–417. Available at: https://www.ncbi.nlm.nih.gov/pubmed/10463412.

275. Finger PT, Berson A, Szechter A. Palladium-103 plaque radiotherapy for choroidal melanoma: results of a 7-year study. Ophthalmology 1999;106:606–613. Available at: https://www.ncbi.nlm.nih.gov/pubmed/10080222.

276. McCannel TA, Kamrava M, Demanes J, et al. 23-mm iodine-125 plaque for uveal melanoma: benefit of vitrectomy and silicone oil on visual acuity. Graefes Arch Clin Exp Ophthalmol 2016;254:2461–2467. Available at: https://www.ncbi.nlm.nih.gov/pubmed/27638702.

277. Meeralakshmi P, Shah PK, Narendran V. Experiences of two different modalities in the management of choroidal melanoma in the Asian Indian population. South Asian J Cancer 2017;6:134–136. Available at: https://www.ncbi.nlm.nih.gov/pubmed/28975125.

278. Karlovits B, Trombetta MG, Verstraeten T, et al. Local control and visual acuity following treatment of medium-sized ocular melanoma using a contact eye plaque: a single surgeon experience. Brachytherapy 2011;10:228–231. Available at: https://www.ncbi.nlm.nih.gov/pubmed/20932809.

279. Krema H, Heydarian M, Beiki-Ardakani A, et al. A comparison between (1)(2)(5)Iodine brachytherapy and stereotactic radiotherapy in the management of juxtapapillary choroidal melanoma. Br J Ophthalmol 2013;97:327–332. Available at: https://www.ncbi.nlm.nih.gov/pubmed/23335213.

280. Wilson MW, Hungerford JL. Comparison of episcleral plaque and proton beam radiation therapy for the treatment of choroidal melanoma. Ophthalmology 1999;106:1579–1587. Available at: https://www.ncbi.nlm.nih.gov/pubmed/10442907.

281. Char DH, Kroll S, Phillips TL, Quivey JM. Late radiation failures after iodine 125 brachytherapy for uveal melanoma compared with charged-particle (proton or helium ion) therapy. Ophthalmology 2002;109:1850–1854. Available at: https://www.ncbi.nlm.nih.gov/pubmed/12359605.

282. Harbour JW, Char DH, Kroll S, et al. Metastatic risk for distinct patterns of postirradiation local recurrence of posterior uveal melanoma. Ophthalmology 1997;104:1785–1792; discussion 1792–1783. Available at: https://www.ncbi.nlm.nih.gov/pubmed/9373108.

283. Wang Z, Nabhan M, Schild SE, et al. Charged particle radiation therapy for uveal melanoma: a systematic review and meta-analysis. Int J Radiat Oncol Biol Phys 2013;86:18–26. Available at: https://www.ncbi.nlm.nih.gov/pubmed/23040219.

284. Badiyan SN, Rao RC, Apicelli AJ, et al. Outcomes of iodine-125 plaque brachytherapy for uveal melanoma with intraoperative ultrasonography and supplemental transpupillary thermotherapy. Int J Radiat Oncol Biol Phys 2014;88:801–805. Available at: https://www.ncbi.nlm.nih.gov/pubmed/24462385.

Discussion update in progress

Version 1.2026 © 2026 National Comprehensive Cancer Network© (NCCN©), All rights reserved. NCCN Guidelines® and this illustration may not be reproduced in any form without the express written permission of NCCN.

PLEASE NOTE that use of this NCCN Content is governed by the End-User License Agreement, and you MAY NOT distribute this Content or use it with any artificial intelligence model or tool.
Printed by Galya Basol Kochav on 2/13/2026 11:27:31 AM. Copyright © 2026 National Comprehensive Cancer Network, Inc. All Rights Reserved.

285. Quivey JM, Augsburger J, Snelling L, Brady LW. 125I plaque therapy for uveal melanoma. Analysis of the impact of time and dose factors on local control. Cancer 1996;77:2356–2362. Available at: https://www.ncbi.nlm.nih.gov/pubmed/8635107.

286. Oellers P, Mowery YM, Perez BA, et al. Efficacy and safety of low-dose iodine plaque brachytherapy for juxtapapillary choroidal melanoma. Am J Ophthalmol 2018;186:32–40. Available at: https://www.ncbi.nlm.nih.gov/pubmed/29199010.

287. Perez BA, Mettu P, Vajzovic L, et al. Uveal melanoma treated with iodine-125 episcleral plaque: an analysis of dose on disease control and visual outcomes. Int J Radiat Oncol Biol Phys 2014;89:127–136. Available at: https://www.ncbi.nlm.nih.gov/pubmed/24613808.

288. Miguel D, de Frutos-Baraja JM, Lopez-Lara F, et al. Visual outcome after posterior uveal melanoma episcleral brachytherapy including radiobiological doses. J Contemp Brachytherapy 2018;10:123–131. Available at: https://www.ncbi.nlm.nih.gov/pubmed/29789761.

289. Wagner A, Chen A, Cook T, et al. Outcomes and control rates for I-125 plaque brachytherapy for uveal melanoma: a community-based institutional experience. ISRN Ophthalmol 2014;2014:950975. Available at: https://www.ncbi.nlm.nih.gov/pubmed/24734198.

290. Murray TG, Markoe AM, Gold AS, et al. Long-term followup comparing two treatment dosing strategies of (125) I plaque radiotherapy in the management of small/medium posterior uveal melanoma. J Ophthalmol 2013;2013:517032. Available at: https://www.ncbi.nlm.nih.gov/pubmed/23533708.

291. Jensen AW, Petersen IA, Kline RW, et al. Radiation complications and tumor control after 125I plaque brachytherapy for ocular melanoma. Int J Radiat Oncol Biol Phys 2005;63:101–108. Available at: https://www.ncbi.nlm.nih.gov/pubmed/16111577.

292. Puusaari I, Heikkonen J, Kivela T. Effect of radiation dose on ocular complications after iodine brachytherapy for large uveal melanoma: empirical data and simulation of collimating plaques. Invest Ophthalmol Vis Sci 2004;45:3425–3434. Available at: https://www.ncbi.nlm.nih.gov/pubmed/15452045.

293. Char DH, Kroll S, Quivey JM, Castro J. Long term visual outcome of radiated uveal melanomas in eyes eligible for randomisation to enucleation versus brachytherapy. Br J Ophthalmol 1996;80:117–124. Available at: https://www.ncbi.nlm.nih.gov/pubmed/8814740.

294. Wisely CE, Hadziahmetovic M, Reem RE, et al. Long-term visual acuity outcomes in patients with uveal melanoma treated with 125I episcleral OSU-Nag plaque brachytherapy. Brachytherapy 2016;15:12–22. Available at: https://www.ncbi.nlm.nih.gov/pubmed/26525215.

295. De Caluwe A, Termote K, Van Gestel D, Van Limbergen E. Dose-response in choroidal melanoma. Radiother Oncol 2018;127:374–378. Available at: https://www.ncbi.nlm.nih.gov/pubmed/29680322.

296. Danish H, Ferris MJ, Balagamwala E, et al. Comparative outcomes and toxicities for ruthenium-106 versus palladium-103 in the treatment of choroidal melanoma. Melanoma Res 2018;28:120–125. Available at: https://www.ncbi.nlm.nih.gov/pubmed/29303890.

297. Cho Y, Chang JS, Yoon JS, et al. Ruthenium-106 brachytherapy with or without additional local therapy shows favorable outcome for variable-sized choroidal melanomas in korean patients. Cancer Res Treat 2018;50:138–147. Available at: https://www.ncbi.nlm.nih.gov/pubmed/28343376.

298. Siedlecki J, Reiterer V, Leicht S, et al. Incidence of secondary glaucoma after treatment of uveal melanoma with robotic radiosurgery versus brachytherapy. Acta Ophthalmol 2017;95:e734–e739. Available at: https://www.ncbi.nlm.nih.gov/pubmed/28387434.

299. Georgopoulos M, Zehetmayer M, Ruhswurm I, et al. Tumour regression of uveal melanoma after ruthenium-106 brachytherapy or stereotactic radiotherapy with gamma knife or linear accelerator. Ophthalmologica 2003;217:315–319. Available at: https://www.ncbi.nlm.nih.gov/pubmed/12913319.

Discussion update in progress

Version 1.2026 © 2026 National Comprehensive Cancer Network© (NCCN©), All rights reserved. NCCN Guidelines® and this illustration may not be reproduced in any form without the express written permission of NCCN.

PLEASE NOTE that use of this NCCN Content is governed by the End-User License Agreement, and you MAY NOT distribute this Content or use it with any artificial intelligence model or tool.
Printed by Galya Basol Kochav on 2/13/2026 11:27:31 AM. Copyright © 2026 National Comprehensive Cancer Network, Inc. All Rights Reserved.

300. Kaiserman I, Anteby I, Chowers I, et al. Post-brachytherapy initial tumour regression rate correlates with metastatic spread in posterior uveal melanoma. Br J Ophthalmol 2004;88:892–895. Available at: https://www.ncbi.nlm.nih.gov/pubmed/15205232.

301. Tagliaferri L, Pagliara MM, Masciocchi C, et al. Nomogram for predicting radiation maculopathy in patients treated with Ruthenium-106 plaque brachytherapy for uveal melanoma. J Contemp Brachytherapy 2017;9:540–547. Available at: https://www.ncbi.nlm.nih.gov/pubmed/29441098.

302. Abrams MJ, Gagne NL, Melhus CS, Mignano JE. Brachytherapy vs. external beam radiotherapy for choroidal melanoma: Survival and patterns-of-care analyses. Brachytherapy 2016;15:216–223. Available at: https://www.ncbi.nlm.nih.gov/pubmed/26846381.

303. Bolling JP, Dagan R, Rutenberg M, et al. Treatment of uveal melanoma with radioactive iodine 125 implant compared with proton beam radiotherapy. Mayo Clin Proc Innov Qual Outcomes 2022;6:27–36. Available at: https://www.ncbi.nlm.nih.gov/pubmed/35005435.

304. Gragoudas ES, Lane AM, Regan S, et al. A randomized controlled trial of varying radiation doses in the treatment of choroidal melanoma. Arch Ophthalmol 2000;118:773–778. Available at: https://www.ncbi.nlm.nih.gov/pubmed/10865313.

305. Boudinet M, Berges O, Le Huerou JY, et al. Quantitative echography in the follow-up of patients treated with proton-beam irradiation for primary choroidal melanomas. Ultrasound Med Biol 2007;33:1046–1056. Available at: https://www.ncbi.nlm.nih.gov/pubmed/17448588.

306. Gragoudas ES, Lane AM, Munzenrider J, et al. Long-term risk of local failure after proton therapy for choroidal/ciliary body melanoma. Trans Am Ophthalmol Soc 2002;100:43–48; discussion 48–49. Available at: https://www.ncbi.nlm.nih.gov/pubmed/12545676.

307. Castro JR, Char DH, Petti PL, et al. 15 years experience with helium ion radiotherapy for uveal melanoma. Int J Radiat Oncol Biol Phys 1997;39:989–996. Available at: https://www.ncbi.nlm.nih.gov/pubmed/9392536.

308. Munzenrider JE, Verhey LJ, Gragoudas ES, et al. Conservative treatment of uveal melanoma: local recurrence after proton beam therapy. Int J Radiat Oncol Biol Phys 1989;17:493–498. Available at: https://www.ncbi.nlm.nih.gov/pubmed/2550395.

309. Lin AJ, Rao YJ, Acharya S, et al. Patterns of care and outcomes of proton and eye plaque brachytherapy for uveal melanoma: Review of the National Cancer Database. Brachytherapy 2017;16:1225–1231. Available at: https://www.ncbi.nlm.nih.gov/pubmed/28966081.

310. Tsuji H, Ishikawa H, Yanagi T, et al. Carbon-ion radiotherapy for locally advanced or unfavorably located choroidal melanoma: a Phase I/II dose-escalation study. Int J Radiat Oncol Biol Phys 2007;67:857–862. Available at: https://www.ncbi.nlm.nih.gov/pubmed/17161555.

311. Sikuade MJ, Salvi S, Rundle PA, et al. Outcomes of treatment with stereotactic radiosurgery or proton beam therapy for choroidal melanoma. Eye (Lond) 2015;29:1194–1198. Available at: https://www.ncbi.nlm.nih.gov/pubmed/26160531.

312. Modorati G, Miserocchi E, Galli L, et al. Gamma knife radiosurgery for uveal melanoma: 12 years of experience. Br J Ophthalmol 2009;93:40–44. Available at: https://www.ncbi.nlm.nih.gov/pubmed/18757470.

313. Simonova G, Novotny J, Jr., Liscak R, Pilbauer J. Leksell gamma knife treatment of uveal melanoma. J Neurosurg 2002;97:635–639. Available at: https://www.ncbi.nlm.nih.gov/pubmed/12507111.

314. Muller K, Nowak PJ, de Pan C, et al. Effectiveness of fractionated stereotactic radiotherapy for uveal melanoma. Int J Radiat Oncol Biol Phys 2005;63:116–122. Available at: https://www.ncbi.nlm.nih.gov/pubmed/16111579.

315. Haji Mohd Yasin NA, Gray AR, Bevin TH, et al. Choroidal melanoma treated with stereotactic fractionated radiotherapy and prophylactic intravitreal bevacizumab: The Dunedin Hospital experience. J Med

Discussion update in progress

Version 1.2026 © 2026 National Comprehensive Cancer Network© (NCCN©), All rights reserved. NCCN Guidelines® and this illustration may not be reproduced in any form without the express written permission of NCCN.

PLEASE NOTE that use of this NCCN Content is governed by the End-User License Agreement, and you MAY NOT distribute this Content or use it with any artificial intelligence model or tool.
Printed by Galya Basol Kochav on 2/13/2026 11:27:31 AM. Copyright © 2026 National Comprehensive Cancer Network, Inc. All Rights Reserved.

Imaging Radiat Oncol 2016;60:756–763. Available at: https://www.ncbi.nlm.nih.gov/pubmed/27378522.

316. Dunavoelgyi R, Zehetmayer M, Gleiss A, et al. Hypofractionated stereotactic photon radiotherapy of posteriorly located choroidal melanoma with five fractions at ten Gy--clinical results after six years of experience. Radiother Oncol 2013;108:342–347. Available at: https://www.ncbi.nlm.nih.gov/pubmed/24044800.

317. Suesskind D, Scheiderbauer J, Buchgeister M, et al. Retrospective evaluation of patients with uveal melanoma treated by stereotactic radiosurgery with and without tumor resection. JAMA Ophthalmol 2013;131:630–637. Available at: https://www.ncbi.nlm.nih.gov/pubmed/23494018.

318. van Beek JGM, Ramdas WD, Angi M, et al. Local tumour control and radiation side effects for fractionated stereotactic photon beam radiotherapy compared to proton beam radiotherapy in uveal melanoma. Radiother Oncol 2021;157:219–224. Available at: https://www.ncbi.nlm.nih.gov/pubmed/33549643.

319. Mueller AJ, Talies S, Schaller UC, et al. Stereotactic radiosurgery of large uveal melanomas with the gamma-knife. Ophthalmology 2000;107:1381–1387; discussion 1387–1388. Available at: https://www.ncbi.nlm.nih.gov/pubmed/10889116.

320. Zehetmayer M, Kitz K, Menapace R, et al. Local tumor control and morbidity after one to three fractions of stereotactic external beam irradiation for uveal melanoma. Radiother Oncol 2000;55:135–144. Available at: https://www.ncbi.nlm.nih.gov/pubmed/10799725.

321. Dieckmann K, Georg D, Zehetmayer M, et al. LINAC based stereotactic radiotherapy of uveal melanoma: 4 years clinical experience. Radiother Oncol 2003;67:199–206. Available at: https://www.ncbi.nlm.nih.gov/pubmed/12812851.

322. Dunavoelgyi R, Dieckmann K, Gleiss A, et al. Local tumor control, visual acuity, and survival after hypofractionated stereotactic photon radiotherapy of choroidal melanoma in 212 patients treated between 1997 and 2007. Int J Radiat Oncol Biol Phys 2011;81:199–205. Available at: https://www.ncbi.nlm.nih.gov/pubmed/20675066.

323. van den Bosch T, Vaarwater J, Verdijk R, et al. Risk factors associated with secondary enucleation after fractionated stereotactic radiotherapy in uveal melanoma. Acta Ophthalmol 2015;93:555–560. Available at: https://www.ncbi.nlm.nih.gov/pubmed/25879399.

324. Krema H, Heydarian M, Beiki-Ardakani A, et al. Dosimetric and late radiation toxicity comparison between iodine-125 brachytherapy and stereotactic radiation therapy for juxtapapillary choroidal melanoma. Int J Radiat Oncol Biol Phys 2013;86:510–515. Available at: https://www.ncbi.nlm.nih.gov/pubmed/23507292.

325. Zahorjanova P, Furdova A, Waczulikova I, et al. Radiation maculopathy after one-day session stereotactic radiosurgery in patients with ciliary body and choroidal melanoma. Cesk Slov Oftalmol 2019;75:3–10. Available at: https://www.ncbi.nlm.nih.gov/pubmed/31382751.

326. Dunavoelgyi R, Dieckmann K, Gleiss A, et al. Radiogenic side effects after hypofractionated stereotactic photon radiotherapy of choroidal melanoma in 212 patients treated between 1997 and 2007. Int J Radiat Oncol Biol Phys 2012;83:121–128. Available at: https://www.ncbi.nlm.nih.gov/pubmed/21945109.

327. Gigliotti CR, Modorati G, Di Nicola M, et al. Predictors of radio-induced visual impairment after radiosurgery for uveal melanoma. Br J Ophthalmol 2018;102:833–839. Available at: https://www.ncbi.nlm.nih.gov/pubmed/28903963.

328. Augsburger JJ, Roth SE, Magargal LE, Shields JA. Panretinal photocoagulation for radiation-induced ocular ischemia. Ophthalmic Surg 1987;18:589–593. Available at: https://www.ncbi.nlm.nih.gov/pubmed/3658314.

329. Konstantinidis L, Groenewald C, Coupland SE, Damato B. Trans-scleral local resection of toxic choroidal melanoma after proton beam radiotherapy. Br J Ophthalmol 2014;98:775–779. Available at: https://www.ncbi.nlm.nih.gov/pubmed/24568869.

Discussion update in progress

Version 1.2026 © 2026 National Comprehensive Cancer Network© (NCCN©), All rights reserved. NCCN Guidelines® and this illustration may not be reproduced in any form without the express written permission of NCCN.

PLEASE NOTE that use of this NCCN Content is governed by the End-User License Agreement, and you MAY NOT distribute this Content or use it with any artificial intelligence model or tool.
Printed by Galya Basol Kochav on 2/13/2026 11:27:31 AM. Copyright © 2026 National Comprehensive Cancer Network, Inc. All Rights Reserved.

330. Finger PT, Chin KJ. Antivascular endothelial growth factor bevacizumab for radiation optic neuropathy: secondary to plaque radiotherapy. Int J Radiat Oncol Biol Phys 2012;82:789–798. Available at: https://www.ncbi.nlm.nih.gov/pubmed/21277107.

331. Finger PT, Chin KJ, Semenova EA. Intravitreal anti-VEGF therapy for macular radiation retinopathy: a 10-year study. Eur J Ophthalmol 2016;26:60–66. Available at: https://www.ncbi.nlm.nih.gov/pubmed/26391167.

332. Roelofs K, Larocque MP, Murtha A, Weis E. The use of intravitreal Anti-VEGF and triamcinolone in the treatment of radiation papillopathy. Ocul Oncol Pathol 2018;4:395–400. Available at: https://www.ncbi.nlm.nih.gov/pubmed/30574493.

333. Russo A, Reibaldi M, Avitabile T, et al. Dexamethasone intravitreal implant vs ranibizumab in the treatment of macular edema secondary to brachytherapy for choroidal melanoma. Retina 2018;38:788–794. Available at: https://www.ncbi.nlm.nih.gov/pubmed/28272283.

334. Daruich A, Matet A, Schalenbourg A, Zografos L. Intravitreal anti-vascular endothelial growth factor treatment at 2-month intervals reduces foveal avascular zone enlargement and vision loss in radiation maculopathy: A Pilot Study. Retina 2019;39:1519–1526. Available at: https://www.ncbi.nlm.nih.gov/pubmed/29746413.

335. Murray TG, Latiff A, Villegas VM, Gold AS. Aflibercept for radiation maculopathy study: A prospective, randomized clinical study. Ophthalmol Retina 2019;3:561–566. Available at: https://www.ncbi.nlm.nih.gov/pubmed/31277797.

336. Horgan N, Shields CL, Mashayekhi A, et al. Periocular triamcinolone for prevention of macular edema after iodine 125 plaque radiotherapy of uveal melanoma. Retina 2008;28:987–995. Available at: https://www.ncbi.nlm.nih.gov/pubmed/18698302.

337. Horgan N, Shields CL, Mashayekhi A, et al. Periocular triamcinolone for prevention of macular edema after plaque radiotherapy of uveal melanoma: a randomized controlled trial. Ophthalmology 2009;116:1383–1390. Available at: https://www.ncbi.nlm.nih.gov/pubmed/19481812.

338. Kim IK, Lane AM, Jain P, et al. Ranibizumab for the prevention of radiation complications in patients treated with proton beam irradiation for choroidal melanoma. Trans Am Ophthalmol Soc 2016;114:T2. Available at: https://www.ncbi.nlm.nih.gov/pubmed/27630373.

339. Shields JA, Glazer LC, Mieler WF, et al. Comparison of xenon arc and argon laser photocoagulation in the treatment of choroidal melanomas. Am J Ophthalmol 1990;109:647–655. Available at: https://www.ncbi.nlm.nih.gov/pubmed/2346193.

340. Shields JA, Shields CL, Peairs R, Racciato P. Laser ablation of an enlarging small melanocytic choroidal tumor: 16-year follow-up and rationale for treatment. Ophthalmic Surg Lasers Imaging 2006;37:79–81. Available at: https://www.ncbi.nlm.nih.gov/pubmed/16468559.

341. Qiang Z, Cairns JD. Laser photocoagulation treatment of choroidal melanoma. Aust N Z J Ophthalmol 1993;21:87–92. Available at: https://www.ncbi.nlm.nih.gov/pubmed/8333939.

342. Brewington BY, Shao YF, Davidorf FH, Cebulla CM. Brachytherapy for patients with uveal melanoma: historical perspectives and future treatment directions. Clin Ophthalmol 2018;12:925–934. Available at: https://www.ncbi.nlm.nih.gov/pubmed/29844657.

343. Brancato R, Menchini U, Pece A. Enucleation after argon laser photocoagulation for choroidal melanoma. Ann Ophthalmol 1988;20:296–298. Available at: https://www.ncbi.nlm.nih.gov/pubmed/3056206.

344. Augsburger JJ, Mullen D, Kleineidam M. Planned combined I-125 plaque irradiation and indirect ophthalmoscope laser therapy for choroidal malignant melanoma. Ophthalmic Surg 1993;24:76–81. Available at: https://www.ncbi.nlm.nih.gov/pubmed/8446358.

345. Harbour JW, Meredith TA, Thompson PA, Gordon ME. Transpupillary thermotherapy versus plaque radiotherapy for suspected choroidal

Discussion update in progress

Version 1.2026 © 2026 National Comprehensive Cancer Network© (NCCN©), All rights reserved. NCCN Guidelines® and this illustration may not be reproduced in any form without the express written permission of NCCN.

PLEASE NOTE that use of this NCCN Content is governed by the End-User License Agreement, and you MAY NOT distribute this Content or use it with any artificial intelligence model or tool.
Printed by Galya Basol Kochav on 2/13/2026 11:27:31 AM. Copyright © 2026 National Comprehensive Cancer Network, Inc. All Rights Reserved.

melanomas. Ophthalmology 2003;110:2207–2214; discussion 2215. Available at: https://www.ncbi.nlm.nih.gov/pubmed/14597531.

346. Win PH, Robertson DM, Buettner H, et al. Extended follow-up of small melanocytic choroidal tumors treated with transpupillary thermotherapy. Arch Ophthalmol 2006;124:503–506. Available at: https://www.ncbi.nlm.nih.gov/pubmed/16606875.

347. Spire M, Devouassoux MS, Kodjikian L, et al. Primary transpupillary thermotherapy for 18 small posterior pole uveal melanomas. Am J Ophthalmol 2006;141:840–849. Available at: https://www.ncbi.nlm.nih.gov/pubmed/16678505.

348. Bartlema YM, Oosterhuis JA, Journee-De Korver JG, et al. Combined plaque radiotherapy and transpupillary thermotherapy in choroidal melanoma: 5 years' experience. Br J Ophthalmol 2003;87:1370–1373. Available at: https://www.ncbi.nlm.nih.gov/pubmed/14609837.

349. Desjardins L, Lumbroso-Le Rouic L, Levy-Gabriel C, et al. Combined proton beam radiotherapy and transpupillary thermotherapy for large uveal melanomas: a randomized study of 151 patients. Ophthalmic Res 2006;38:255–260. Available at: https://www.ncbi.nlm.nih.gov/pubmed/16888407.

350. Yarovoy AA, Magaramov DA, Bulgakova ES. The comparison of ruthenium brachytherapy and simultaneous transpupillary thermotherapy of choroidal melanoma with brachytherapy alone. Brachytherapy 2012;11:224–229. Available at: https://www.ncbi.nlm.nih.gov/pubmed/22104351.

351. Gunduz K, Kurt RA, Akmese HE, et al. Ruthenium-106 plaque radiotherapy alone or in combination with transpupillary thermotherapy in the management of choroidal melanoma. Jpn J Ophthalmol 2010;54:338–343. Available at: https://www.ncbi.nlm.nih.gov/pubmed/20700803.

352. Croughs P, Baguette MN. [Treatment of choroidal nevi and melanomas using cryo-applications: preliminary study]. Bull Soc Belge Ophtalmol 1992;243:87–93. Available at: https://www.ncbi.nlm.nih.gov/pubmed/1302157.

353. Abramson DH, Lisman RD. Cryopexy of a choroidal melanoma. Ann Ophthalmol 1979;11:1418–1421. Available at: https://www.ncbi.nlm.nih.gov/pubmed/556166.

354. Wilson DJ, Klein ML. Cryotherapy as a primary treatment for choroidal melanoma. Arch Ophthalmol 2002;120:400–403. Available at: https://www.ncbi.nlm.nih.gov/pubmed/11879152.

355. Jalkh AE, Trempe CL, Nasrallah FP, et al. Treatment of small choroidal melanomas with photocoagulation. Ophthalmic Surg 1988;19:738–742. Available at: https://www.ncbi.nlm.nih.gov/pubmed/3194108.

356. Shields JA. Current approaches to the diagnosis and management of choroidal melanomas. Surv Ophthalmol 1977;21:443–463. Available at: https://www.ncbi.nlm.nih.gov/pubmed/331533.

357. Shields CL, Sioufi K, Robbins JS, et al. Large uveal melanoma (>/=10 mm thickness): Clinical features and millimeter-by-millimeter risk of metastasis in 1311 cases. The 2018 Albert E. Finley lecture. Retina 2018;38:2010–2022. Available at: https://www.ncbi.nlm.nih.gov/pubmed/29528980.

358. van Beek JG, Koopmans AE, Vaarwater J, et al. The prognostic value of extraocular extension in relation to monosomy 3 and gain of chromosome 8q in uveal melanoma. Invest Ophthalmol Vis Sci 2014;55:1284–1291. Available at: https://www.ncbi.nlm.nih.gov/pubmed/24508790.

359. Blanco G. Diagnosis and treatment of orbital invasion in uveal melanoma. Can J Ophthalmol 2004;39:388–396. Available at: https://www.ncbi.nlm.nih.gov/pubmed/15327104.

360. Rodriguez A, Duenas-Gonzalez A, Delgado-Pelayo S. Clinical presentation and management of uveal melanoma. Mol Clin Oncol 2016;5:675–677. Available at: https://www.ncbi.nlm.nih.gov/pubmed/28101347.

Discussion update in progress

Version 1.2026 © 2026 National Comprehensive Cancer Network© (NCCN©), All rights reserved. NCCN Guidelines® and this illustration may not be reproduced in any form without the express written permission of NCCN.

PLEASE NOTE that use of this NCCN Content is governed by the End-User License Agreement, and you MAY NOT distribute this Content or use it with any artificial intelligence model or tool.
Printed by Galya Basol Kochav on 2/13/2026 11:27:31 AM. Copyright © 2026 National Comprehensive Cancer Network, Inc. All Rights Reserved.

361. Mirkiewicz-Sieradzka B, Zygulska-Mach H, Romanowska B, et al. [Attempts of orbit irradiation after enucleation of the eye with malignant choroidal melanoma. Part I]. Klin Oczna 1999;101:287–290. Available at: https://www.ncbi.nlm.nih.gov/pubmed/10581897.

362. Shammas HF, Blodi FC. Orbital extension of choroidal and ciliary body melanomas. Arch Ophthalmol 1977;95:2002–2005. Available at: https://www.ncbi.nlm.nih.gov/pubmed/921579.

363. Kersten RC, Tse DT, Anderson RL, Blodi FC. The role of orbital exenteration in choroidal melanoma with extrascleral extension. Ophthalmology 1985;92:436–443. Available at: https://www.ncbi.nlm.nih.gov/pubmed/3991131.

364. Pach JM, Robertson DM, Taney BS, et al. Prognostic factors in choroidal and ciliary body melanomas with extrascleral extension. Am J Ophthalmol 1986;101:325–331. Available at: https://www.ncbi.nlm.nih.gov/pubmed/3953727.

365. Hykin PG, McCartney AC, Plowman PN, Hungerford JL. Postenucleation orbital radiotherapy for the treatment of malignant melanoma of the choroid with extrascleral extension. Br J Ophthalmol 1990;74:36–39. Available at: https://www.ncbi.nlm.nih.gov/pubmed/2106340.

366. Eskelin S, Pyrhonen S, Summanen P, et al. Tumor doubling times in metastatic malignant melanoma of the uvea: tumor progression before and after treatment. Ophthalmology 2000;107:1443–1449. Available at: https://www.ncbi.nlm.nih.gov/pubmed/10919885.

367. Design and methods of a clinical trial for a rare condition: the Collaborative Ocular Melanoma Study. COMS Report No. 3. Control Clin Trials 1993;14:362–391. Available at: https://www.ncbi.nlm.nih.gov/pubmed/8222668.

368. Marchini G, Gerosa M, Piovan E, et al. Gamma Knife stereotactic radiosurgery for uveal melanoma: clinical results after 2 years. Stereotact Funct Neurosurg 1996;66 Suppl 1:208–213. Available at: https://www.ncbi.nlm.nih.gov/pubmed/9032863.

369. Horgan N, Shields CL, Mashayekhi A, et al. Early macular morphological changes following plaque radiotherapy for uveal melanoma. Retina 2008;28:263–273. Available at: https://www.ncbi.nlm.nih.gov/pubmed/18301032.

370. Tsui I, Beardsley RM, McCannel TA, et al. Visual acuity, contrast sensitivity and color vision three years after iodine-125 brachytherapy for choroidal and ciliary body melanoma. Open Ophthalmol J 2015;9:131–135. Available at: https://www.ncbi.nlm.nih.gov/pubmed/26312123.

371. Eibl-Lindner K, Furweger C, Nentwich M, et al. Robotic radiosurgery for the treatment of medium and large uveal melanoma. Melanoma Res 2016;26:51–57. Available at: https://www.ncbi.nlm.nih.gov/pubmed/26484738.

372. Collaborative Ocular Melanoma Study G. Ten-year follow-up of fellow eyes of patients enrolled in collaborative ocular melanoma study randomized trials: COMS report no. 22. Ophthalmology 2004;111:966–976. Available at: https://www.ncbi.nlm.nih.gov/pubmed/15121376.

373. Diener-West M, Reynolds SM, Agugliaro DJ, et al. Screening for metastasis from choroidal melanoma: the collaborative ocular melanoma study group report 23. J Clin Oncol 2004;22:2438–2444. Available at: https://www.ncbi.nlm.nih.gov/pubmed/15197206.

374. Diener-West M, Reynolds SM, Agugliaro DJ, et al. Development of metastatic disease after enrollment in the COMS trials for treatment of choroidal melanoma: Collaborative Ocular Melanoma Study Group Report No. 26. Arch Ophthalmol 2005;123:1639–1643. Available at: https://www.ncbi.nlm.nih.gov/pubmed/16344433.

375. Mahendraraj K, Shrestha S, Lau CS, Chamberlain RS. Ocular melanoma-when you have seen one, you have not seen them all: a clinical outcome study from the Surveillance, Epidemiology and End Results (SEER) database (1973-2012). Clin Ophthalmol 2017;11:153–160. Available at: https://www.ncbi.nlm.nih.gov/pubmed/28115829.

376. Scott JF, Vyas R, Galvin J, et al. Primary bilateral uveal melanoma: a population-based study and systematic review. Clin Exp Ophthalmol

Discussion update in progress

Version 1.2026 © 2026 National Comprehensive Cancer Network© (NCCN©), All rights reserved. NCCN Guidelines® and this illustration may not be reproduced in any form without the express written permission of NCCN.

PLEASE NOTE that use of this NCCN Content is governed by the End-User License Agreement, and you MAY NOT distribute this Content or use it with any artificial intelligence model or tool.
Printed by Galya Basol Kochav on 2/13/2026 11:27:31 AM. Copyright © 2026 National Comprehensive Cancer Network, Inc. All Rights Reserved.

2018;46:502–510. Available at: https://www.ncbi.nlm.nih.gov/pubmed/29219254.

377. Khetan V, Ambatipudi S, Gopal L. Presumed metastasis of choroidal melanoma to the contralateral choroid. Retin Cases Brief Rep 2010;4:387–389. Available at: https://www.ncbi.nlm.nih.gov/pubmed/25390926.

378. Shields JA, Shields CL, Shakin EP, Kobetz LE. Metastasis of choroidal melanoma to the contralateral choroid, orbit, and eyelid. Br J Ophthalmol 1988;72:456–460. Available at: https://www.ncbi.nlm.nih.gov/pubmed/3390423.

379. Singh AD, Shields JA, Shields CL, Sato T. Choroidal melanoma metastatic to the contralateral choroid. Am J Ophthalmol 2001;132:941–943. Available at: https://www.ncbi.nlm.nih.gov/pubmed/11730671.

380. Torossian NM, Wallace RT, Hwu WJ, Bedikian AY. Metastasis of ciliary body melanoma to the contralateral eye: a case report and review of uveal melanoma literature. Case Rep Oncol Med 2015;2015:427163. Available at: https://www.ncbi.nlm.nih.gov/pubmed/25874144.

381. Bourla DH, Young TA. Treatment considerations for primary uveal melanoma with choroidal metastasis to the fellow eye. Semin Ophthalmol 2007;22:175–177. Available at: https://www.ncbi.nlm.nih.gov/pubmed/17763240.

382. Caminal Mitjana JM, Vila Grane N, Adan Civera A, et al. Clinical course of a presumed metastatic uveal melanoma to the contralateral choroid. Semin Ophthalmol 2015;30:417–419. Available at: https://www.ncbi.nlm.nih.gov/pubmed/24171794.

383. Coupland SE, Sidiki S, Clark BJ, et al. Metastatic choroidal melanoma to the contralateral orbit 40 years after enucleation. Arch Ophthalmol 1996;114:751–756. Available at: https://www.ncbi.nlm.nih.gov/pubmed/8639093.

384. George S, Cooke CA, Mc Ginnity GF, et al. Treated choroidal melanoma with late metastases to the contralateral orbit. Clin Med Pathol 2009;2:5–8. Available at: https://www.ncbi.nlm.nih.gov/pubmed/21151543.

385. Belfort RN, Muller MS, Isenberg J, et al. Metastatic choroidal melanoma to the contralateral eye: a rare case. Arq Bras Oftalmol 2018;81:517–519. Available at: https://www.ncbi.nlm.nih.gov/pubmed/30328940.

386. Freton A, Chin KJ, Raut R, et al. Initial PET/CT staging for choroidal melanoma: AJCC correlation and second nonocular primaries in 333 patients. Eur J Ophthalmol 2012;22:236–243. Available at: https://www.ncbi.nlm.nih.gov/pubmed/21959680.

387. Fakiris AJ, Lo SS, Henderson MA, et al. Gamma-knife-based stereotactic radiosurgery for uveal melanoma. Stereotact Funct Neurosurg 2007;85:106–112. Available at: https://www.ncbi.nlm.nih.gov/pubmed/17228176.

388. Muller K, Naus N, Nowak PJ, et al. Fractionated stereotactic radiotherapy for uveal melanoma, late clinical results. Radiother Oncol 2012;102:219–224. Available at: https://www.ncbi.nlm.nih.gov/pubmed/21864922.

389. Xu LT, Funchain PF, Bena JF, et al. Uveal melanoma metastatic to the liver: Treatment trends and outcomes. Ocul Oncol Pathol 2019;5:323–332. Available at: https://www.ncbi.nlm.nih.gov/pubmed/31559243.

390. Rossi E, Croce M, Reggiani F, et al. Uveal melanoma metastasis. Cancers (Basel) 2021;13. Available at: https://www.ncbi.nlm.nih.gov/pubmed/34830841.

391. Kim JH, Shin SJ, Heo SJ, et al. Prognoses and clinical outcomes of primary and recurrent uveal melanoma. Cancer Res Treat 2018;50:1238–1251. Available at: https://www.ncbi.nlm.nih.gov/pubmed/29281872.

392. Eskelin S, Pyrhonen S, Hahka-Kemppinen M, et al. A prognostic model and staging for metastatic uveal melanoma. Cancer 2003;97:465–475. Available at: https://www.ncbi.nlm.nih.gov/pubmed/12518371.

Discussion update in progress

Version 1.2026 © 2026 National Comprehensive Cancer Network© (NCCN©), All rights reserved. NCCN Guidelines® and this illustration may not be reproduced in any form without the express written permission of NCCN.

PLEASE NOTE that use of this NCCN Content is governed by the End-User License Agreement, and you MAY NOT distribute this Content or use it with any artificial intelligence model or tool.
Printed by Galya Basol Kochav on 2/13/2026 11:27:31 AM. Copyright © 2026 National Comprehensive Cancer Network, Inc. All Rights Reserved.

393. Onken MD, Worley LA, Ehlers JP, Harbour JW. Gene expression profiling in uveal melanoma reveals two molecular classes and predicts metastatic death. Cancer Res 2004;64:7205–7209. Available at: https://www.ncbi.nlm.nih.gov/pubmed/15492234.

394. Tschentscher F, Husing J, Holter T, et al. Tumor classification based on gene expression profiling shows that uveal melanomas with and without monosomy 3 represent two distinct entities. Cancer Res 2003;63:2578–2584. Available at: https://www.ncbi.nlm.nih.gov/pubmed/12750282.

395. Onken MD, Worley LA, Davila RM, et al. Prognostic testing in uveal melanoma by transcriptomic profiling of fine needle biopsy specimens. J Mol Diagn 2006;8:567–573. Available at: https://www.ncbi.nlm.nih.gov/pubmed/17065425.

396. Worley LA, Onken MD, Person E, et al. Transcriptomic versus chromosomal prognostic markers and clinical outcome in uveal melanoma. Clin Cancer Res 2007;13:1466–1471. Available at: https://www.ncbi.nlm.nih.gov/pubmed/17332290.

397. Petrausch U, Martus P, Tonnies H, et al. Significance of gene expression analysis in uveal melanoma in comparison to standard risk factors for risk assessment of subsequent metastases. Eye (Lond) 2008;22:997–1007. Available at: https://www.ncbi.nlm.nih.gov/pubmed/17384575.

398. Onken MD, Worley LA, Tuscan MD, Harbour JW. An accurate, clinically feasible multi-gene expression assay for predicting metastasis in uveal melanoma. J Mol Diagn 2010;12:461–468. Available at: https://www.ncbi.nlm.nih.gov/pubmed/20413675.

399. Chappell MC, Char DH, Cole TB, et al. Uveal melanoma: molecular pattern, clinical features, and radiation response. Am J Ophthalmol 2012;154:227–232 e222. Available at: https://www.ncbi.nlm.nih.gov/pubmed/22541662.

400. Correa ZM, Augsburger JJ. Independent prognostic significance of gene expression profile class and largest basal diameter of posterior uveal melanomas. Am J Ophthalmol 2016;162:20–27 e21. Available at: https://www.ncbi.nlm.nih.gov/pubmed/26596399.

401. Decatur CL, Ong E, Garg N, et al. Driver mutations in uveal melanoma: Associations with gene expression profile and patient outcomes. JAMA Ophthalmol 2016;134:728–733. Available at: https://www.ncbi.nlm.nih.gov/pubmed/27123562.

402. Field MG, Decatur CL, Kurtenbach S, et al. PRAME as an independent biomarker for metastasis in uveal melanoma. Clin Cancer Res 2016;22:1234–1242. Available at: https://www.ncbi.nlm.nih.gov/pubmed/26933176.

403. Plasseraud KM, Cook RW, Tsai T, et al. Clinical performance and management outcomes with the DecisionDx-UM gene expression profile test in a prospective multicenter study. J Oncol 2016;2016:5325762. Available at: https://www.ncbi.nlm.nih.gov/pubmed/27446211.

404. Walter SD, Chao DL, Feuer W, et al. Prognostic implications of tumor diameter in association with gene expression profile for uveal melanoma. JAMA Ophthalmol 2016;134:734–740. Available at: https://www.ncbi.nlm.nih.gov/pubmed/27123792.

405. Cai L, Paez-Escamilla M, Walter SD, et al. Gene expression profiling and PRAME status versus tumor-node-metastasis staging for prognostication in uveal melanoma. Am J Ophthalmol 2018;195:154–160. Available at: https://www.ncbi.nlm.nih.gov/pubmed/30092184.

406. Afshar AR, Damato BE, Stewart JM, et al. Next-generation sequencing of uveal melanoma for detection of genetic alterations predicting metastasis. Transl Vis Sci Technol 2019;8:18. Available at: https://www.ncbi.nlm.nih.gov/pubmed/31024753.

407. Harbour JW, Correa ZM, Schefler AC, et al. 15-gene expression profile and PRAME as integrated prognostic test for uveal melanoma: First report of collaborative ocular oncology group study no. 2 (COOG2.1). J Clin Oncol 2024;42:3319–3329. Available at: https://www.ncbi.nlm.nih.gov/pubmed/39052972.

Discussion update in progress

Version 1.2026 © 2026 National Comprehensive Cancer Network© (NCCN©), All rights reserved. NCCN Guidelines® and this illustration may not be reproduced in any form without the express written permission of NCCN.

PLEASE NOTE that use of this NCCN Content is governed by the End-User License Agreement, and you MAY NOT distribute this Content or use it with any artificial intelligence model or tool.
Printed by Galya Basol Kochav on 2/13/2026 11:27:31 AM. Copyright © 2026 National Comprehensive Cancer Network, Inc. All Rights Reserved.

408. Desjardins L, Levy-Gabriel C, Lumbroso-Lerouic L, et al. [Prognostic factors for malignant uveal melanoma. Retrospective study on 2,241 patients and recent contribution of monosomy-3 research]. J Fr Ophtalmol 2006;29:741–749. Available at: https://www.ncbi.nlm.nih.gov/pubmed/16988624.

409. Mazloumi M, Vichitvejpaisal P, Dalvin LA, et al. Accuracy of the cancer genome atlas classification vs american joint committee on cancer classification for prediction of metastasis in patients with uveal melanoma. JAMA Ophthalmol 2020;138:260–267. Available at: https://www.ncbi.nlm.nih.gov/pubmed/31944225.

410. Mooy C, Vissers K, Luyten G, et al. DNA flow cytometry in uveal melanoma: the effect of pre-enucleation irradiation. Br J Ophthalmol 1995;79:174–177. Available at: https://www.ncbi.nlm.nih.gov/pubmed/7696240.

411. Trolet J, Hupe P, Huon I, et al. Genomic profiling and identification of high-risk uveal melanoma by array CGH analysis of primary tumors and liver metastases. Invest Ophthalmol Vis Sci 2009;50:2572–2580. Available at: https://www.ncbi.nlm.nih.gov/pubmed/19151381.

412. Shields CL, Ganguly A, Bianciotto CG, et al. Prognosis of uveal melanoma in 500 cases using genetic testing of fine-needle aspiration biopsy specimens. Ophthalmology 2011;118:396–401. Available at: https://www.ncbi.nlm.nih.gov/pubmed/20869116.

413. Staby KM, Gravdal K, Mork SJ, et al. Prognostic impact of chromosomal aberrations and GNAQ, GNA11 and BAP1 mutations in uveal melanoma. Acta Ophthalmol 2018;96:31–38. Available at: https://www.ncbi.nlm.nih.gov/pubmed/28444874.

414. Patrone S, Maric I, Rutigliani M, et al. Prognostic value of chromosomal imbalances, gene mutations, and BAP1 expression in uveal melanoma. Genes Chromosomes Cancer 2018;57:387–400. Available at: https://www.ncbi.nlm.nih.gov/pubmed/29689622.

415. Shields CL, Dalvin LA, Vichitvejpaisal P, et al. Prognostication of uveal melanoma is simple and highly predictive using The Cancer Genome Atlas (TCGA) classification: A review. Indian J Ophthalmol 2019;67:1959–1963. Available at: https://www.ncbi.nlm.nih.gov/pubmed/31755428.

416. Rodrigues M, Ait Rais K, Salviat F, et al. Association of partial chromosome 3 deletion in uveal melanomas with metastasis-free survival. JAMA Ophthalmol 2020;138:182–188. Available at: https://www.ncbi.nlm.nih.gov/pubmed/31895446.

417. Vaarwater J, van den Bosch T, Mensink HW, et al. Multiplex ligation-dependent probe amplification equals fluorescence in-situ hybridization for the identification of patients at risk for metastatic disease in uveal melanoma. Melanoma Res 2012;22:30–37. Available at: https://www.ncbi.nlm.nih.gov/pubmed/22157614.

418. Ewens KG, Kanetsky PA, Richards-Yutz J, et al. Genomic profile of 320 uveal melanoma cases: chromosome 8p-loss and metastatic outcome. Invest Ophthalmol Vis Sci 2013;54:5721–5729. Available at: https://www.ncbi.nlm.nih.gov/pubmed/23821189.

419. Vaquero-Garcia J, Lalonde E, Ewens KG, et al. PRiMeUM: A model for predicting risk of metastasis in uveal melanoma. Invest Ophthalmol Vis Sci 2017;58:4096–4105. Available at: https://www.ncbi.nlm.nih.gov/pubmed/28828481.

420. Koopmans AE, Verdijk RM, Brouwer RW, et al. Clinical significance of immunohistochemistry for detection of BAP1 mutations in uveal melanoma. Mod Pathol 2014;27:1321–1330. Available at: https://www.ncbi.nlm.nih.gov/pubmed/24633195.

421. Jha J, Singh MK, Singh L, et al. Expression of BAP1 and ATM proteins: Association with AJCC tumor category in uveal melanoma. Ann Diagn Pathol 2020;44:151432. Available at: https://www.ncbi.nlm.nih.gov/pubmed/31864162.

422. Ewens KG, Lalonde E, Richards-Yutz J, et al. Comparison of germline versus somatic BAP1 mutations for risk of metastasis in uveal melanoma. BMC Cancer 2018;18:1172. Available at: https://www.ncbi.nlm.nih.gov/pubmed/30477459.

Discussion update in progress

Version 1.2026 © 2026 National Comprehensive Cancer Network© (NCCN©), All rights reserved. NCCN Guidelines® and this illustration may not be reproduced in any form without the express written permission of NCCN.

PLEASE NOTE that use of this NCCN Content is governed by the End-User License Agreement, and you MAY NOT distribute this Content or use it with any artificial intelligence model or tool.
Printed by Galya Basol Kochav on 2/13/2026 11:27:31 AM. Copyright © 2026 National Comprehensive Cancer Network, Inc. All Rights Reserved.

423. Szalai E, Jiang Y, van Poppelen NM, et al. Association of uveal melanoma metastatic rate with stochastic mutation rate and type of mutation. JAMA Ophthalmol 2018;136:1115–1120. Available at: https://www.ncbi.nlm.nih.gov/pubmed/30073324.

424. Yavuzyigitoglu S, Koopmans AE, Verdijk RM, et al. Uveal melanomas with SF3B1 mutations: A distinct subclass associated with late-onset metastases. Ophthalmology 2016;123:1118–1128. Available at: https://www.ncbi.nlm.nih.gov/pubmed/26923342.

425. Yavuzyigitoglu S, Mensink HW, Smit KN, et al. Metastatic disease in polyploid uveal melanoma patients is associated with BAP1 mutations. Invest Ophthalmol Vis Sci 2016;57:2232–2239. Available at: https://www.ncbi.nlm.nih.gov/pubmed/27116551.

426. Robertson AG, Shih J, Yau C, et al. Integrative analysis identifies four molecular and clinical subsets in uveal melanoma. Cancer Cell 2017;32:204–220 e215. Available at: https://www.ncbi.nlm.nih.gov/pubmed/28810145.

427. Drabarek W, Yavuzyigitoglu S, Obulkasim A, et al. Multi-modality analysis improves survival prediction in enucleated uveal melanoma patients. Invest Ophthalmol Vis Sci 2019;60:3595–3605. Available at: https://www.ncbi.nlm.nih.gov/pubmed/31425584.

428. Schefler AC, Koca E, Bernicker EH, Correa ZM. Relationship between clinical features, GEP class, and PRAME expression in uveal melanoma. Graefes Arch Clin Exp Ophthalmol 2019;257:1541–1545. Available at: https://www.ncbi.nlm.nih.gov/pubmed/31065847.

429. Gragoudas ES, Egan KM, Seddon JM, et al. Survival of patients with metastases from uveal melanoma. Ophthalmology 1991;98:383–389; discussion 390. Available at: https://www.ncbi.nlm.nih.gov/pubmed/2023760.

430. Kodjikian L, Grange JD, Baldo S, et al. Prognostic factors of liver metastases from uveal melanoma. Graefes Arch Clin Exp Ophthalmol 2005;243:985–993. Available at: https://www.ncbi.nlm.nih.gov/pubmed/15891893.

431. Rivoire M, Kodjikian L, Baldo S, et al. Treatment of liver metastases from uveal melanoma. Ann Surg Oncol 2005;12:422–428. Available at: https://www.ncbi.nlm.nih.gov/pubmed/15886904.

432. Kim IK, Lane AM, Gragoudas ES. Survival in patients with presymptomatic diagnosis of metastatic uveal melanoma. Arch Ophthalmol 2010;128:871–875. Available at: https://www.ncbi.nlm.nih.gov/pubmed/20625048.

433. Eskelin S, Pyrhonen S, Summanen P, et al. Screening for metastatic malignant melanoma of the uvea revisited. Cancer 1999;85:1151–1159. Available at: https://www.ncbi.nlm.nih.gov/pubmed/10091801.

434. Kaiserman I, Amer R, Pe'er J. Liver function tests in metastatic uveal melanoma. Am J Ophthalmol 2004;137:236–243. Available at: https://www.ncbi.nlm.nih.gov/pubmed/14962411.

435. Hendler K, Pe'er J, Kaiserman I, et al. Trends in liver function tests: a comparison with serum tumor markers in metastatic uveal melanoma (part 2). Anticancer Res 2011;31:351–357. Available at: https://www.ncbi.nlm.nih.gov/pubmed/21273623.

436. Kurli M, Reddy S, Tena LB, et al. Whole body positron emission tomography/computed tomography staging of metastatic choroidal melanoma. Am J Ophthalmol 2005;140:193–199. Available at: https://www.ncbi.nlm.nih.gov/pubmed/15992753.

437. Mouriaux F, Diorio C, Bergeron D, et al. Liver function testing is not helpful for early diagnosis of metastatic uveal melanoma. Ophthalmology 2012;119:1590–1595. Available at: https://www.ncbi.nlm.nih.gov/pubmed/22683062.

438. Piperno-Neumann S, Servois V, Mariani P, et al. Prospective study of surveillance testing for metastasis in 100 high-risk uveal melanoma patients. J Fr Ophtalmol 2015;38:526–534. Available at: https://www.ncbi.nlm.nih.gov/pubmed/25978872.

Discussion update in progress

Version 1.2026 © 2026 National Comprehensive Cancer Network© (NCCN©), All rights reserved. NCCN Guidelines® and this illustration may not be reproduced in any form without the express written permission of NCCN.

PLEASE NOTE that use of this NCCN Content is governed by the End-User License Agreement, and you MAY NOT distribute this Content or use it with any artificial intelligence model or tool.
Printed by Galya Basol Kochav on 2/13/2026 11:27:31 AM. Copyright © 2026 National Comprehensive Cancer Network, Inc. All Rights Reserved.

439. Wagner M, Mariani P, Bidard FC, et al. Diffusion-weighted MRI for uveal melanoma liver metastasis detection. Eur Radiol 2015;25:2263–2273. Available at: https://www.ncbi.nlm.nih.gov/pubmed/25712144.

440. Choudhary MM, Gupta A, Bena J, et al. Hepatic ultrasonography for surveillance in patients with uveal melanoma. JAMA Ophthalmol 2016;134:174–180. Available at: https://www.ncbi.nlm.nih.gov/pubmed/26633182.

441. Cohen VML, Pavlidou E, DaCosta J, et al. Staging uveal melanoma with whole-body positron-emission tomography/computed tomography and abdominal ultrasound: Low incidence of metastatic disease, high incidence of second primary cancers. Middle East Afr J Ophthalmol 2018;25:91–95. Available at: https://www.ncbi.nlm.nih.gov/pubmed/30122854.

442. Rantala ES, Peltola E, Helminen H, et al. Hepatic ultrasonography compared with computed tomography and magnetic resonance imaging at diagnosis of metastatic uveal melanoma. Am J Ophthalmol 2020;216:156–164. Available at: https://www.ncbi.nlm.nih.gov/pubmed/32278769.

443. Wen JC, Sai V, Straatsma BR, McCannel TA. Radiation-related cancer risk associated with surveillance imaging for metastasis from choroidal melanoma. JAMA Ophthalmol 2013;131:56–61. Available at: https://www.ncbi.nlm.nih.gov/pubmed/23307209.

444. Semelka RC, Martin DR, Balci C, Lance T. Focal liver lesions: comparison of dual-phase CT and multisequence multiplanar MR imaging including dynamic gadolinium enhancement. J Magn Reson Imaging 2001;13:397–401. Available at: https://www.ncbi.nlm.nih.gov/pubmed/11241813.

445. Servois V, Mariani P, Malhaire C, et al. Preoperative staging of liver metastases from uveal melanoma by magnetic resonance imaging (MRI) and fluorodeoxyglucose-positron emission tomography (FDG-PET). Eur J Surg Oncol 2010;36:189–194. Available at: https://www.ncbi.nlm.nih.gov/pubmed/19775851.

446. Orcurto V, Denys A, Voelter V, et al. (18)F-fluorodeoxyglucose positron emission tomography/computed tomography and magnetic resonance imaging in patients with liver metastases from uveal melanoma: results from a pilot study. Melanoma Res 2012;22:63–69. Available at: https://www.ncbi.nlm.nih.gov/pubmed/22027909.

447. Marshall E, Romaniuk C, Ghaneh P, et al. MRI in the detection of hepatic metastases from high-risk uveal melanoma: a prospective study in 188 patients. Br J Ophthalmol 2013;97:159–163. Available at: https://www.ncbi.nlm.nih.gov/pubmed/23159448.

448. Diener-West M, Reynolds SM, Agugliaro DJ, et al. Second primary cancers after enrollment in the COMS trials for treatment of choroidal melanoma: COMS Report No. 25. Arch Ophthalmol 2005;123:601–604. Available at: https://www.ncbi.nlm.nih.gov/pubmed/15883277.

449. Caminal JM, Martinez J, Arias LL, et al. [Multiple neoplasms in patients with uveal melanoma]. Arch Soc Esp Oftalmol 2007;82:535–540. Available at: https://www.ncbi.nlm.nih.gov/pubmed/17846942.

450. Shields CL, Shields JA, Perez N, et al. Primary transpupillary thermotherapy for small choroidal melanoma in 256 consecutive cases: outcomes and limitations. Ophthalmology 2002;109:225–234. Available at: https://www.ncbi.nlm.nih.gov/pubmed/11825800.

451. Riechardt AI, Cordini D, Dobner B, et al. Salvage proton beam therapy in local recurrent uveal melanoma. Am J Ophthalmol 2014;158:948–956. Available at: https://www.ncbi.nlm.nih.gov/pubmed/25038327.

452. Seibel I, Cordini D, Rehak M, et al. Local recurrence after primary proton beam therapy in uveal melanoma: Risk factors, retreatment approaches, and outcome. Am J Ophthalmol 2015;160:628–636. Available at: https://www.ncbi.nlm.nih.gov/pubmed/26133249.

453. King B, Morales-Tirado VM, Wynn HG, et al. Repeat episcleral plaque brachytherapy: Clinical outcomes in patients treated for locally recurrent posterior uveal melanoma. Am J Ophthalmol 2017;176:40–45. Available at: https://www.ncbi.nlm.nih.gov/pubmed/28048976.

Discussion update in progress

Version 1.2026 © 2026 National Comprehensive Cancer Network© (NCCN©), All rights reserved. NCCN Guidelines® and this illustration may not be reproduced in any form without the express written permission of NCCN.

PLEASE NOTE that use of this NCCN Content is governed by the End-User License Agreement, and you MAY NOT distribute this Content or use it with any artificial intelligence model or tool.
Printed by Galya Basol Kochav on 2/13/2026 11:27:31 AM. Copyright © 2026 National Comprehensive Cancer Network, Inc. All Rights Reserved.

454. Marucci L, Lane AM, Li W, et al. Conservation treatment of the eye: Conformal proton reirradiation for recurrent uveal melanoma. Int J Radiat Oncol Biol Phys 2006;64:1018–1022. Available at: https://www.ncbi.nlm.nih.gov/pubmed/16376492.

455. Gragoudas ES, Egan KM, Seddon JM, et al. Intraocular recurrence of uveal melanoma after proton beam irradiation. Ophthalmology 1992;99:760–766. Available at: https://www.ncbi.nlm.nih.gov/pubmed/1594223.

456. Marucci L, Ancukiewicz M, Lane AM, et al. Uveal melanoma recurrence after fractionated proton beam therapy: comparison of survival in patients treated with reirradiation or with enucleation. Int J Radiat Oncol Biol Phys 2011;79:842–846. Available at: https://www.ncbi.nlm.nih.gov/pubmed/20472356.

457. Rantala ES, Hernberg M, Kivela TT. Overall survival after treatment for metastatic uveal melanoma: a systematic review and meta-analysis. Melanoma Res 2019;29:561–568. Available at: https://www.ncbi.nlm.nih.gov/pubmed/30664106.

458. Rowcroft A, Loveday BPT, Thomson BNJ, et al. Systematic review of liver directed therapy for uveal melanoma hepatic metastases. HPB (Oxford) 2020;22:497–505. Available at: https://www.ncbi.nlm.nih.gov/pubmed/31791894.

459. Valpione S, Moser JC, Parrozzani R, et al. Development and external validation of a prognostic nomogram for metastatic uveal melanoma. PLoS One 2015;10:e0120181. Available at: https://www.ncbi.nlm.nih.gov/pubmed/25780931.

460. Stalhammar G, Herrspiegel C. Long-term relative survival in uveal melanoma: a systematic review and meta-analysis. Commun Med (Lond) 2022;2:18. Available at: https://www.ncbi.nlm.nih.gov/pubmed/35603296.

461. Nicholas MN, Khoja L, Atenafu EG, et al. Prognostic factors for first-line therapy and overall survival of metastatic uveal melanoma: The Princess Margaret Cancer Centre experience. Melanoma Res 2018;28:571–577. Available at: https://www.ncbi.nlm.nih.gov/pubmed/30067547.

462. Lorenzo D, Piulats JM, Ochoa M, et al. Clinical predictors of survival in metastatic uveal melanoma. Jpn J Ophthalmol 2019;63:197–209. Available at: https://www.ncbi.nlm.nih.gov/pubmed/30796549.

463. Frenkel S, Nir I, Hendler K, et al. Long-term survival of uveal melanoma patients after surgery for liver metastases. Br J Ophthalmol 2009;93:1042–1046. Available at: https://www.ncbi.nlm.nih.gov/pubmed/19429579.

464. Patel M, Winston CB, Marr BP, et al. Characterization of computed tomography scan abnormalities in patients with biopsy-proven hepatic metastases from uveal melanoma. Arch Ophthalmol 2011;129:1576–1582. Available at: https://www.ncbi.nlm.nih.gov/pubmed/22159677.

465. Mariani P, Dureau S, Savignoni A, et al. Development of a prognostic nomogram for liver metastasis of uveal melanoma patients selected by liver MRI. Cancers (Basel) 2019;11. Available at: https://www.ncbi.nlm.nih.gov/pubmed/31234340.

466. Jochems A, van der Kooij MK, Fiocco M, et al. Metastatic uveal melanoma: Treatment strategies and survival-results from the Dutch melanoma treatment registry. Cancers (Basel) 2019;11. Available at: https://www.ncbi.nlm.nih.gov/pubmed/31323802.

467. Hsueh EC, Essner R, Foshag LJ, et al. Prolonged survival after complete resection of metastases from intraocular melanoma. Cancer 2004;100:122–129. Available at: https://www.ncbi.nlm.nih.gov/pubmed/14692032.

468. Augsburger JJ, Correa ZM, Shaikh AH. Effectiveness of treatments for metastatic uveal melanoma. Am J Ophthalmol 2009;148:119–127. Available at: https://www.ncbi.nlm.nih.gov/pubmed/19375060.

469. Agarwala SS, Eggermont AM, O'Day S, Zager JS. Metastatic melanoma to the liver: a contemporary and comprehensive review of surgical, systemic, and regional therapeutic options. Cancer

Discussion update in progress

Version 1.2026 © 2026 National Comprehensive Cancer Network© (NCCN©), All rights reserved. NCCN Guidelines® and this illustration may not be reproduced in any form without the express written permission of NCCN.

PLEASE NOTE that use of this NCCN Content is governed by the End-User License Agreement, and you MAY NOT distribute this Content or use it with any artificial intelligence model or tool.
Printed by Galya Basol Kochav on 2/13/2026 11:27:31 AM. Copyright © 2026 National Comprehensive Cancer Network, Inc. All Rights Reserved.

2014;120:781–789. Available at: https://www.ncbi.nlm.nih.gov/pubmed/24301420.

470. Rantala ES, Kivela TT, Hernberg MM. Impact of staging on survival outcomes: a nationwide real-world cohort study of metastatic uveal melanoma. Melanoma Res 2021;31:224–231. Available at: https://www.ncbi.nlm.nih.gov/pubmed/33595243.

471. Breedis C, Young G. The blood supply of neoplasms in the liver. Am J Pathol 1954;30:969–977. Available at: https://www.ncbi.nlm.nih.gov/pubmed/13197542.

472. Reddy SK, Kesmodel SB, Alexander HR, Jr. Isolated hepatic perfusion for patients with liver metastases. Ther Adv Med Oncol 2014;6:180–194. Available at: https://www.ncbi.nlm.nih.gov/pubmed/25057304.

473. Broman KK, Zager JS. Intra-arterial perfusion-based therapies for regionally metastatic cutaneous and uveal melanoma. Melanoma Manag 2019;6:MMT26. Available at: https://www.ncbi.nlm.nih.gov/pubmed/31807277.

474. Eschelman DJ, Gonsalves CF, Sato T. Transhepatic therapies for metastatic uveal melanoma. Semin Intervent Radiol 2013;30:39–48. Available at: https://www.ncbi.nlm.nih.gov/pubmed/24436516.

475. Hughes MS, Zager J, Faries M, et al. Results of a randomized controlled multicenter phase III trial of percutaneous hepatic perfusion compared with best available care for patients with melanoma liver metastases. Ann Surg Oncol 2016;23:1309–1319. Available at: https://www.ncbi.nlm.nih.gov/pubmed/26597368.

476. Olofsson Bagge R, Nelson A, Shafazand A, et al. Isolated hepatic perfusion with melphalan for patients with isolated uveal melanoma liver metastases: A multicenter, randomized, open-label, phase III trial (the SCANDIUM Trial). J Clin Oncol 2023;41:3042–3050. Available at: https://www.ncbi.nlm.nih.gov/pubmed/36940407.

477. Vogl TJ, Koch SA, Lotz G, et al. Percutaneous isolated hepatic perfusion as a treatment for isolated hepatic metastases of uveal melanoma: Patient outcome and safety in a multi-centre study. Cardiovasc Intervent Radiol 2017;40:864–872. Available at: https://www.ncbi.nlm.nih.gov/pubmed/28144756.

478. Karydis I, Gangi A, Wheater MJ, et al. Percutaneous hepatic perfusion with melphalan in uveal melanoma: A safe and effective treatment modality in an orphan disease. J Surg Oncol 2018;117:1170–1178. Available at: https://www.ncbi.nlm.nih.gov/pubmed/29284076.

479. Artzner C, Mossakowski O, Hefferman G, et al. Chemosaturation with percutaneous hepatic perfusion of melphalan for liver-dominant metastatic uveal melanoma: a single center experience. Cancer Imaging 2019;19:31. Available at: https://www.ncbi.nlm.nih.gov/pubmed/31146793.

480. Dewald CLA, Warnke MM, Bruning R, et al. Percutaneous hepatic perfusion (PHP) with melphalan in liver-dominant metastatic uveal melanoma: The german experience. Cancers (Basel) 2021;14. Available at: https://www.ncbi.nlm.nih.gov/pubmed/35008282.

481. Meijer TS, Burgmans MC, Fiocco M, et al. Safety of percutaneous hepatic perfusion with melphalan in patients with unresectable liver metastases from ocular melanoma using the delcath systems' second-generation hemofiltration system: A prospective non-randomized phase II trial. Cardiovasc Intervent Radiol 2019;42:841–852. Available at: https://www.ncbi.nlm.nih.gov/pubmed/30767147.

482. Bethlehem MS, Katsarelias D, Olofsson Bagge R. Meta-analysis of isolated hepatic perfusion and percutaneous hepatic perfusion as a treatment for uveal melanoma liver metastases. Cancers (Basel) 2021;13. Available at: https://www.ncbi.nlm.nih.gov/pubmed/34572953.

483. Edelhauser G, Schicher N, Berzaczy D, et al. Fotemustine chemoembolization of hepatic metastases from uveal melanoma: a retrospective single-center analysis. AJR Am J Roentgenol 2012;199:1387–1392. Available at: https://www.ncbi.nlm.nih.gov/pubmed/23169735.

Discussion update in progress

Version 1.2026 © 2026 National Comprehensive Cancer Network© (NCCN©), All rights reserved. NCCN Guidelines® and this illustration may not be reproduced in any form without the express written permission of NCCN.

PLEASE NOTE that use of this NCCN Content is governed by the End-User License Agreement, and you MAY NOT distribute this Content or use it with any artificial intelligence model or tool.
Printed by Galya Basol Kochav on 2/13/2026 11:27:31 AM. Copyright © 2026 National Comprehensive Cancer Network, Inc. All Rights Reserved.

484. Shibayama Y, Namikawa K, Sone M, et al. Efficacy and toxicity of transarterial chemoembolization therapy using cisplatin and gelatin sponge in patients with liver metastases from uveal melanoma in an Asian population. Int J Clin Oncol 2017;22:577–584. Available at: https://www.ncbi.nlm.nih.gov/pubmed/28144882.

485. Fiorentini G, Aliberti C, Del Conte A, et al. Intra-arterial hepatic chemoembolization (TACE) of liver metastases from ocular melanoma with slow-release irinotecan-eluting beads. Early results of a phase II clinical study. In Vivo 2009;23:131–137. Available at: https://www.ncbi.nlm.nih.gov/pubmed/19368137.

486. Carling U, Dorenberg EJ, Haugvik SP, et al. Transarterial chemoembolization of liver metastases from uveal melanoma using irinotecan-loaded beads: Treatment response and complications. Cardiovasc Intervent Radiol 2015;38:1532–1541. Available at: https://www.ncbi.nlm.nih.gov/pubmed/25832764.

487. Valpione S, Aliberti C, Parrozzani R, et al. A retrospective analysis of 141 patients with liver metastases from uveal melanoma: a two-cohort study comparing transarterial chemoembolization with CPT-11 charged microbeads and historical treatments. Melanoma Res 2015;25:164–168. Available at: https://www.ncbi.nlm.nih.gov/pubmed/25521594.

488. Bedikian AY, Legha SS, Mavligit G, et al. Treatment of uveal melanoma metastatic to the liver: a review of the M. D. Anderson Cancer Center experience and prognostic factors. Cancer 1995;76:1665–1670. Available at: https://www.ncbi.nlm.nih.gov/pubmed/8635073.

489. Patel K, Sullivan K, Berd D, et al. Chemoembolization of the hepatic artery with BCNU for metastatic uveal melanoma: results of a phase II study. Melanoma Res 2005;15:297–304. Available at: https://www.ncbi.nlm.nih.gov/pubmed/16034309.

490. Yamamoto A, Chervoneva I, Sullivan KL, et al. High-dose immunoembolization: survival benefit in patients with hepatic metastases from uveal melanoma. Radiology 2009;252:290–298. Available at: https://www.ncbi.nlm.nih.gov/pubmed/19561263.

491. Gupta S, Bedikian AY, Ahrar J, et al. Hepatic artery chemoembolization in patients with ocular melanoma metastatic to the liver: response, survival, and prognostic factors. Am J Clin Oncol 2010;33:474–480. Available at: https://www.ncbi.nlm.nih.gov/pubmed/19935383.

492. Duran R, Chapiro J, Frangakis C, et al. Uveal melanoma metastatic to the liver: The role of quantitative volumetric contrast-enhanced MR imaging in the assessment of early tumor response after transarterial chemoembolization. Transl Oncol 2014;7:447–455. Available at: https://www.ncbi.nlm.nih.gov/pubmed/24953419.

493. Huppert PE, Fierlbeck G, Pereira P, et al. Transarterial chemoembolization of liver metastases in patients with uveal melanoma. Eur J Radiol 2010;74:e38–44. Available at: https://www.ncbi.nlm.nih.gov/pubmed/19467811.

494. Gonsalves CF, Eschelman DJ, Thornburg B, et al. Uveal melanoma metastatic to the liver: Chemoembolization with 1,3-bis-(2-chloroethyl)-1-nitrosourea. AJR Am J Roentgenol 2015;205:429–433. Available at: https://www.ncbi.nlm.nih.gov/pubmed/25905562.

495. Tulokas S, Maenpaa H, Peltola E, et al. Selective internal radiation therapy (SIRT) as treatment for hepatic metastases of uveal melanoma: a Finnish nation-wide retrospective experience. Acta Oncol 2018;57:1373–1380. Available at: https://www.ncbi.nlm.nih.gov/pubmed/29683787.

496. Jia Z, Jiang G, Zhu C, et al. A systematic review of yttrium-90 radioembolization for unresectable liver metastases of melanoma. Eur J Radiol 2017;92:111–115. Available at: https://www.ncbi.nlm.nih.gov/pubmed/28624008.

497. Ponti A, Denys A, Digklia A, et al. First-line selective internal radiation therapy in patients with uveal melanoma metastatic to the liver. J Nucl Med 2020;61:350–356. Available at: https://www.ncbi.nlm.nih.gov/pubmed/31481579.

498. Gonsalves CF, Eschelman DJ, Adamo RD, et al. A prospective phase II trial of radioembolization for treatment of uveal melanoma hepatic

Discussion update in progress

Version 1.2026 © 2026 National Comprehensive Cancer Network© (NCCN©), All rights reserved. NCCN Guidelines® and this illustration may not be reproduced in any form without the express written permission of NCCN.

PLEASE NOTE that use of this NCCN Content is governed by the End-User License Agreement, and you MAY NOT distribute this Content or use it with any artificial intelligence model or tool.
Printed by Galya Basol Kochav on 2/13/2026 11:27:31 AM. Copyright © 2026 National Comprehensive Cancer Network, Inc. All Rights Reserved.

metastasis. Radiology 2019;293:223–231. Available at: https://www.ncbi.nlm.nih.gov/pubmed/31453767.

499. Eldredge-Hindy H, Ohri N, Anne PR, et al. Yttrium-90 microsphere brachytherapy for liver metastases from uveal melanoma: Clinical outcomes and the predictive value of fluorodeoxyglucose positron emission tomography. Am J Clin Oncol 2016;39:189–195. Available at: https://www.ncbi.nlm.nih.gov/pubmed/24441583.

500. Klingenstein A, Haug AR, Zech CJ, Schaller UC. Radioembolization as locoregional therapy of hepatic metastases in uveal melanoma patients. Cardiovasc Intervent Radiol 2013;36:158–165. Available at: https://www.ncbi.nlm.nih.gov/pubmed/22526099.

501. Gonsalves CF, Eschelman DJ, Sullivan KL, et al. Radioembolization as salvage therapy for hepatic metastasis of uveal melanoma: a single-institution experience. AJR Am J Roentgenol 2011;196:468–473. Available at: https://www.ncbi.nlm.nih.gov/pubmed/21257902.

502. Kennedy AS, Nutting C, Jakobs T, et al. A first report of radioembolization for hepatic metastases from ocular melanoma. Cancer Invest 2009;27:682–690. Available at: https://www.ncbi.nlm.nih.gov/pubmed/19219675.

503. Sato T, Eschelman DJ, Gonsalves CF, et al. Immunoembolization of malignant liver tumors, including uveal melanoma, using granulocyte-macrophage colony-stimulating factor. J Clin Oncol 2008;26:5436–5442. Available at: https://www.ncbi.nlm.nih.gov/pubmed/18838710.

504. Valsecchi ME, Terai M, Eschelman DJ, et al. Double-blinded, randomized phase II study using embolization with or without granulocyte-macrophage colony-stimulating factor in uveal melanoma with hepatic metastases. J Vasc Interv Radiol 2015;26:523–532 e522. Available at: https://www.ncbi.nlm.nih.gov/pubmed/25678394.

505. Eichler K, Zangos S, Gruber-Rouh T, et al. MR-guided laser-induced thermotherapy (LITT) in patients with liver metastases of uveal melanoma. J Eur Acad Dermatol Venereol 2014;28:1756–1760. Available at: https://www.ncbi.nlm.nih.gov/pubmed/24593299.

506. Bale R, Schullian P, Schmuth M, et al. Stereotactic radiofrequency ablation for metastatic melanoma to the liver. Cardiovasc Intervent Radiol 2016;39:1128–1135. Available at: https://www.ncbi.nlm.nih.gov/pubmed/27055850.

507. White ML, Atwell TD, Kurup AN, et al. Recurrence and survival outcomes after percutaneous thermal ablation of oligometastatic melanoma. Mayo Clin Proc 2016;91:288–296. Available at: https://www.ncbi.nlm.nih.gov/pubmed/26827235.

508. Rozeman EA, Prevoo W, Meier MAJ, et al. Phase Ib/II trial testing combined radiofrequency ablation and ipilimumab in uveal melanoma (SECIRA-UM). Melanoma Res 2020;30:252–260. Available at: https://www.ncbi.nlm.nih.gov/pubmed/31895753.

509. Mariani P, Almubarak MM, Kollen M, et al. Radiofrequency ablation and surgical resection of liver metastases from uveal melanoma. Eur J Surg Oncol 2016;42:706–712. Available at: https://www.ncbi.nlm.nih.gov/pubmed/26968227.

510. Servois V, Bouhadiba T, Dureau S, et al. Iterative treatment with surgery and radiofrequency ablation of uveal melanoma liver metastasis: Retrospective analysis of a series of very long-term survivors. Eur J Surg Oncol 2019;45:1717–1722. Available at: https://www.ncbi.nlm.nih.gov/pubmed/31266665.

511. Bala MM, Riemsma RP, Wolff R, et al. Cryotherapy for liver metastases. Cochrane Database Syst Rev 2019;7:CD009058. Available at: https://www.ncbi.nlm.nih.gov/pubmed/31291464.

512. Putzer D, Schullian P, Bale R. Locoregional ablative treatment of melanoma metastases. Int J Hyperthermia 2019;36:59–63. Available at: https://www.ncbi.nlm.nih.gov/pubmed/31537161.

513. Holzwanger DJ, Madoff DC. Role of interventional radiology in the management of hepatocellular carcinoma: current status. Chin Clin Oncol 2018;7:49. Available at: https://www.ncbi.nlm.nih.gov/pubmed/30180753.

Discussion update in progress

Version 1.2026 © 2026 National Comprehensive Cancer Network© (NCCN©), All rights reserved. NCCN Guidelines® and this illustration may not be reproduced in any form without the express written permission of NCCN.

PLEASE NOTE that use of this NCCN Content is governed by the End-User License Agreement, and you MAY NOT distribute this Content or use it with any artificial intelligence model or tool.
Printed by Galya Basol Kochav on 2/13/2026 11:27:31 AM. Copyright © 2026 National Comprehensive Cancer Network, Inc. All Rights Reserved.

514. Glassberg MB, Ghosh S, Clymer JW, et al. Microwave ablation compared with radiofrequency ablation for treatment of hepatocellular carcinoma and liver metastases: a systematic review and meta-analysis. Onco Targets Ther 2019;12:6407–6438. Available at: https://www.ncbi.nlm.nih.gov/pubmed/31496742.

515. Vietti Violi N, Duran R, Guiu B, et al. Efficacy of microwave ablation versus radiofrequency ablation for the treatment of hepatocellular carcinoma in patients with chronic liver disease: a randomised controlled phase 2 trial. Lancet Gastroenterol Hepatol 2018;3:317–325. Available at: https://www.ncbi.nlm.nih.gov/pubmed/29503247.

516. Mahnken AH, Konig AM, Figiel JH. Current technique and application of percutaneous cryotherapy. Rofo 2018;190:836–846. Available at: https://www.ncbi.nlm.nih.gov/pubmed/29665588.

517. Wu S, Hou J, Ding Y, et al. Cryoablation versus radiofrequency ablation for hepatic malignancies: A systematic review and literature-based analysis. Medicine (Baltimore) 2015;94:e2252. Available at: https://www.ncbi.nlm.nih.gov/pubmed/26656371.

518. Buder K, Gesierich A, Gelbrich G, Goebeler M. Systemic treatment of metastatic uveal melanoma: review of literature and future perspectives. Cancer Med 2013;2:674–686. Available at: https://www.ncbi.nlm.nih.gov/pubmed/24403233.

519. McWilliams RR, Allred JB, Slostad JA, et al. NCCTG N0879 (Alliance): A randomized phase 2 cooperative group trial of carboplatin, paclitaxel, and bevacizumab +/- everolimus for metastatic melanoma. Cancer 2018;124:537–545. Available at: https://www.ncbi.nlm.nih.gov/pubmed/29044496.

520. Carvajal RD, Piperno-Neumann S, Kapiteijn E, et al. Selumetinib in combination with dacarbazine in patients with metastatic uveal melanoma: A phase iii, multicenter, randomized trial (SUMIT). J Clin Oncol 2018;36:1232–1239. Available at: https://www.ncbi.nlm.nih.gov/pubmed/29528792.

521. Sacco JJ, Nathan PD, Danson S, et al. Sunitinib versus dacarbazine as first-line treatment in patients with metastatic uveal melanoma. Journal of Clinical Oncology 2013;31:9031–9031. Available at: https://ascopubs.org/doi/abs/10.1200/jco.2013.31.15_suppl.9031.

522. Luke JJ, Olson DJ, Allred JB, et al. Randomized phase II trial and tumor mutational spectrum analysis from cabozantinib versus chemotherapy in metastatic uveal melanoma (Alliance A091201). Clin Cancer Res 2020;26:804–811. Available at: https://www.ncbi.nlm.nih.gov/pubmed/31558480.

523. Daud A, Kluger HM, Kurzrock R, et al. Phase II randomised discontinuation trial of the MET/VEGF receptor inhibitor cabozantinib in metastatic melanoma. Br J Cancer 2017;116:432–440. Available at: https://www.ncbi.nlm.nih.gov/pubmed/28103611.

524. Nathan P, Hassel JC, Rutkowski P, et al. Overall survival benefit with tebentafusp in metastatic uveal melanoma. N Engl J Med 2021;385:1196–1206. Available at: https://www.ncbi.nlm.nih.gov/pubmed/34551229.

525. Zimmer L, Vaubel J, Mohr P, et al. Phase II DeCOG-study of ipilimumab in pretreated and treatment-naive patients with metastatic uveal melanoma. PLoS One 2015;10:e0118564. Available at: https://www.ncbi.nlm.nih.gov/pubmed/25761109.

526. Piulats Rodriguez JM, Ochoa de Olza M, Codes M, et al. Phase II study evaluating ipilimumab as a single agent in the first-line treatment of adult patients (Pts) with metastatic uveal melanoma (MUM): The GEM-1 trial. Journal of Clinical Oncology 2014;32:9033–9033. Available at: https://ascopubs.org/doi/abs/10.1200/jco.2014.32.15_suppl.9033.

527. van der Kooij MK, Joosse A, Speetjens FM, et al. Anti-PD1 treatment in metastatic uveal melanoma in the Netherlands. Acta Oncol 2017;56:101–103. Available at: https://www.ncbi.nlm.nih.gov/pubmed/27911126.

528. Johnson DB, Bao R, Ancell KK, et al. Response to anti-PD-1 in uveal melanoma without high-volume liver metastasis. J Natl Compr Canc Netw

Discussion update in progress

Version 1.2026 © 2026 National Comprehensive Cancer Network© (NCCN©), All rights reserved. NCCN Guidelines® and this illustration may not be reproduced in any form without the express written permission of NCCN.

PLEASE NOTE that use of this NCCN Content is governed by the End-User License Agreement, and you MAY NOT distribute this Content or use it with any artificial intelligence model or tool.
Printed by Galya Basol Kochav on 2/13/2026 11:27:31 AM. Copyright © 2026 National Comprehensive Cancer Network, Inc. All Rights Reserved.

2019;17:114–117. Available at: https://www.ncbi.nlm.nih.gov/pubmed/30787124.

529. Rossi E, Pagliara MM, Orteschi D, et al. Pembrolizumab as first-line treatment for metastatic uveal melanoma. Cancer Immunol Immunother 2019;68:1179–1185. Available at: https://www.ncbi.nlm.nih.gov/pubmed/31175402.

530. Schadendorf D, Ascierto PA, Haanen JBAG, et al. Efficacy and safety of nivolumab (NIVO) in patients with advanced melanoma (MEL) and poor prognostic factors who progressed on or after ipilimumab (IPI): Results from a phase II study (CheckMate 172). Journal of Clinical Oncology 2017;35:9524–9524. Available at: https://ascopubs.org/doi/abs/10.1200/JCO.2017.35.15_suppl.9524.

531. Nathan P, Ascierto PA, Haanen J, et al. Safety and efficacy of nivolumab in patients with rare melanoma subtypes who progressed on or after ipilimumab treatment: a single-arm, open-label, phase II study (CheckMate 172). Eur J Cancer 2019;119:168–178. Available at: https://www.ncbi.nlm.nih.gov/pubmed/31445199.

532. Pelster MS, Gruschkus SK, Bassett R, et al. Nivolumab and ipilimumab in metastatic uveal melanoma: Results from a single-arm phase II study. J Clin Oncol 2021;39:599–607. Available at: https://www.ncbi.nlm.nih.gov/pubmed/33125309.

533. Piulats JM, Espinosa E, de la Cruz Merino L, et al. Nivolumab plus ipilimumab for treatment-naive metastatic uveal melanoma: An open-label, multicenter, phase II trial by the spanish multidisciplinary melanoma group (GEM-1402). J Clin Oncol 2021;39:586–598. Available at: https://www.ncbi.nlm.nih.gov/pubmed/33417511.

534. Jung M, Lee J, Kim TM, et al. Ipilimumab real-world efficacy and safety in korean melanoma patients from the korean named-patient program cohort. Cancer Res Treat 2017;49:44–53. Available at: https://www.ncbi.nlm.nih.gov/pubmed/27121719.

535. Hassel JC, Piperno-Neumann S, Rutkowski P, et al. Three-year overall survival with tebentafusp in metastatic uveal melanoma. N Engl J Med 2023;389:2256–2266. Available at: https://www.ncbi.nlm.nih.gov/pubmed/37870955.

536. Carvajal RD, Sosman JA, Quevedo JF, et al. Effect of selumetinib vs chemotherapy on progression-free survival in uveal melanoma: a randomized clinical trial. JAMA 2014;311:2397–2405. Available at: https://www.ncbi.nlm.nih.gov/pubmed/24938562.

537. Bedikian AY, Plager C, Papadopoulos N, et al. Phase II evaluation of paclitaxel by short intravenous infusion in metastatic melanoma. Melanoma Res 2004;14:63–66. Available at: https://www.ncbi.nlm.nih.gov/pubmed/15091196.

538. Homsi J, Bedikian AY, Papadopoulos NE, et al. Phase 2 open-label study of weekly docosahexaenoic acid-paclitaxel in patients with metastatic uveal melanoma. Melanoma Res 2010;20:507–510. Available at: https://www.ncbi.nlm.nih.gov/pubmed/20881508.

539. Leyvraz S, Piperno-Neumann S, Suciu S, et al. Hepatic intra-arterial versus intravenous fotemustine in patients with liver metastases from uveal melanoma (EORTC 18021): a multicentric randomized trial. Ann Oncol 2014;25:742–746. Available at: https://www.ncbi.nlm.nih.gov/pubmed/24510314.

540. Schmidt-Hieber M, Schmittel A, Thiel E, Keilholz U. A phase II study of bendamustine chemotherapy as second-line treatment in metastatic uveal melanoma. Melanoma Res 2004;14:439–442. Available at: https://www.ncbi.nlm.nih.gov/pubmed/15577312.

541. Schmittel A, Schmidt-Hieber M, Martus P, et al. A randomized phase II trial of gemcitabine plus treosulfan versus treosulfan alone in patients with metastatic uveal melanoma. Ann Oncol 2006;17:1826–1829. Available at: https://www.ncbi.nlm.nih.gov/pubmed/16971664.

542. Bedikian AY, Papadopoulos NE, Kim KB, et al. A pilot study with vincristine sulfate liposome infusion in patients with metastatic melanoma. Melanoma Res 2008;18:400–404. Available at: https://www.ncbi.nlm.nih.gov/pubmed/19011511.

Discussion update in progress

Version 1.2026 © 2026 National Comprehensive Cancer Network© (NCCN©), All rights reserved. NCCN Guidelines® and this illustration may not be reproduced in any form without the express written permission of NCCN.

PLEASE NOTE that use of this NCCN Content is governed by the End-User License Agreement, and you MAY NOT distribute this Content or use it with any artificial intelligence model or tool.
Printed by Galya Basol Kochav on 2/13/2026 11:27:31 AM. Copyright © 2026 National Comprehensive Cancer Network, Inc. All Rights Reserved.

543. Kim KB, Bedikian AY, Camacho LH, et al. A phase II trial of arsenic trioxide in patients with metastatic melanoma. Cancer 2005;104:1687–1692. Available at: https://www.ncbi.nlm.nih.gov/pubmed/16130126.

544. Zeldis JB, Heller C, Seidel G, et al. A randomized phase II trial comparing two doses of lenalidomide for the treatment of stage IV ocular melanoma. Journal of Clinical Oncology 2009;27:e20012–e20012. Available at: https://ascopubs.org/doi/abs/10.1200/jco.2009.27.15_suppl.e20012.

545. Bedikian AY, Papadopoulos N, Plager C, et al. Phase II evaluation of temozolomide in metastatic choroidal melanoma. Melanoma Res 2003;13:303–306. Available at: https://www.ncbi.nlm.nih.gov/pubmed/12777987.

546. Flaherty KT, Lee SJ, Zhao F, et al. Phase III trial of carboplatin and paclitaxel with or without sorafenib in metastatic melanoma. J Clin Oncol 2013;31:373–379. Available at: https://www.ncbi.nlm.nih.gov/pubmed/23248256.

547. O'Neill PA, Butt M, Eswar CV, et al. A prospective single arm phase II study of dacarbazine and treosulfan as first-line therapy in metastatic uveal melanoma. Melanoma Res 2006;16:245–248. Available at: https://www.ncbi.nlm.nih.gov/pubmed/16718271.

548. Schmittel A, Scheulen ME, Bechrakis NE, et al. Phase II trial of cisplatin, gemcitabine and treosulfan in patients with metastatic uveal melanoma. Melanoma Res 2005;15:205–207. Available at: https://www.ncbi.nlm.nih.gov/pubmed/15917703.

549. Atzpodien J, Terfloth K, Fluck M, Reitz M. Cisplatin, gemcitabine and treosulfan is effective in chemotherapy-pretreated relapsed stage IV uveal melanoma patients. Cancer Chemother Pharmacol 2008;62:685–688. Available at: https://www.ncbi.nlm.nih.gov/pubmed/18084763.

550. Schinzari G, Rossi E, Cassano A, et al. Cisplatin, dacarbazine and vinblastine as first line chemotherapy for liver metastatic uveal melanoma in the era of immunotherapy: a single institution phase II study. Melanoma Res 2017;27:591–595. Available at: https://www.ncbi.nlm.nih.gov/pubmed/29076951.

551. Lee CK, Jung M, Choi HJ, et al. Results of a phase II study to evaluate the efficacy of docetaxel and carboplatin in metastatic malignant melanoma patients who failed first-line therapy containing dacarbazine. Cancer Res Treat 2015;47:781–789. Available at: https://www.ncbi.nlm.nih.gov/pubmed/25687848.

552. Bedikian AY, Legha SS, Eton O, et al. Phase II trial of tirapazamine combined with cisplatin in chemotherapy of advanced malignant melanoma. Ann Oncol 1997;8:363–367. Available at: https://www.ncbi.nlm.nih.gov/pubmed/9209666.

553. Shoushtari AN, Kudchadkar RR, Panageas K, et al. A randomized phase 2 study of trametinib with or without GSK2141795 in patients with advanced uveal melanoma. Journal of Clinical Oncology 2016;34:9511–9511. Available at: http://ascopubs.org/doi/abs/10.1200/JCO.2016.34.15_suppl.9511.

554. Steeb T, Wessely A, Ruzicka T, et al. How to MEK the best of uveal melanoma: A systematic review on the efficacy and safety of MEK inhibitors in metastatic or unresectable uveal melanoma. Eur J Cancer 2018;103:41–51. Available at: https://www.ncbi.nlm.nih.gov/pubmed/30205280.

555. Shoushtari AN, Ong LT, Schoder H, et al. A phase 2 trial of everolimus and pasireotide long-acting release in patients with metastatic uveal melanoma. Melanoma Res 2016;26:272–277. Available at: https://www.ncbi.nlm.nih.gov/pubmed/26795274.

556. Bhatia S, Moon J, Margolin KA, et al. Phase II trial of sorafenib in combination with carboplatin and paclitaxel in patients with metastatic uveal melanoma: SWOG S0512. PLoS One 2012;7:e48787. Available at: https://www.ncbi.nlm.nih.gov/pubmed/23226204.

557. Kaempgen E, Schmid M, Erdmann M, et al. Predictable clinical responses to sorafenib in stage IV uveal melanoma. Journal of Clinical

Discussion update in progress

Version 1.2026 © 2026 National Comprehensive Cancer Network© (NCCN©), All rights reserved. NCCN Guidelines® and this illustration may not be reproduced in any form without the express written permission of NCCN.

PLEASE NOTE that use of this NCCN Content is governed by the End-User License Agreement, and you MAY NOT distribute this Content or use it with any artificial intelligence model or tool.
Printed by Galya Basol Kochav on 2/13/2026 11:27:31 AM. Copyright © 2026 National Comprehensive Cancer Network, Inc. All Rights Reserved.

Oncology 2012;30:e19032–e19032. Available at: https://ascopubs.org/doi/abs/10.1200/jco.2012.30.15_suppl.e19032.

558. Piperno-Neumann S, Diallo A, Etienne-Grimaldi MC, et al. Phase II trial of bevacizumab in combination with temozolomide as first-line treatment in patients with metastatic uveal melanoma. Oncologist 2016;21:281–282. Available at: https://www.ncbi.nlm.nih.gov/pubmed/26911405.

559. Hofmann UB, Kauczok-Vetter CS, Houben R, Becker JC. Overexpression of the KIT/SCF in uveal melanoma does not translate into clinical efficacy of imatinib mesylate. Clin Cancer Res 2009;15:324–329. Available at: https://www.ncbi.nlm.nih.gov/pubmed/19118061.

560. Dogrusoz M, Jager MJ. Genetic prognostication in uveal melanoma. Acta Ophthalmol 2018;96:331–347. Available at: https://www.ncbi.nlm.nih.gov/pubmed/29105334.

561. Falchook GS, Lewis KD, Infante JR, et al. Activity of the oral MEK inhibitor trametinib in patients with advanced melanoma: a phase 1 dose-escalation trial. Lancet Oncol 2012;13:782–789. Available at: https://www.ncbi.nlm.nih.gov/pubmed/22805292.

Discussion update in progress

Version 1.2026 © 2026 National Comprehensive Cancer Network© (NCCN©), All rights reserved. NCCN Guidelines® and this illustration may not be reproduced in any form without the express written permission of NCCN.